



Thyroid eye disease: An evolving continuum of care

Disclaimer

- *Unapproved products or unapproved uses of approved products may be discussed by the faculty; these situations may reflect the approval status in one or more jurisdictions*
- *The presenting faculty have been advised by USF Health and touchIME to ensure that they disclose any such references made to unlabelled or unapproved use*
- *No endorsement by USF Health or touchIME of any unapproved products or unapproved uses is either made or implied by mention of these products or uses in USF Health and touchIME activities*
- *USF Health and touchIME accept no responsibility for errors or omissions*

Expert panel



Dr Andrea Kossler

Ophthalmologist

Stanford University School of Medicine
Palo Alto, CA, USA



Dr Mario Salvi

Endocrinologist

University of Milan
Milan, Italy



Dr Edsel Ing

Ophthalmologist

University of Alberta
Alberta, Canada
University of Toronto
Ontario, Canada



Agenda

Understanding the mechanisms of TED: Who is at risk?

Clinical presentation of TED: What are the signs and symptoms?

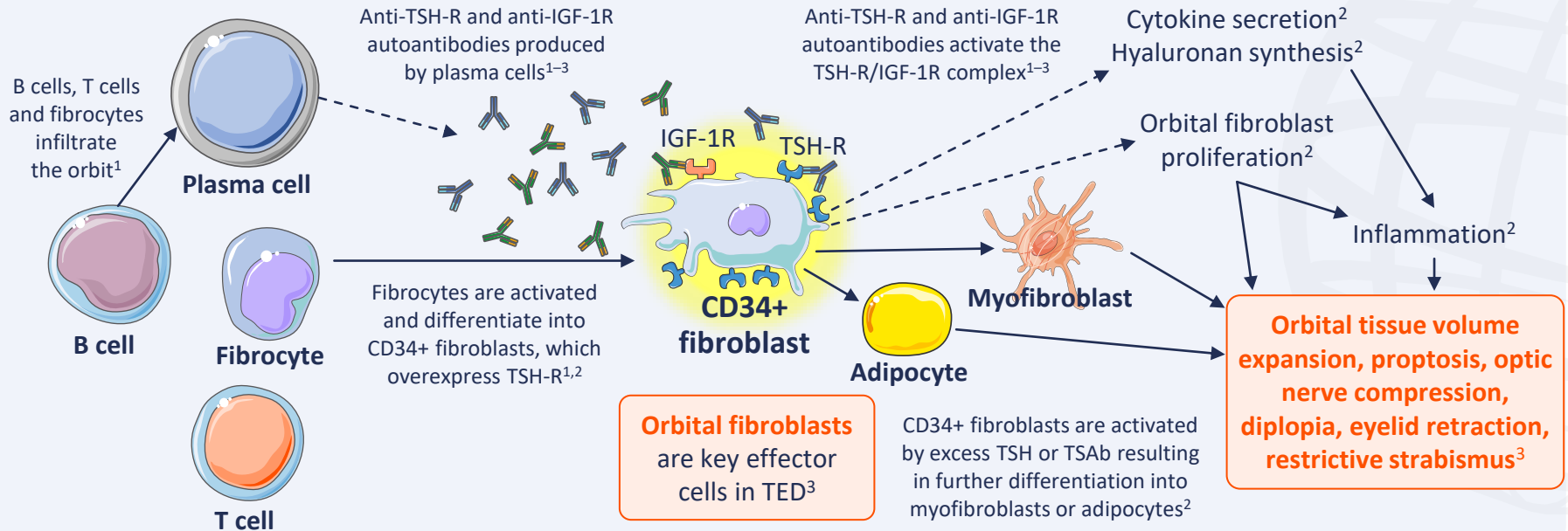
Diagnosing TED: What is involved?



Understanding the mechanisms of TED: Who is at risk?



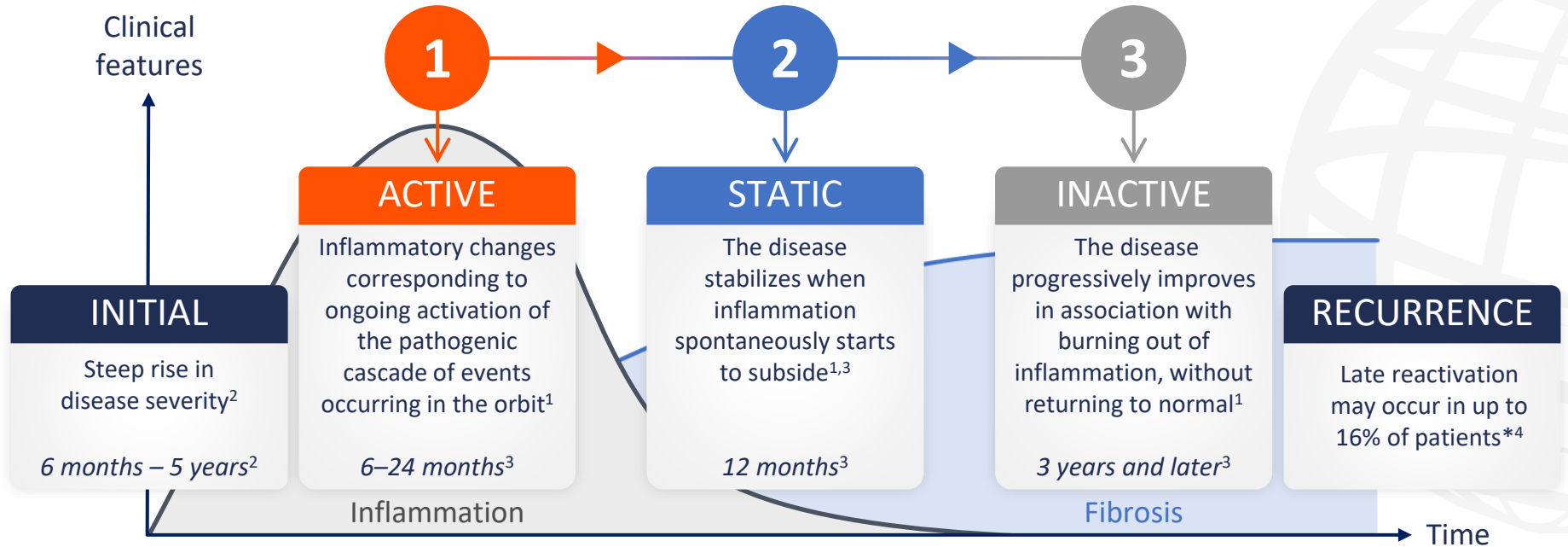
TED is characterized by inflammation and remodelling of the orbital soft tissues and periorbital areas^{1,2}



IGF-1R, insulin-like growth factor 1 receptor; TED, thyroid eye disease; TSAb, thyroid stimulating antibody; TSH, thyroid stimulating hormone; TSH-R, thyroid stimulating hormone receptor.

1. Men CJ, et al. *Ther Adv Ophthalmol*. 2021;13:1–14; 2. Moledina M, et al. *Eye (Lond)*. 2024;38:1425–37; 3. Maurya RP, et al. *Int J Ocular Oculoplast*. 2021;7:117–30.

The natural history of TED involves an active phase, a static phase and an inactive phase¹⁻³



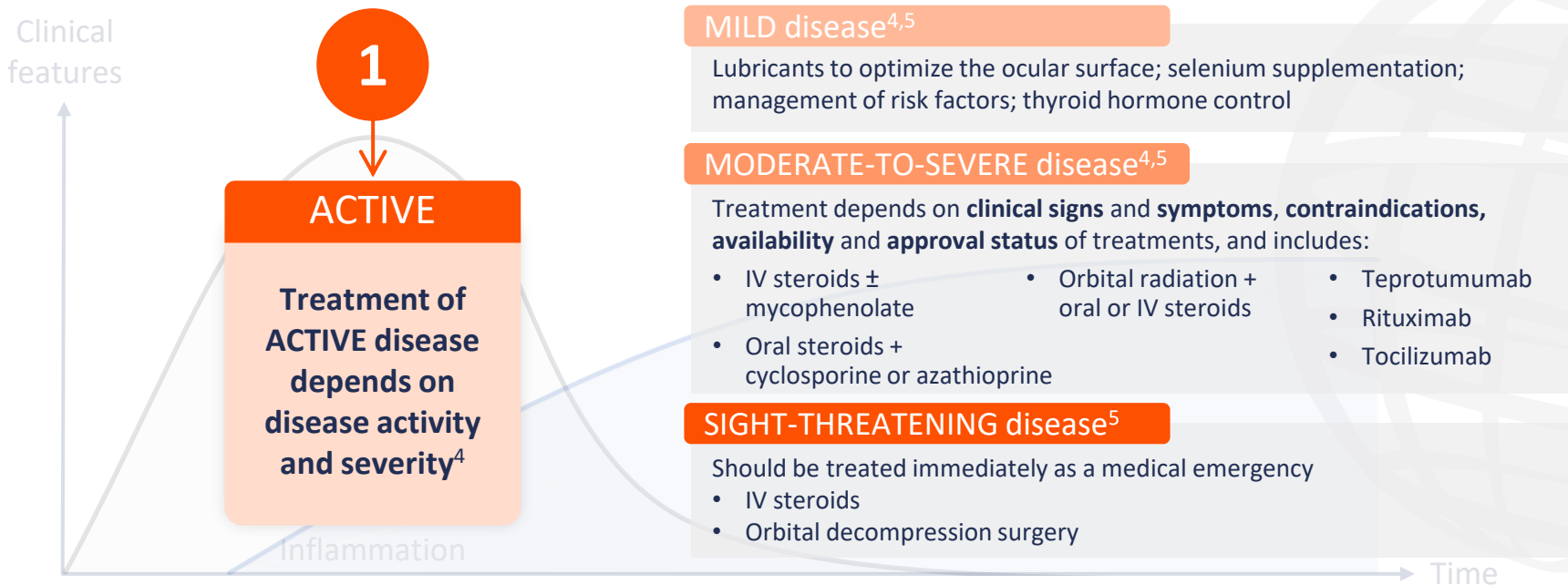
Graph reproduced from Maurya RP, et al. *Int J Ocular Oculoplast.* 2021;7:117–30 (CC BY 4.0 www.creativecommons.org/licenses/by/4.0/).

*Based on a retrospective study, N=415.⁴

TED, thyroid eye disease.

1. Bartalena L, et al. *Front Endocrinol.* 2020;11:615993; 2. Shah SS, Patel BC. Thyroid Eye Disease. Updated 2023. Available at: www.ncbi.nlm.nih.gov/books/NBK582134/ (accessed 17 June 2024); 3. Maurya RP, et al. *Int J Ocular Oculoplast.* 2021;7:117–30; 4. Patel P, et al. *Ophthalmic Plast Reconstr Surg.* 2015;31:445–8.

The natural history of TED involves an active phase, a static phase and an inactive phase^{1–3}



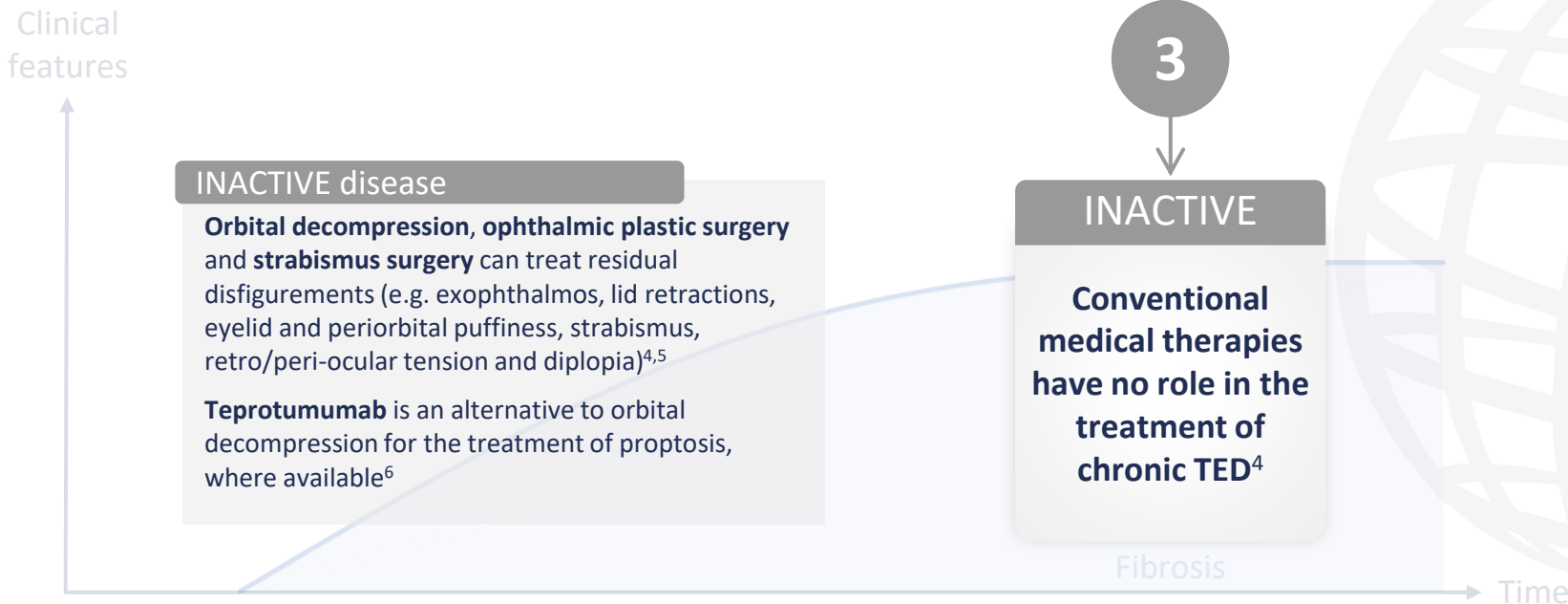
Graph reproduced from Maurya RP, et al. *Int J Ocular Oculoplast.* 2021;7:117–30 (CC BY 4.0 www.creativecommons.org/licenses/by/4.0/).

IV, intravenous; TED, thyroid eye disease.

1. Bartalena L, et al. *Front Endocrinol.* 2020;11:615993; 2. Shah SS, Patel BC. Thyroid Eye Disease. Updated 2023. Available at: www.ncbi.nlm.nih.gov/books/NBK582134/ (accessed 17 June 2024); 3. Maurya RP, et al. *Int J Ocular Oculoplast.* 2021;7:117–30; 4. Men CJ, Kossler AL. *touchREVIEWS Ophthalmol.* 2024;18:33–40;

5. Bartalena L, et al. *Eur J Endocrinol.* 2021;185:G43–67.

The natural history of TED involves an active phase, a static phase and an inactive phase^{1–3}



Graph reproduced from Maurya RP, et al. *Int J Ocular Oculoplast.* 2021;7:117–30 (CC BY 4.0 www.creativecommons.org/licenses/by/4.0/).

TED, thyroid eye disease.

1. Bartalena L, et al. *Front Endocrinol.* 2020;11:615993; 2. Shah SS, Patel BC. Thyroid Eye Disease. Updated 2023. Available at: www.ncbi.nlm.nih.gov/books/NBK582134/ (accessed 17 June 2024); 3. Maurya RP, et al. *Int J Ocular Oculoplast.* 2021;7:117–30; 4. Kossler AL, et al. *J Clin Endocrinol Metab.* 2022;107:S36–46;

5. Bartalena L, et al. *Eur J Endocrinol.* 2021;185:G43–67; 6. Men CJ, Kossler AL. *touchREVIEWS Ophthalmol.* 2024;18:33–40.



**Clinical presentation of TED:
What are the signs and symptoms?**



Ocular discomfort is the most common presentation in patients with TED¹

Eyelid retraction is the most common clinical sign of TED¹

Upper lid retraction presents in over **90%** of cases^{1,2}

Ocular surface*



Dry eye symptoms occur in 65–85% of patients;³ lacrimal gland inflammation; increased tear production; superior limbic keratoconjunctivitis; lagophthalmos; exposure keratopathy; corneal ulceration;† corneal perforation;† endophthalmitis¹

Eyelid



Eyelid retraction; lateral flare; lid lag; lagophthalmos; redness; swelling¹

Orbit



Proptosis; hypertrophy of the orbital fat and EOM; venous stasis and congestion; ocular hypertension¹

EOM



Restrictive strabismus; EOM enlargement; late-onset fibrosis; diplopia¹

Optic nerve



Dysthyroid optic neuropathy (compressive optic neuropathy; optic nerve stretching)¹

*Active TED. †Severe cases. Bold text highlights the key sign/symptom within each category. EOM, extraocular muscles; TED, thyroid eye disease.

1. Shah SS, Patel BC. Thyroid Eye Disease. Updated 2023. Available at: www.ncbi.nlm.nih.gov/books/NBK582134/ (accessed 17 June 2024);

2. Burch HB, et al. *Thyroid*. 2022;32:1439–70; 3. Sun R, et al. *BMC Ophthalmol*. 2023;23:72.



Diagnosing TED: What is involved?



TED diagnosis is typically made clinically, based on presenting ocular signs and symptoms¹



Eyelid retraction present plus any of:²

- Thyroid dysfunction
- Proptosis
- Dysthyroid optic neuropathy
- Extraocular muscle (double vision or restricted eye movements)



Eyelid retraction absent plus thyroid dysfunction plus any of:²

- Proptosis²
- Optic nerve dysfunction²
- Extraocular muscle involvement²
- Classic imaging findings^{2,3}

All other presentations²

- Consider alternative diagnosis

TED, thyroid eye disease.

1. Barrio-Barrio J, et al. *J Ophthalmol.* 2015;2015:249125; 2. Burch HB, et al. *Thyroid.* 2022;32:1439–70; 3. Shah SS, Patel BC. Thyroid Eye Disease. Updated 2023.

Available at: www.ncbi.nlm.nih.gov/books/NBK582134/ (accessed 17 June 2024).

Ophthalmologists can confirm a TED diagnosis and assess severity, activity and disease trajectory

Suggested office-based examination by endocrinologists for assessment of TED



Eyelids

Swelling, redness, retraction, lagophthalmos



Eye movements

Head posture, strabismus, restriction to movement, double vision, retro-orbital pain



Conjunctivae

Redness, chemosis



Cornea

Opacity due to scarring or erosions



Proptosis

Position of cornea in relation to the lateral orbital rim using exophthalmometer, if available



Vision*

VA, colour desaturation, visual field defects, relative afferent pupillary defect, papilledema/optic atrophy

Formal ophthalmic examination by ophthalmologists with expertise in TED



Vision

Central vision; colour vision; peripheral vision

Examination: Snellen chart; colour plates; pupil testing; fundus and optic nerve examination



Inflammation

Redness and swelling of eyelids and conjunctiva

Examination: Slit-lamp biomicroscope



Strabismus

Diplopia; ductions; strabismus

Examination: Corneal light reflex test; cover testing



Appearance

Eyelid retraction; proptosis; corneal exposure

Examination: Marginal reflex distance; exophthalmometry; slit-lamp biomicroscope; fluorescein stain

*Required if history suggests visual loss.
ED, thyroid eye disease; VA, visual acuity.
Burch HB, et al. *Thyroid*. 2022;32:1439–70.