Cataract surgery and ocular comorbidities: Key considerations for intraocular lens choice

Disclaimer

- *Unapproved products or unapproved uses of approved products may be discussed by the faculty; these situations may reflect the approval status in one or more jurisdictions*
- *The presenting faculty have been advised by touchIME and USF Health to ensure that they disclose any such references made to unlabelled or unapproved use*
- *No endorsement by touchIME and USF Health of any unapproved products or unapproved uses is either made or implied by mention of these products or uses in touchIME and USF Health activities*
- *touchIME and USF Health accept no responsibility for errors or omissions*

Considerations for patients with cataracts and glaucoma

Dr Jennifer Loh

Loh Ophthalmology Associates
Miami, FL, USA

touch™ OPHTHALMOLOGY

How does glaucoma affect vision and what are the implications of glaucoma on patients requiring cataract surgery?

Key features of glaucoma

Glaucomatous visual field defects (top) with primary open angle glaucoma and simulation of the patient's vision (bottom)[1,2]

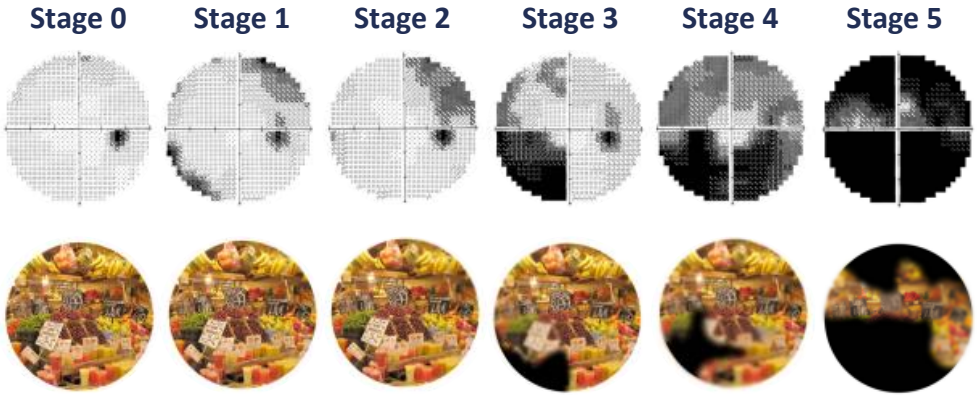

Open-angle glaucoma[3]

- Increase in IOP over time causing damage to the optic nerve
- Usually painless
- No vision changes at first
- Blind spots in peripheral vision develop over time

Closed-angle glaucoma[3]

- Acute attack/eye emergency
- Vision suddenly very blurry
- Severe eye pain
- Headaches
- Nausea and vomiting
- Rainbow coloured halos around lights

Images adapted from Rulli E, et al. *Sci Rep.* 2018;8:619 (CC BY 4.0 www.creativecommons.org/licenses/by/4.0/).
IOP, intraocular pressure.

1. Broadway DC. *Comm Eye Health.* 2012;25:66–70; 2. Rulli E, et al. *Sci Rep*. 2018;8:619; 3. Boyd K. 2022. Available at: www.aao.org/eye-health/diseases/what-is-glaucoma (accessed 20 October 2023).

What are your key considerations when selecting an IOL for patients with mild and well-controlled glaucoma?

IOL selection: Mild or well-controlled glaucoma

In patients with glaucoma suspect, ocular hypertension, or early glaucoma that is well controlled and shows no signs of progression, IOL selection should be based on the desired refractive outcomes and glaucoma progression[1]

IOL	Distance vision	Intermediate vision	Near vision	Spectacle independence	Low levels of glare and halos
Monofocal[2,3]	Good	Moderate	Poor	Poor	Good
Multifocal*[2–4]	Good	Good	Good	Good	Moderate
EDOF[2,4]	Good	Good	Moderate	Moderate	Moderate

Good Moderate Poor

*Depending on the IOL model, visual acuity between focal points and optimal vision distances may vary.[4]
EDOF, extended depth of focus; IOL, intraocular lens.

1. Yeu E, Cuozzo S. *Ophthalmology.* 2021;128:e132–41; 2. Auffarth GU, et al. *J Cataract Refract Surg.* 2021;47:184–91;
3. de Silva SR, et al. *Cochrane Database Syst Rev.* 2016;12:CD003169; 4. Kondylis G, et al. *Ann Eye Sci.* 2019;4:5.

What are your key considerations when selecting an IOL for patients with moderate or severe glaucoma?

Features of moderate or severe glaucoma that influence IOL selection

Contrast sensitivity
Glaucoma is associated with a loss of contrast sensitivity, which correlates with the degree of structural and functional glaucomatous damage

Pupil size
Eyes with glaucoma tend to have smaller pupils than non-glaucomatous eyes and this can impair the performance of pupil-dependent IOL technologies

Zonular weakness
Pseudoexfoliative glaucoma may be associated with zonular weakness, which can lead to IOL decentration that can impair IOL performance and induce higher-order aberrations

Co-existing ocular surface disease
Dry eye and ocular surface disease can be common in patients with glaucoma, especially in those taking multiple medications containing preservatives

Other factors to consider preoperatively:

- Visual field loss
- IOP control
- Retinal nerve fibre and ganglion cell analyses
- Optic disc appearance
- Co-existing retinal/macular disease
- Therapy adherence
- Risk factors for progression

IOL, intraocular lens; IOP, intraocular pressure.

Kerr N. 2022. Available at: www.mieducation.com/pages/iol-selection-in-patients-with-glaucoma (accessed 14 September 2023).

IOL selection: Moderate or severe glaucoma

Multifocal and EDOF lenses are generally contraindicated in patients with severe glaucoma or central visual field defects, and in those at high risk for progression[1]

IOL	Distance vision	Intermediate vision	Near vision	Spectacle independence	Low levels of glare and halos
Monofocal[2,3]	Good	Moderate	Poor	Poor	Good
Multifocal*[2–4]	Good	Good	Good	Good	Moderate
EDOF[2,4]	Good	Good	Moderate	Moderate	Moderate

Good Moderate Poor

*Depending on the IOL model, visual acuity between focal points and optimal vision distances may vary.[4]
EDOF, extended depth of focus; IOL, intraocular lens.

1. Kerr N. 2022. Available at: www.mieducation.com/pages/iol-selection-in-patients-with-glaucoma (accessed 14 September 2023);
2. Auffarth GU, et al. *J Cataract Refract Surg.* 2021;47:184–91; 3. de Silva SR, et al. *Cochrane Database Syst Rev.* 2016;12:CD003169;
4. Kondylis G, et al. *Ann Eye Sci*. 2019;4:5.

touch™ OPHTHALMOLOGY

How do you counsel your patients with glaucoma prior to cataract surgery in terms of expected outcomes?

Predicting outcomes of cataract surgery in patients with glaucoma

Association between preoperative VFI and MD and mean BCVA 2 months after surgery (N=63*)[1]

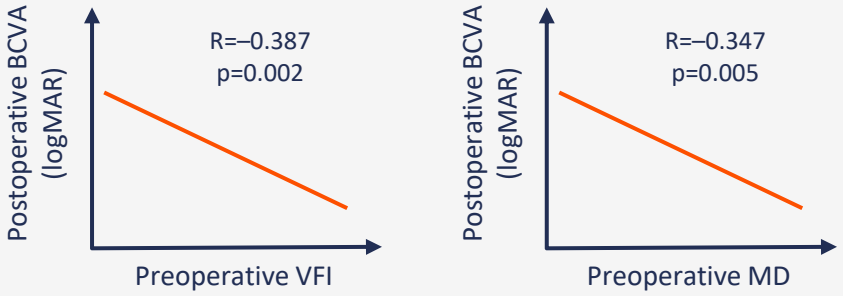

The higher the preoperative VFI or MD, the better the postoperative BCVA[1]

Clinical outcomes 10 years after cataract surgery in patients with primary angle-closure glaucoma (N=39*)[2]

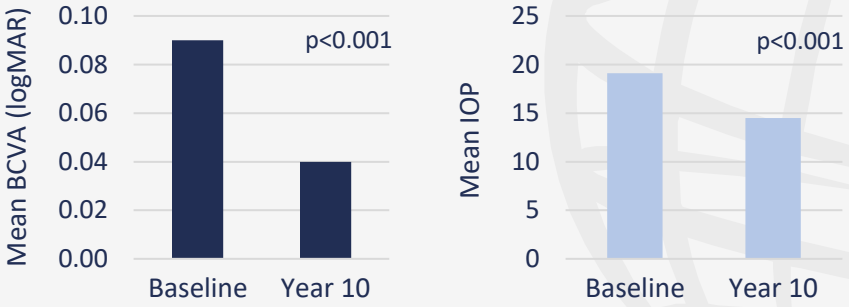

Improved mean BCVA and IOP were reported up to 10 years after cataract surgery[2]

*N represents the number of eyes.
BCVA, best-corrected visual acuity; IOP, intraocular pressure; logMAR, logarithm of the minimum angle of resolution; MD, mean defect; VFI, visual field index.
1. Hu T, et al. *Ophthalmic Res.* 2023;66:620–26; 2. Sakai D, et al. *Jpn J Ophthalmol.* 2023;67:129–37.

touch™ OPHTHALMOLOGY

Considerations for patients with cataracts and AMD

Dr Jennifer Loh

Loh Ophthalmology Associates
Miami, FL, USA

touch™ OPHTHALMOLOGY

What are the different types of AMD and how do each affect vision in patients?

Age-related macular degeneration (AMD)

Healthy eye

Late geographic atrophy

- Reduced contrast sensitivity[1]
- Scotomas[1]
- Loss of central vision[1,2]



Late neovascular AMD

- Straight lines look wavy[3]
- Colours seem less bright[3]
- Often leads to rapid loss of central vision[2]

Fundus images: Pepermpron/stock.adobe.com. Tree image: Modified from www.pexels.com/photo/green-tree-on-grass-field-during-daytime-53435/ (CC0).

1. Bakri S, et al. *J Manag Care Spec Pharm.* 2023;29:S2–11; 2. Macular Disease Foundation Australia. Available at: www.mdfoundation.com.au/about-macular-disease/age-related-macular-degeneration/stages-of-amd/ (accessed 18 October 2023); 3. National Eye Institute. Available at: www.nei.nih.gov/learn-about-eye-health/eye-conditions-and-diseases/age-related-macular-degeneration (accessed 18 October 2023).

touch™ OPHTHALMOLOGY

Does cataract surgery affect the development or progression of AMD?

Cataract surgery and AMD progression

Association between cataract surgery and progression/development of AMD*

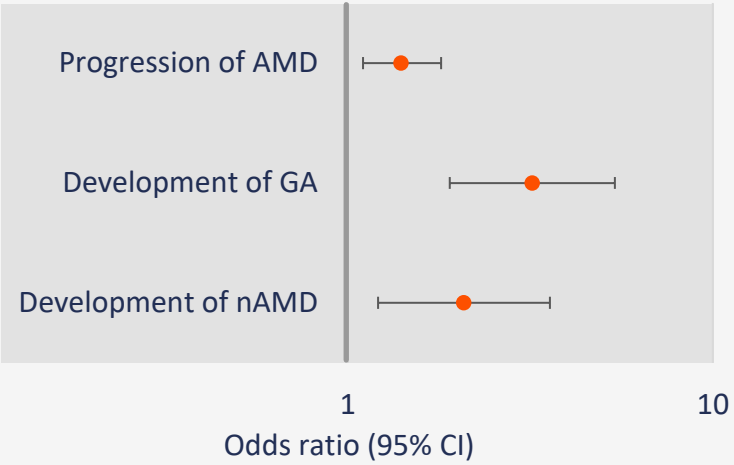

Cataract surgery was significantly associated with an increased risk of late AMD development and AMD progression

Association between cataract surgery and progression/development of AMD by follow-up duration*

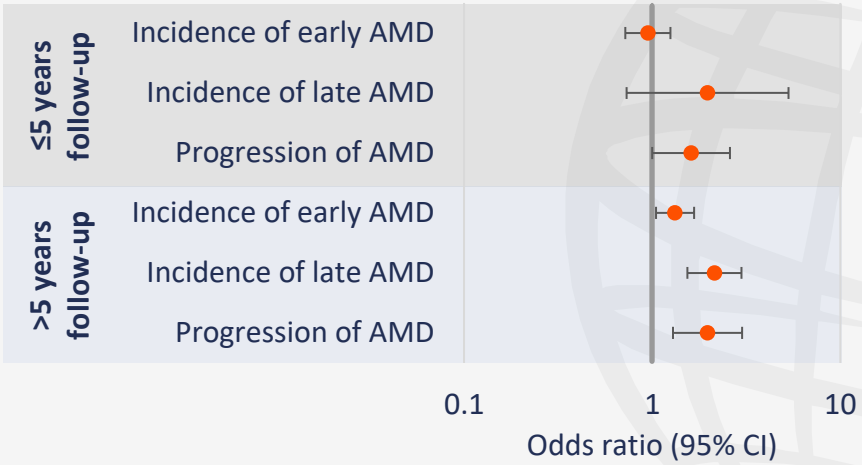

Cataract surgery was significantly associated with the incidence of early and late AMD and progression of AMD in patients with a follow-up of >5 years

*Data from a systematic review and meta-analysis that included 12 population-based cohort studies, two randomized controlled trials and one case-control study.
AMD, age-related macular degeneration; CI, confidence interval; GA, geographic atrophy; nAMD, neovascular age-related macular degeneration.
Yang L, et al. *J Ophthalmol.* 2022;2022:6780901.

touch™ OPHTHALMOLOGY

What are your key considerations when selecting an IOL for patients with AMD?

IOL selection in patients with AMD

Multifocal IOLs are relatively contraindicated[1,2] and evidence supporting the use of EDOF IOLs in patients with AMD is lacking.[2] Toric lenses can be used if there is significant astigmatism[2]

IOL	Distance vision	Intermediate vision	Near vision	Spectacle independence	Low levels of glare and halos
Monofocal[3,4]	Good	Moderate	Poor	Poor	Good
Multifocal*[3–5]	Good	Good	Good	Good	Moderate
EDOF[3,4]	Good	Good	Moderate	Moderate	Moderate
Toric†[6]	Good	Good	Good	Moderate	Moderate

Magnifying or **prism-based** lenses may also be beneficial for patients with AMD[2]

Good Moderate Poor

*Visual acuity between focal points and optimal vision distances may vary between IOL models.[5] †Effect on intermediate vision, spectacle dependence and level of glare and halos varies between bifocal and trifocal toric lenses.[6]
AMD, age-related macular degeneration; EDOF, extended depth of focus; IOL, intraocular lens.

1. Yeu E, Cuozzo S. *Ophthalmology.* 2021;128:e132–41; 2. Mehta H. *J Clin Med.* 2021;10:2538; 3. Auffarth GU, et al. *J Cataract Refract Surg.* 2021;47:184–91; 4. de Silva SR, et al. *Cochrane Database Syst Rev.* 2016;12:CD003169; 5. Kondylis G, et al. *Ann Eye Sci.* 2019;4:5; 6. Gencer MB, et al. *Int J Ophthalmol.* 2021; 14:1876–81.

touch™ OPHTHALMOLOGY

How do you counsel your patients with AMD prior to cataract surgery in terms of expected outcomes?

Predicting outcomes of cataract surgery in patients with AMD

Association between VA 6 months before surgery and 6 months after surgery in eyes with AMD (N=168)[1]

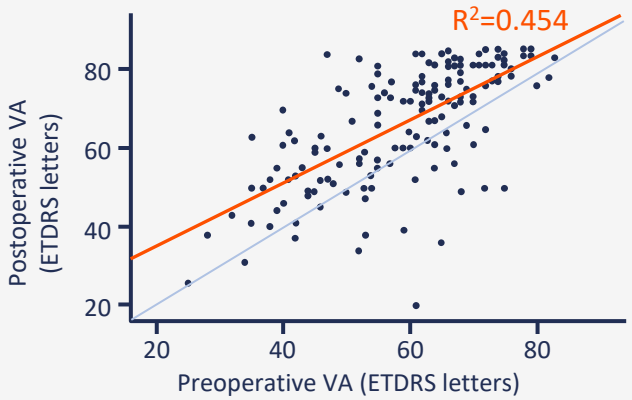

A higher preoperative VA was associated with a higher VA after cataract surgery[1]

Clinical outcomes 1 year after cataract surgery in eyes with neovascular AMD (N=111)[2]

	At cataract surgery	At 1 year
BCVA (logMAR)	0.70	0.33
CSMT (µm)	280.1	265.9
Foveal thickness (µm)	259.8	233.7
Anti-VEGF treatment interval (weeks)	6.53	7.03

Improvements in BCVA, CSMT and foveal thickness were seen up to 1 year after cataract surgery[2]

Figure reproduced from Tang Y, et al. *BMC Ophthalmology.* 2023;23:276 (CC BY 4.0).
AMD, age-related macular degeneration; BCVA, best-corrected visual acuity; CSMT, central subfield macular thickness; ETDRS, Early Treatment Diabetic Retinopathy Study; logMAR, logarithm of the minimum angle of resolution; VA, visual acuity; VEGF, vascular endothelial growth factor.

1. Tang Y, et al. *BMC Ophthalmology.* 2023;23:276; 2. Karesvuo P, et al. *Acta Ophthalmologica.* 2022;100:e262–69.

touch™ OPHTHALMOLOGY

Considerations for patients with cataracts and diabetic retinopathy

Dr Jennifer Loh

Loh Ophthalmology Associates
Miami, FL, USA

touch™ OPHTHALMOLOGY

What are the main strategies for assessing and managing DR and DMO?

Patients with diabetes: Initial management

Severity of retinopathy	Macular oedema	Follow-up (months)	PRP	Focal and/or grid laser	Anti-VEGF
Normal or minimal NPDR	No	12	No	No	No
Mild NPDR	No	12	No	No	No
	NCI-DMO	3–6	No	Sometimes	No
	CI-DMO	1	No	Rarely	Usually
Moderate NPDR	No	6–12	No	No	No
	NCI-DMO	3–6	No	Sometimes	Rarely
	CI-DMO	1	No	Rarely	Usually
Severe NPDR	No	3–4	Sometimes	No	Sometimes
	NCI-DMO	2–4	Sometimes	Sometimes	Sometimes
	CI-DMO	1	Sometimes	Rarely	Usually
Non-high-risk PDR	No	3–4	Sometimes	No	Sometimes
	NCI-DMO	2–4	Sometimes	Sometimes	Sometimes
	CI-DMO	1	Sometimes	Sometimes	Usually
High-risk PDR	No	2–4	Recommended	No	Sometimes
	NCI-DMO	2–4	Recommended	Sometimes	Sometimes
	CI-DMO	1	Recommended	Sometimes	Usually

- No
- Rarely
- Sometimes
- Usually
- Recommended

CI-DMO, centre-involving diabetic macular oedema; NCI-DMO, non-centre-involving diabetic macular oedema; NPDR, non-proliferative diabetic retinopathy; PDR, proliferative diabetic retinopathy; PRP, panretinal photocoagulation; VEGF, vascular endothelial growth factor.

Flaxel CJ, et al. *Ophthalmology*. 2020;127:66–145.

touch™ OPHTHALMOLOGY

How does DR severity affect clinical outcomes following cataract surgery?

Visual acuity outcomes following cataract surgery in patients with DR

Median VA at baseline and follow-up after phacoemulsification and IOL implantation cataract surgery by DR grade in people with diabetes

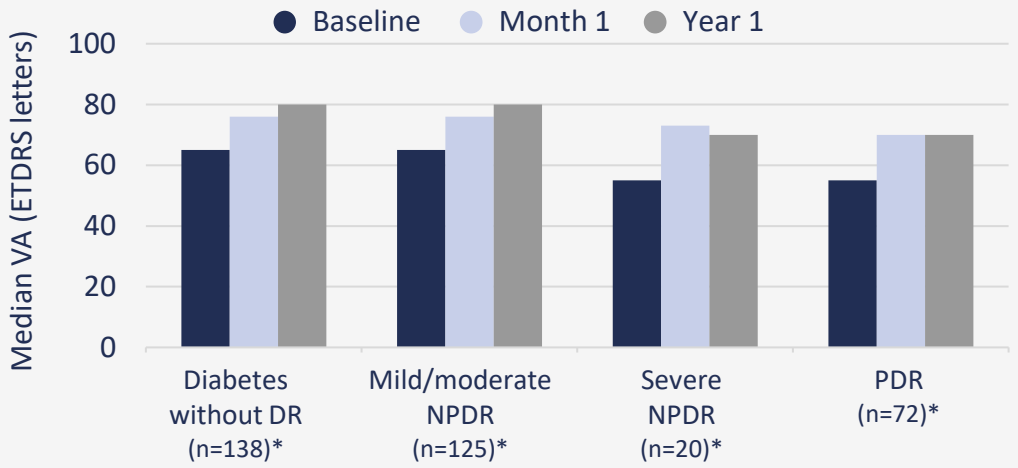

Median VA improved in people with diabetes with or without DR up to 1 year after cataract surgery

*n represents number of eyes at baseline.
DR, diabetic retinopathy; ETDRS, Early Treatment Diabetic Retinopathy Study; IOL, intraocular lens; NPDR, non-proliferative diabetic retinopathy; PDR, proliferative diabetic retinopathy; VA, visual acuity.
Han MM, et al. *Ophthalmol Retina.* 2020;4:351–60.

touch™ OPHTHALMOLOGY

Macular oedema outcomes following cataract surgery in patients with DR

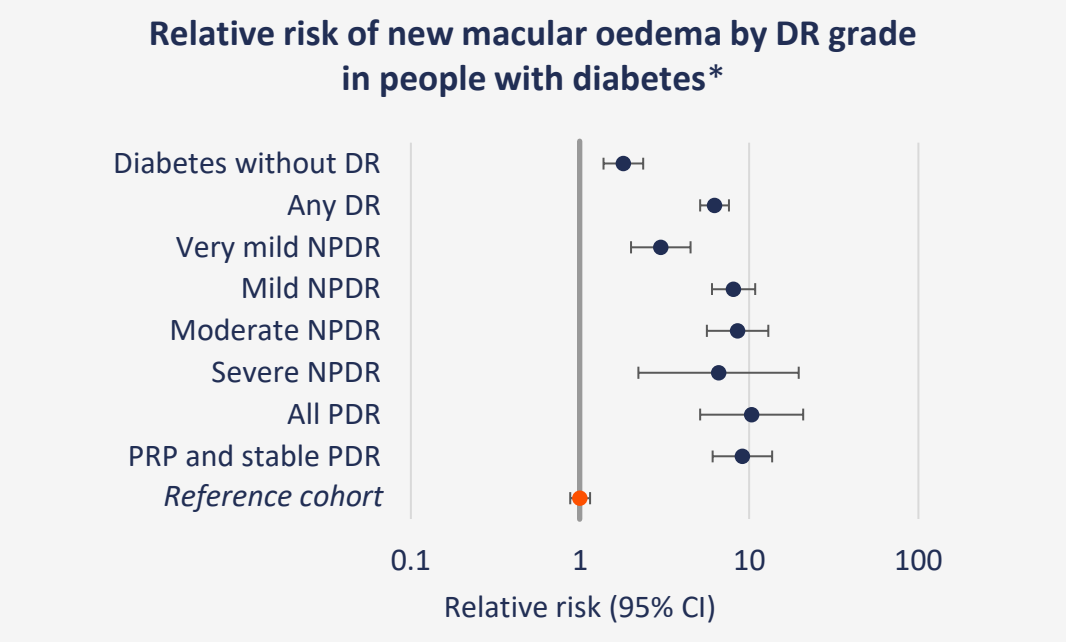

People with diabetes, with or without DR, are at significantly higher risk for developing new macular oedema after cataract surgery than those without diabetes

*Study included patients with diabetes without DR or maculopathy (2807 eyes) and those with DR but no preoperative maculopathy (1678 eyes) vs the reference cohort of patients with no diabetes, operative complications or co-pathologic features except amblyopia (35,563 eyes). CI, confidence interval; DR, diabetic retinopathy; NPDR, non-proliferative diabetic retinopathy; PDR, proliferative diabetic retinopathy; PRP, panretinal photocoagulation.

Chu CJ, et al. *Ophthalmology.* 2016;123:316–23.

touch™ OPHTHALMOLOGY

What are your key considerations when selecting an IOL for patients with DR?

Preoperative considerations for patients with DR

Glycaemic control

Uncontrolled diabetes can cause changes in topography and lead to errors in IOL power calculation.[1] Control of diabetes, blood pressure and lipids is critical to reduce the risk of postoperative macular oedema and endophthalmitis, promote corneal wound healing and hasten vision recovery[2]

Comprehensive ophthalmologic examination is essential

Including VA/BCVA, relative afferent pupillary defect, slit-lamp biomicroscopy to assess corneal health and neovascularization of the iris, tonometry, and dilated fundoscopy and gonioscopy.[3] Preoperative PRP is recommended in patients with PDR because of rapid progression and development of retinal complications after cataract surgery[1,3]

Maculopathy control

Preoperative control of maculopathy (achieving a static central foveal thickness on OCT on two consecutive monthly visits) is necessary to prevent postoperative deterioration of macular oedema[1–3]

Timing DMO treatment

Intravitreal anti-VEGF ≤14 days before cataract surgery is best for reducing macular thickness during the first postoperative month.[2] Triamcinolone acetonide should be given earlier.[2] When prompt cataract surgery is recommended, patients may benefit from intraoperative intravitreal anti-VEGF or steroids[2,3]

BCVA, best-corrected visual acuity; DMO, diabetic macular oedema; DR, diabetic retinopathy; IOL, intraocular lens; OCT, optical coherence tomography; PDR, proliferative diabetic retinopathy; PRP, panretinal photocoagulation; VA, visual acuity; VEGF, vascular endothelial growth factor.

1. Morya AK, et al. *World J Clin Cases.* 2023;11:3736–49; 2. Chan LKY, et al. *Front Endocrinol.* 2023;14:1106706; 3. Kelkar A, et al. *Indian J Ophthalmol.* 2018;66:1401–10.

IOL selection in patients with DR

Not recommended

Multifocal or accommodative IOLs[1–4]
Can reduce contrast sensitivity or VA and hamper postoperative laser treatment, and fundus visualization during vitrectomy due to the optics

Toric IOLs[3]
VA may change over time, reducing IOL effectiveness

Silicone IOL[2]
Silicone oil may be used later for surgical management of severe DR, which may condense on silicone IOLs

Hydrophilic acrylic IOLs[1,4]
Can opacify, especially in patients with PDR, due to high levels of phosphorous in the serum and aqueous humour

Recommended

Monofocal IOLs[2]
Good distance vision but patient may require spectacles for near-vision activities

Square edge IOLs[1]
Inhibits lens epithelial cell proliferation and therefore prevents opacification

Large diameter IOLs[4]
Facilitate visualization and treatment of the peripheral retina

Hydrophobic acrylic IOLs[2,4]
Low risk for posterior capsular opacification; IOL should retain clarity if future retinal intervention is required, but can cause early postoperative anterior-chamber flare

DR, diabetic retinopathy; IOL, intraocular lens; PDR, proliferative diabetic retinopathy; VA, visual acuity.

1. Morya AK, et al. *World J Clin Cases.* 2023;11:3736–49; 2. Bixler JE. 2019. Available at: www.ncbi.nlm.nih.gov/books/NBK544518/ (accessed 19 October 2023);
3. Mukamal R. 2021. Available at: www.aao.org/eye-health/tips-prevention/diabetes-vision-eye-exam-care-cataract-glaucoma (accessed 20 October 2023);
4. Kelkar A, et al. *Indian J Ophthalmol.* 2018;66:1401–10.

How do you counsel your patients with DR prior to cataract surgery in terms of expected outcomes?

Managing expectations for cataract surgery in patients with DR

Patient expectations[1]

- Good visual acuity
- Reduced spectacle dependence[2]
- No complications
- Satisfactory results

Key considerations[3]

- Highlight the risks of initiation or progression of macular oedema and suboptimal vision gain early to avoid patient dissatisfaction
- Highlight the importance of perioperative control of systemic cardiovascular risk factors
- Highlight the importance of macular oedema control prior to cataract surgery and possible delay to cataract surgery
- Advise that anti-VEGF therapy may still be required postoperatively

DR, diabetic retinopathy; VEGF, vascular endothelial growth factor.

1. Salerno LC, et al. *Taiwan J Ophthalmol.* 2017;7:179–84; 2. Yeu E, Cuozzo S. *Ophthalmology.* 2021;128:e132–41; 3. Chan LKY, et al. *Front Endocrinol.* 2023;14:1106706.

How do you approach cataract surgery for patients with diabetes but who have not yet developed DR?

Preoperative considerations for patients with diabetes without DR

Cataract treatment options

People with diabetes may benefit from laser cataract surgery (phacoemulsification) due to reduced postoperative inflammation and quicker visual rehabilitation compared with intra- or extracapsular cataract surgery[1]

IOL selection and risk of disease progression

IOL implants are considered permanent, so IOL selection should account for the possible development of macular disease in the future. Patients with an IOL contraindicated for macular pathology (e.g. multifocal IOLs) who later develop macular disease may experience vision compromise[2]

Managing expectations

Monofocal IOLs that are well focused for distance vision may require patients to wear spectacles for near-vision activities regardless of their preoperative accommodation.[2] Candidates for cataract surgery should also be counselled regarding risk of initiation or progression of DR[1]

DR, diabetic retinopathy; IOL, intraocular lens.

1. Amoaku WM, et al. *Eye.* 2020;34:1–51; 2. Bixler JE. 2019. Available at: www.ncbi.nlm.nih.gov/books/NBK544518/ (accessed 19 October 2023).

touch™ OPHTHALMOLOGY