



Optical Coherence Tomography Evaluation of Macular Oedema after Corneal Graft

a report by

Olivier Genevois, Etienne Gardea, Gérard Brasseur and Marc Muraine

Hospital Charles Nicolle, Department of Ophthalmology, University of Rouen

DOI: 10.17925/EOR.2007.00.00.25

Macular oedema (MO) is an established complication of intraocular surgery and is one of the leading causes of poor post-operative visual acuity after keratoplasty.¹⁻⁷ MO is a localised expansion of the retinal intracellular and/or extracellular space in the macular area. This tendency towards the macular region is probably associated with the loose binding of innerconnecting fibres in Henle's layer, allowing accumulation of fluid leaking from peri-foveal capillaries.

The aim of this study⁸ was to assess the incidence of MO following keratoplasty and to identify factors that are associated with oedema using optical coherence tomography (OCT). The device utilised was an OCT 3 (Stratus, Carl Zeiss Meditec, Dublin, California), the only device capable of providing a detailed analysis of retinal tissue, and an objective, reproducible and reliable measurement of retinal thickness.^{7,9}

OCT is a highly sensitive tool that allows reproducible measurements of retinal thickness with reproducibility of $\pm 5\%$. It is a more powerful investigative tool than the biomicroscopic or angiographic examinations previously reported in the literature: both are qualitative and insensitive to small changes in retinal thickness.

Materials and Methods

This prospective study involved 62 patients who were all operated on by the same surgeon. Informed consent was obtained from all patients. Forty-three (69.35%) underwent penetrating keratoplasty and 19 (30.65%) deep anterior lamellar keratoplasty (using the big-bubble technique). We realised a deep anterior keratoplasty with pathologies involving the corneal stroma and sparing the Descemet membrane. Combined surgery was performed for 20 patients. Of this number there were secondary implantations for nine patients, cataract extractions for eight and iris plasties for three. The indications for surgery were as follows: keratoconus in 18 cases, pseudophakic or aphakic keratopathy in 18 cases, Fuchs dystrophy in 10 cases, viral corneal scar in seven cases, re-graft in five cases and corneal oedema following closed angle glaucoma in four cases.

We analysed the morphological characteristics of the macula by OCT 3 one and three months after surgery using 'line group' mode, with 6mm sections centred on the patient's fixation point along various axes. We also measured central macular thickness (CMT). CMT was defined as the average thickness of a central macular region 1000 μ m in diameter, centred on the patient's foveola and automatically measured by OCT 3 and A5 mapping software (Humphrey Instruments, Dublin, California).

MO was defined as increased central retinal thickness, to more than 250 μ (retinal thickness in healthy eyes is 212 \pm 20 μ)⁸ with intra-retinal cystoid-like spaces that appeared as round or oval areas of low


reflectivity. OCT investigations before keratoplasty were not possible due to corneal transparency. Student's t-test and Fisher's test were used for statistical analysis.

Results

OCT carried out one and three months after surgery revealed normal macular profiles in 54 of the 62 patients (87.1%), typical MO in six patients (9.6%), macular atrophy in one patient (1.6%) and a vitreomacular traction syndrome in one patient (1.6%) (see *Figure 1*). All six patients with MO had the same profile after one and three months. Central foveolar thickness in the group of 62 patients was 243 \pm 77 μ after one month and 230 \pm 49 μ after three months ($p=0.93$). However, central

The device utilised was an OCT 3, the only device capable of providing a detailed analysis of retinal tissue, and an objective, reproducible and reliable measurement of retinal thickness.

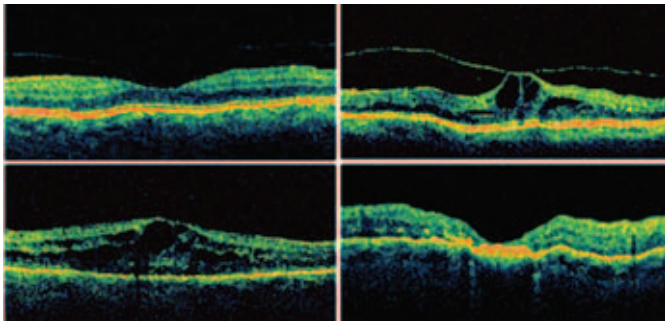
foveolar thickness was 216 \pm 21 μ at one month and 217 \pm 21 μ at three months in the group of patients without MO, but 401 \pm 87 μ at one month and 380 \pm 85 μ at three months in the group of patients with MO. There was a significant difference between the two groups after both one and three months ($p=0.0001$) for both. There was no significant change in the central foveolar thickness between months one and three in either group ($p=0.85$ with no MO, $p=0.61$ with MO). There was no significant difference between patients who had penetrating keratoplasty and those who had deep lamellar keratoplasty ($p=0.60$ after one month, $p=0.79$ after three months; see *Figure 2*). In contrast, central foveolar thickness differed significantly both after one month ($p=0.035$) and after three months ($p=0.017$) between patients who underwent keratoplasty alone and those who underwent combined surgery (see *Figure 3*). The indication for grafting appeared to be an important factor. OCT identified MO in two of four patients (50%) grafted for herpetic keratitis, but in only three of 18 patients (16.6%) grafted for aphakic or pseudophakic keratopathy and only one of 18 patients (5.5%) grafted for keratoconus.



Olivier Genevois is a Fellow in the Department of Ophthalmology at Rouen University Hospital, a position he has held since 2004. His clinical and research interests are in retinal disease. He obtained his degree from the Rouen Medical School in France in 1998, a Masters in microcirculation in 2002 and his MD in 2003.

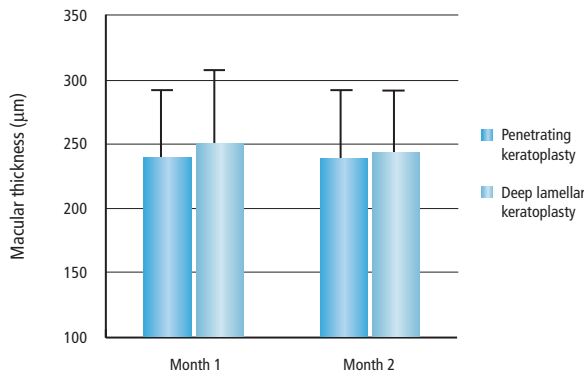


Figure 1: Macular Profile after Keratoplasty



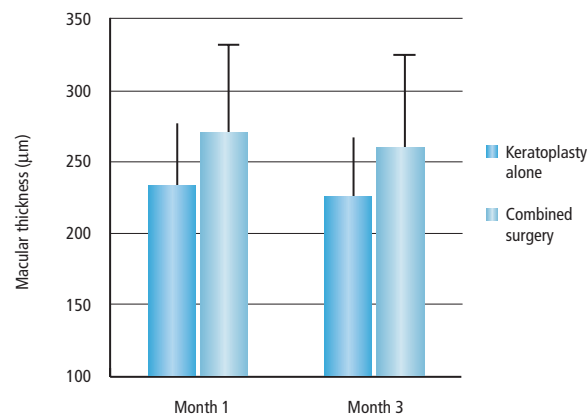
Top left: normal profile with foveal pit (87.1%). Bottom left: macular oedema with large intra-retinal hyporeflective spaces (9.6%). Top right: macular oedema with vitreo-macular traction (1.6%). Bottom right: macular atrophy (1.6%). Optical coherence tomography taken three months after surgery.

Figure 2: Macular Foveal Thickness One Month and Three Months after Penetrating Keratoplasty versus Deep Lamellar Keratoplasty



The difference is not significant. Normal foveal thickness on the OCT 3 (Stratus): 212±20µ.

Figure 3: Macular Foveal Thickness



One and three months after keratoplasty versus keratoplasty with cataract extraction or intraocular lens implantation or pupillary plasty. $p=0.035$ after one month, $p=0.017$ after three months. Normal foveal thickness as determined by OCT (Stratus): 212±20µ.

Discussion

MO is an established complication of intraocular surgery that may impair vision recovery. In our series of corneal graft patients, the incidence was 9.6% lower than that reported in the literature,¹⁻⁶ where incidences of 10–36% have been described. In addition, our value is probably an overestimate because pre-operative OCT was not performed (due to corneal transparency), and some patients may have had pre-operative MO. The difference between our series and those reported previously appears to be associated with the methods used. Also, image quality was not distorted by astigmatism or corneal transparency in any of these cases, demonstrating the value of OCT as a non-invasive examination.

Combined Surgery

Combined surgery significantly increased the incidence of MO, a finding that is unsurprising because oedema depends in part on the severity of the inflammatory reaction. In a retrospective study of uveitis patients undergoing surgery (extra-capsular cataract extraction and posterior chamber intraocular lens implantation), Foster et al.¹⁰ reported a 46% incidence of post-operative MO. It has been suggested that the risk of MO after surgery is greater in uveitis patients with severe post-operative uveitis and pre-operative anterior uveitis.

Combined surgery was associated with various pro-inflammatory factors: protracted surgery, larger incisions and uveal tissue irritation. A more severe, or recurrence of, inflammation could account for the higher risk of oedema in our patients grafted because of sequelae of herpetic kerato-uveitis.

Conversely, the surgical technique used – involving either an open globe (penetrating keratoplasty) or a closed globe (deep anterior lamellar keratoplasty) – surprisingly had no impact on oedema occurrence. This may be due to the shorter operating time for penetrating keratoplasty (25–45 minutes) than for the new lamellar surgical techniques (up to 90 minutes to strip the Descemet’s membrane and for the grafting procedure).

Cystoid MO is one of the leading causes of poor visual acuity after ocular surgery. After heratoplasty, MO therefore appeared to be a less frequent complication than expected (9.6%), and was unrelated to the grafting technique used. In contrast, combined surgery and herpes keratitis appeared to be risk factors for MO. A further study with a larger population of patients and longer follow-up is warranted to confirm our findings and to ascertain whether, and which, pre-operative inflammatory disease increases the risk of post-operative MO. ■

Acknowledgement

We thank Richard Medeiros, medical editor at Rouen University Hospital, for editing the manuscript.

- Holland EJ, Daya SM, Evangelista A, et al., Penetrating keratoplasty and transscleral fixation of posterior chamber lens, *Am J Ophthalmol*, 1992;114:182–7.
- Farjo AA, Rhee DJ, Soong HK, et al., Iris-sutured posterior chamber intraocular lens implantation during penetrating keratoplasty, *Cornea*, 2004;23:18–28.
- Kornmehl EW, Steinert RF, Odrich MG, et al., Penetrating keratoplasty for pseudophacic bullous keratopathy associated with closed-loop anterior chamber intraocular lenses, *Ophthalmology*, 1990;97:407–12.
- Insler MS, Kook MS, Kaufman HE, Penetrating keratoplasty for pseudophacic bullous keratopathy associated with semiflexible, closed-loop anterior chamber intraocular lenses, *Am J Ophthalmol*, 1989;107:252–6.
- Soong HK, Musch DC, Kowal V, et al., Implantation of posterior chamber intraocular lenses in the absence of lens capsule during penetrating keratoplasty, *Arch Ophthalmol*, 1989;107:660–65.
- Muraine M, Sanchez C, Watt L, et al., Long-term results of penetrating keratoplasty. A 10-year-plus retrospective study, *Graefes Arch Clin Exp Ophthalmol*, 2003;241:571–6.
- Massin P, Vicaut E, Haouchine B, et al., Reproducibility of retinal mapping using optical coherence tomography, *Arch Ophthalmol*, 2001;119:1135–42.
- Genevois O, Benzerroug M, Gardea E, et al., Macular edema after corneal graft: a prospective study by optical coherence tomography, *Cornea*, 2007;26(6):683–4.
- Chan A, Duker JS, Ko TH, et al., Normal macular thickness measurements in healthy eyes using Stratus optical coherence tomography, *Arch Ophthalmol*, 2006;124(2):193–8.
- Foster RE, Lowder CY, Meisler DM, Zakov ZN, Extracapsular cataract extraction and posterior chamber intraocular lens implantation in uveitis patients, *Ophthalmology*, 1992;99(8):1234–41.