

Management Options in Pediatric Cataract

Abhay R Vasavada, MS,¹ FRCS, Sajani K Shah, MS² and Vaishali Vasavada, MS²

1. Director; 2. Consultant, Iladevi Cataract and IOL Research Center, Ahmedabad

Abstract

Pediatric cataract surgery remains a very important and difficult problem to manage and involves a team effort, the most important members of which are parents. While dramatic advances have occurred in this field during the past 10 years, some technical aspects of surgery, changing refraction, and functional outcome continue to pose significant problems. Manual capsulorhexis remains the gold standard for a successful outcome of pediatric cataract surgery as well as in deciding intraocular lens (IOL) placement. Primary management of the posterior capsule with or without anterior vitrectomy is mandatory depending on age of the child at surgery. Primary implantation of the IOL after cataract removal is gaining popularity, even for infants and young children. Predicting axial growth and the refractive change that accompanies it is one of the major challenges for the long-term care of children after surgery. The evaluation of rate of axial growth and its correlation with age at surgery, laterality, aphakia/pseudophakia, and visual axis obscuration is a positive step in this direction. Finally, appropriate visual rehabilitation and amblyopia therapy are the cornerstones for the child's final visual development.

Keywords

Pediatric cataract surgery, congenital cataract, posterior capsule, visual axis opacification, anterior vitrectomy, visual rehabilitation

Disclosure: The authors have no conflicts of interest to declare.

Received: October 1, 2011 **Accepted:** November 11, 2011 **Citation:** *US Ophthalmic Review*, 2012;5(1):44–7 DOI: 10.17925/USOR.2012.05.01.44

Correspondence: Abhay R Vasavada, MS, FRCS, Iladevi Cataract & IOL Research Center, Raghudeep Eye Clinic, Gurukul Road, Memnagar, Ahmedabad 380052, India. E: icirc@abhayvasavada.com

Over the past decade, advances in technology and refinements in surgical techniques have brought pediatric cataract surgery into the modern age. Automation and the use of intraocular lenses (IOLs) have facilitated better anatomical and functional outcomes. At one point, lensectomy was the standard treatment used in such cases. However, in recent times, small incisions, anterior capsulorhexis, bimanual irrigation/aspiration, and primary posterior capsulectomy and vitrectomy have become acceptable treatment options for infantile cataract. IOL implantation has become the standard of care for the optical rehabilitation of children with cataract, from the toddler age group and up.

Pediatric cataract surgery is a complex issue best left to surgeons familiar with its long-term complications and lengthy follow-up. Treatment is often difficult and tedious and requires a dedicated team effort, the most important of which are parents.

Indications for Surgery

Visually significant cataract in children calls for prompt surgical intervention to clear the ocular media and provide a focused retinal image. The timing of treatment is crucial to the visual development and successful rehabilitation of children, especially during early infancy. In cases of a unilateral dense cataract diagnosed at birth, the surgeon can wait until the patient is four to six weeks of age.¹ In the case of bilateral cataract diagnosed at birth, a good visual outcome can be achieved if the child is operated before 10 weeks of age.² It is

important to keep the time interval between the surgeries performed on the two eyes to a minimum.

Pre-operative Evaluation

The importance of counseling parents cannot be overstressed. Parents should understand that treatment of the child starts only after surgery. They need to come for regular follow-up visits, see that the child wears glasses or contact lenses (CLs) despite the IOL implantation, and realize that the child may need occlusion therapy following surgery

The pre-operative examination includes age-appropriate vision testing and details of strabismus and nystagmus. Visual function in older children can be assessed with charts, such as preferential looking charts (Teller acuity card, Keeler), Lea gratings and symbols (Precision vision, Lasalle), Sheridan Gardiner tests, and 'E' charts or Snellen's charts. In very young children, who cannot co-operate for vision tests, the ability to fixate or follow light or objects should be assessed. The presence of squint or nystagmus should be recorded. A pre-operative examination with fully dilated pupils, if necessary under anesthesia, is mandatory in both the eyes prior to surgery. It includes examination under the operating microscope or slit-lamp biomicroscope to assess the type of cataract and intraocular pressure to rule out any association of glaucoma. The examination should also include measurement of the corneal diameter, posterior segment evaluation, keratometry, biometry, gonioscopy, and ultrasound biomicroscopy.

Clinical examination of the child should include a complete examination of all systems, including respiratory, nervous, and cardiovascular systems. Supportive laboratory investigations should include hemogram, blood sugar, titers for antibodies to TORCH agents (toxoplasmosis, other infections, rubella, cytomegalovirus, and herpes simplex virus), HIV, hepatitis B surface antigen, and X-rays, and echocardiography if required. Special tests to rule out metabolic diseases should be ordered whenever necessary.

Surgical Technique

Anterior Capsule Management

Anterior capsulorhexis is the anchor for pediatric cataract management, as it determines the surgical strategy and site of IOL fixation. The anterior capsule in children is very elastic, and therefore it may be difficult to perform a controlled manual continuous curvilinear capsulorhexis (CCC). However, it remains a gold standard for resistance to tearing and should be accomplished whenever possible. Difficulties in performing manual CCC in the infantile eye led researchers and surgeons to search for alternative methods to open the anterior capsule in children. Alternatives to manual CCC currently available include vitrectorhexis, radiofrequency diathermy with a Fugo plasma blade, the two-incision push-pull technique, and the four-incision technique.³⁻⁶ Wilson et al. analyzed pediatric anterior capsulotomy techniques in the porcine model and found that manual capsulorhexis produced the most extensible capsulotomy with the most regular and stable edge.⁷ In eyes with poor anterior capsule visibility, trypan blue (0.0125 %) was used to stain the anterior capsule. The shape, size, and edge integrity of anterior capsulotomy are very important for the long-term centration of the IOL (*Figure 1*).

Management of the Posterior Capsule and Anterior Vitreous Face

The most frequent and significant problem following pediatric cataract surgery is visual axis opacification (VAO).⁸⁻¹³ (*Figure 2*). Maintenance of a clear visual axis remains a high priority when planning management of the posterior capsule in the amblyogenic age range. An important question that remains is when should the posterior capsule be left intact? Primary posterior capsulectomy (with or without anterior vitrectomy) are considered 'routine surgical steps,' especially in young children.¹⁴⁻²⁰ Posterior capsulotomy can be performed using various approaches, including manual posterior continuous curvilinear capsulorhexis (PCCC), vitrectorhexis, radiofrequency diathermy, and the Fugo plasma blade.^{21,22} Manual PCCC is performed before IOL implantation, whereas, if a pars plana vitrectomy is performed, it is done after the IOL is implanted.^{23,24} The size of the posterior capsulorhexis should be large enough to provide a clear central visual axis, but smaller than the IOL optic, so as to allow stable in-the-bag IOL fixation. Manual PCCC offers the advantage of a controlled size and strong edges, but is more difficult to perform (*Figure 3*).

A potential complication associated with this procedure is disruption of the anterior vitreous face (AVF).²⁵ The signs of AVF disruption vary from subtle to obvious, and include:

- the presence of vitreous strands in the anterior chamber;
- the attachment of the vitreous to the capsular flap; and
- distortion of the capsulorhexis margin.

Figure 1: Well-centered, Symmetric Anterior Capsulorhexis

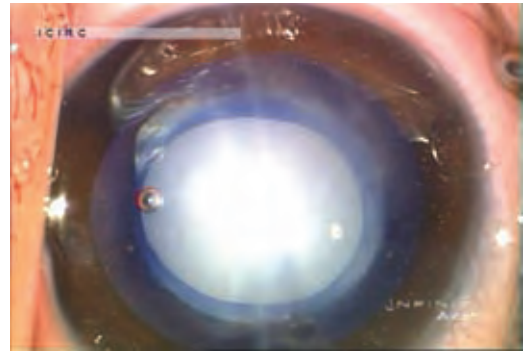


Figure 2: Postoperative Images of Posterior Capsule Opacification with Primary Posterior Continuous Curvilinear Capsulorhexis

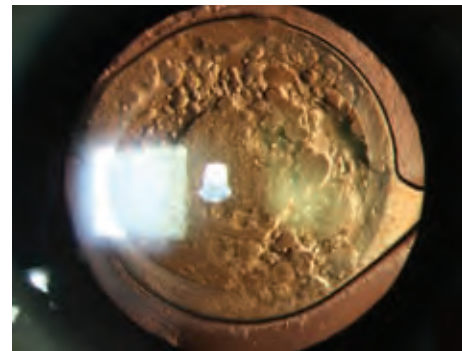




Figure 3: A Well-centered Primary Posterior Continuous Curvilinear Capsulorhexis Concentric to and Smaller than the Anterior Capsulorhexis Allows Safe in the Bag IOL Implantation



Recently, we described a technique to render the vitreous visible to the anterior segment surgeon. On completion of the PCCC, 0.1 ml of a suspension of preservative free triamcinolone acetonide (Aurocort) was injected for visualizing the AVF as well as the presence and extent of vitreous in the anterior chamber.^{26,27} After vitrectomy, if the surgeon has not cleared the residual vitreous strands triamcinolone can now be used second time to identify clearly the superficial vitreous gel, which may have otherwise gone unnoticed. After IOL implantation and removal of the residual ophthalmic viscosurgical device, the surgeon again injects 0.1 ml of the suspension into the anterior chamber. Additional anterior vitrectomy is performed if vitreous strands are identified in the anterior chamber.

Figure 4: A Central Clear Visual Axis after Performing Optic Capture



Intraocular Lens Implantation

One of the most important pre-operative considerations is whether to implant an IOL or not. Surgeons should be prepared for the common question “Would you implant an IOL if this were your child?” The capability of the IOL to offer constant visual input is an important advantage for a better visual outcome after pediatric cataract surgery. Use of IOL provides at least a partial optical correction at all times. As a consequence of the advantage it offers, primary IOL implantation has slowly gained acceptance for the management of childhood cataracts. However, as of 2007, use of IOL remains controversial for the management of infantile cataract. The important concerns about primary IOL implantation during infancy are the technical difficulties of implanting an IOL and selecting an IOL power, and the higher rate of VAO.²⁸⁻³⁷ At present, only adult-sized IOLs are available, which are often difficult to implant in infantile eyes and may cause complications in the long run.

The size of the posterior capsulorhexis should be large enough to provide a clear central visual axis, but smaller than the IOL optic so as to allow stable in-the-bag IOL fixation. Even if the surgeon is not planning to implant an IOL in a specific eye, it is important to leave behind sufficient anterior and posterior capsular support at the time of cataract surgery to facilitate subsequent IOL implantation. The common practice is to perform posterior capsulectomy and anterior vitrectomy before IOL implantation if the limbal approach is used, whereas if a pars plana vitrectomy is performed, it is done after the IOL is implanted. Furthermore, there is no agreement as to whether the IOL should be implanted before or after the primary posterior capsulectomy. Some surgeons perform a pars plicata capsulectomy and vitrectomy with the vitrectome after implanting the IOL in the bag. Both polymethyl methacrylate and hydrophobic acrylic foldable IOLs have been widely used in pediatric eyes. However, several studies show that hydrophobic acrylic IOLs are preferable as they offer better uveal biocompatibility and a decreased incidence of VAO, with hydrophobic acrylic IOLs causing a delayed onset of posterior capsule opacification (PCO).³⁸⁻⁴² For bilateral cataract during the first year, aphakic glasses and/or CL use may be a reasonable option; however, for unilateral cataract, we are truly equipoised between whether or not to offer primary IOL implantation at the time of infantile cataract surgery. A large randomized clinical trial – the Infant Aphakia Treatment Study is currently underway to compare primary IOL implantation to CL correction in children undergoing unilateral cataract surgery in the first six months of life.

Secondary Intraocular Lens Implantation

Eyes that are left aphakic are likely to require a secondary IOL implantation. Even if the surgeon is not planning to implant an IOL primarily, it is important to leave behind sufficient anterior and posterior capsular support at the time of cataract surgery to facilitate in-the-bag or sulcus-fixated IOL implantation to allow ciliary sulcus or in-the-bag placement of an IOL once the child and eye grow.

Newer Approaches Optic Capture

An alternative technique to stabilize the IOL was introduced with the concept of capturing an IOL through anterior capsulorhexis. The haptics were placed in the ciliary sulcus and the IOL optic was then placed through the anterior capsulorhexis to ‘capture’ the IOL for stable optic fixation. This concept has been used to develop the technique of posterior capsulorhexis with optic capture through posterior capsulorhexis (haptics in the bag) to prevent PCO.⁴³⁻⁵¹

Conventional or posterior optic capture can be achieved by capturing the optic through anterior capsulorhexis (haptics in the ciliary sulcus, optic in the bag), both the rhexes (haptics in the ciliary sulcus, optic behind the posterior capsule), and posterior capsulorhexis (haptics in the bag, optic behind the posterior capsule). The third concept is also known as optic buttonholing. The posterior capsule lies on top of the IOL optic and the LECs, which are deviated anteriorly, no longer have access to the retrolenticular space. The optic–haptic junction is the only place in which there is no opposition between the leaflets of the anterior and posterior capsules (*Figure 4*).

Sealed Capsule Irrigation

Maloof and co-workers designed a sealed capsule irrigation device (Perfect Capsule™) that can help to irrigate the capsular bag selectively, which may help pediatric cataract surgeons to eliminate or delay VAO by using irrigation chemicals through this device.⁵²⁻⁵⁵

Manual Posterior Continuous Curvilinear Capsulorhexis via Pars Plana Approach

Vasavada and co-workers recently introduced a technique of performing manual PCCC via the pars plicata.⁵⁶ After implantation of the IOL in the capsular bag all the incisions are sutured with 10-0 nylon and residual Provisc is left in the anterior chamber. The pars plicata entry is made 1–1.5 mm behind the limbus and an initial puncture is made in the center of the posterior capsule and later a coaxial capsulorhexis forceps is introduced and a flap generated. The edge of the flap is grasped and then re-grasped every two clock hours, fashioning the PCCC in a clockwise manner.

Bag-in-the-lens Implantation

Tassignon and colleagues reported the outcome of a surgical procedure in pediatric cataractous eyes that they called ‘bag-in-the-lens’.^{57,58} In this technique, the anterior and posterior capsules are placed in the groove of a specially designed IOL after a capsulorhexis of the same size is created in both capsules. The principle behind this IOL design is to ensure a clear visual axis by mechanically tucking the two capsules into the IOL, and thereby prevent any migration of proliferating lens epithelial cells.

Sutureless Vitrectomy

The 25 as well as 23 gauge high-speed vitrectomes have found a growing number of applications in pediatric surgery via a pars plana approach or transcorneal approach.^{59,60} In a clinical series, it was found that the 25-gauge system offers several advantages when used in infantile cataract extraction. By using this system, the surgical wounds are rendered safe and secure. Moreover, when created with a flat paracentesis knife, the incisions do not need to be closed. The authors suggested that the 25-gauge vitrectomy system appears ideally suited for the management of congenital cataract in children younger than one year.^{59,60}

Heparin in Irrigating Solution

Heparin has been used in intraocular irrigating solutions to reduce inflammatory reactions after pediatric cataract surgery. It has

been documented that infusion of enoxaparin, a low molecular weight heparin, during pediatric cataract surgery may minimize the post-operative inflammatory response.⁶¹

Summary

While dramatic advances have occurred in this field over the past 10 years, some technical aspects of surgery, changing refraction, and functional outcome continue to pose significant problems. Primary management of the posterior capsule is mandatory depending on the age of the child at surgery. With refinements in surgical techniques, improvisation of IOLs, and better understanding of growth of the pediatric eye, in the coming years IOL implantation is likely to become an established mode of treatment of children, even in the youngest age group. ■

- Birch EE, Stager DR, The critical period for surgical treatment of dense congenital unilateral cataract, *Invest Ophthalmol Vis Sci*, 1996;37(8):1532-1538.
- Lambert SR, Lynn MJ, Reeves R, et al., Is there a latent period for the surgical treatment of children with dense bilateral congenital cataracts?, *J AAPOS*, 2006;10(1):30-36.
- Andreo LK, Wilson ME, Apple DJ, Elastic properties and scanning electron microscopic appearance of manual continuous curvilinear capsulorhexis and vitrectorhexis in an animal model of pediatric cataract, *J Cataract Refract Surg*, 1999;25:534-539.
- Nischal KK, Two-incision push-pull capsulorhexis for pediatric cataract surgery, *J Cataract Refract Surg*, 2002;28:593-595.
- Comer RM, Abdulla N, O'Keefe M, Radiofrequency diathermy capsulorhexis of the anterior and posterior capsules in pediatric cataract surgery: preliminary results, *J Cataract Refract Surg*, 1997;23(Suppl. 1):641-644.
- Singh D, Singh RT, Applications of the Fugo blade. In: Wilson ME, Trivedi RH, Pandey SK, Pediatric Cataract Surgery: Techniques, Complications, and Management, Philadelphia: Lippincott, Williams & Wilkins, 2005;97-100.
- Wilson ME Jr, Trivedi RH, Bartholomew LR, Pershing S, Comparison of anterior vitrectorhexis and continuous curvilinear capsulorhexis in pediatric cataract and intraocular lens implantation surgery: a 10-year analysis, *J AAPOS*, 2007;11(5):443-446.
- Parks MM, Posterior lens capsulectomy during primary cataract surgery in children, *Ophthalmology*, 1983;90:344-345.
- Knight-Nanan D, O'Keefe M, Bowell R, Outcomes and complications of intraocular lenses in children with cataract, *J Cataract Refract Surg*, 1996;22:730-736.
- BenEzra D, Cohen E, Posterior capsulectomy in pediatric cataract surgery: the necessity of a choice, *Ophthalmology*, 1997;104:2168-2174.
- Sharma N, Pushkar N, Dada T, et al., Complications of pediatric cataract surgery and intraocular lens implantation, *J Cataract Refract Surg*, 1999;25:1585-1588.
- Koch DD, Köhnen T, A retrospective comparison of techniques to prevent secondary cataract formation following posterior chamber intraocular lens implantation in infants and children. *Trans Am Ophthalmol Soc*, 1997;95:351-360; discussion: 361-365.
- Trivedi RH, Wilson ME Jr, Bartholomew LR, et al. Opacification of the visual axis after cataract surgery and single acrylic intraocular lens implantation in the first year of life, *J AAPOS*, 2004;8:156-164.
- Buckley EG, Klombers LA, Seaber JH, et al., Management of the posterior capsule during pediatric intraocular lens implantation, *Am J Ophthalmol*, 1993;115:722-728.
- Basti S, Ravishankar U, Gupta S, Results of a prospective evaluation of three methods of management of pediatric cataracts, *Ophthalmology*, 1996;103:713-720.
- Vasavada A, Desai J, Primary posterior capsulorhexis with and without anterior vitrectomy in congenital cataracts, *J Cataract Refract Surg*, 1997;23(Suppl. 1):645-651.
- Plager DA, Lipsky SN, Snyder SK, Sprunger DT, Ellis FD, Sondhi N. Capsular management and refractive error in pediatric intraocular lenses. *Ophthalmology* 1997; 104:600-607.
- Luo Y, Lu Y, Lu G, Wang M, Primary posterior capsulorhexis with anterior vitrectomy in preventing posterior capsule opacification in pediatric cataract microsurgery, *Microsurgery*, 2008;28:113-116.
- Fenton S, O'Keefe M, Primary posterior capsulorhexis without anterior vitrectomy in pediatric cataract surgery: longer-term outcome, *J Cataract Refract Surg*, 1999;25:763-767.
- Kugelberg M, Zetterstrom C, Pediatric cataract surgery with or without anterior vitrectomy, *J Cataract Refract Surg*, 2002;28:1770-1773.
- BenEzra D, Cohen E, Posterior capsulectomy in pediatric cataract surgery: the necessity of a choice, *Ophthalmology*, 1997;104:2168-2174.
- Comer RM, Abdulla N, O'Keefe M, Radiofrequency diathermy capsulorhexis of the anterior and posterior capsules in pediatric cataract surgery: preliminary results, *J Cataract Refract Surg*, 1997;23(Suppl. 1):641-644.
- Alexandrakis G, Peterseim MM, Wilson ME, Clinical outcomes of pars plana capsulotomy with anterior vitrectomy in pediatric cataract surgery, *J AAPOS*, 2002;6:163-167.
- Ahmadi H, Javadi MA, Ahmady M, et al., Primary capsulectomy, anterior vitrectomy, lensectomy, and posterior chamber lens implantation in children: limbal versus pars plana, *J Cataract Refract Surg*, 1999;25:768-775.
- Praveen MR, Vasavada AR, Koul A, et al., Subtle signs of anterior vitreous face disturbance during posterior capsulorhexis in pediatric cataract surgery, *J Cataract Refract Surg*, 2008;34:163-167.
- Peyman GA, Cheema R, Conway MD, Fang T, Triamcinolone acetonide as an aid to visualization of the vitreous and the posterior hyaloid during pars plana vitrectomy, *Retina*, 2000;20:554-555.
- Shah SK, Vasavada V, Praveen MR, et al., Triamcinolone-assisted vitrectomy in pediatric cataract surgery, *J Cataract Refract Surg*, 2009;35:230-232.
- Dahan E, Salmenson BD, Pseudophakia in children: precautions, technique, and feasibility, *J Cataract Refract Surg*, 1990;16:75-82.
- Gimbel HV, Ferensowicz M, Raanan M, DeLuca M, Implantation in children, *J Pediatr Ophthalmol Strabismus*, 1993;30:69-79.
- Oliver M, Milstein A, Pollack A, Posterior chamber lens implantation in infants and juveniles, *Eur J Implant Refract Surg*, 1990;2:309-314.
- Vasavada A, Chauhan H, Intraocular lens implantation in infants with congenital cataracts, *J Cataract Refract Surg*, 1994;20:592-598.
- O'Keefe M, Fenton S, Lanigan B, Visual outcomes and complications of posterior chamber intraocular lens implantation in the first year of life, *J Cataract Refract Surg*, 2001;27:2006-2011.
- Hosal BM, Biglan AW, Risk factors for secondary membrane formation after removal of pediatric cataract, *J Cataract Refract Surg*, 2002;28:302-309.
- Jensen AA, Basti S, Greenwald MJ, Mets MB, When may the posterior capsule be preserved in pediatric intraocular lens surgery?, *Ophthalmology*, 2002;109:324-327; discussion: 328.
- Stager DR Jr, Weakley DR Jr, Hunter JS, Long-term rates of PCO following small incision foldable acrylic intraocular lens implantation in children, *J Pediatr Ophthalmol Strabismus*, 2002;39:73-76.
- Astle WF, Alewenah O, Ingram AD, Paszuk A, Surgical outcomes of primary foldable intraocular lens implantation in children: understanding posterior opacification and the absence of glaucoma, *J Cataract Refract Surg*, 2009;35:1216-1222.
- Ram J, Brar GS, Kaushik S, et al., Role of posterior capsulotomy with vitrectomy and intraocular lens design and material in reducing posterior capsule opacification after pediatric cataract surgery, *J Cataract Refract Surg*, 2003;29:1579-1584.
- Raina UK, Mehta DK, Monga S, Arora R, Functional outcomes of acrylic intraocular lenses in pediatric cataract surgery, *J Cataract Refract Surg*, 2004;30:1082-1091.
- Vasavada AR, Trivedi RH, Nath VC, Visual axis opacification after AcrySof intraocular lens implantation in children, *J Cataract Refract Surg*, 2004;30:1073-1081, erratum: 1826.
- Aasuri MK, Fernandes M, Pathan PP, Comparison of acrylic and polymethyl methacrylate lenses in a pediatric population, *Indian J Ophthalmol*, 2006;54:105-109.
- Nihalani BR, Vasavada AR, Single-piece AcrySof intraocular lens implantation in children with congenital and developmental cataract, *J Cataract Refract Surg*, 2006;32:1527-1534.
- Trivedi RH, Wilson ME Jr, Single-piece acrylic intraocular lens implantation in children, *J Cataract Refract Surg*, 2003;29:1738-1743.
- Gimbel HV, DeBroff BM, Posterior capsulorhexis with optic capture: maintaining a clear visual axis after pediatric cataract surgery, *J Cataract Refract Surg*, 1994;20:658-664.
- Gimbel HV, DeBroff BM, Intraocular lens optic capture, *J Cataract Refract Surg*, 2004;30:200-206.
- Gimbel HV, Posterior continuous curvilinear capsulorhexis and optic capture of the intraocular lens to prevent secondary opacification in pediatric cataract surgery, *J Cataract Refract Surg*, 1997;23(Suppl. 1):652-656.
- Vasavada AR, Trivedi RH, Role of optic capture in congenital cataract and intraocular lens surgery in children, *J Cataract Refract Surg*, 2000;26:824-831.
- Vasavada AR, Trivedi RH, Singh R, Necessity of vitrectomy when optic capture is performed in children older than 5 years, *J Cataract Refract Surg*, 2001;27:1185-1193.
- Argento C, Badoza D, Ugrin C, Optic capture of the AcrySof intraocular lens in pediatric cataract surgery, *J Cataract Refract Surg*, 2001;27:1638-1642.
- Dada T, Dada VK, Sharma N, Vajpayee RB, Primary posterior capsulorhexis with optic capture and intracameral heparin in paediatric cataract surgery, *Clin Experiment Ophthalmol*, 2000;28:361-363.
- Enapace R, Posterior capsulorhexis combined with optic buttonholing: an alternative to standard in-the-bag implantation of sharp-edged intraocular lenses? A critical analysis of 1000 consecutive cases, *Graefes Arch Clin Exp Ophthalmol*, 2008;246:787-801.
- Grieshaber MC, Pienaar A, Stegmann R, Posterior vertical capsulotomy with optic entrapment of the intraocular lens in congenital cataracts - prevention of capsule opacification, *J Cataract Refract Surg*, 2005;31:886-894.
- Maloof A, Neilson G, Milverton EJ, Pandey SK, Selective and specific targeting of lens epithelial cells during cataract surgery using sealed-capsule irrigation, *J Cataract Refract Surg*, 2003;29:1566-1568.
- Agarwal A, Agarwal S, Agarwal A, Maloof A, Sealed-capsule irrigation device, *J Cataract Refract Surg*, 2003;29:2274-2276.
- Crowston JG, Healey PR, Hopley C, et al., Water-mediated lysis of lens epithelial cells attached to lens capsule, *J Cataract Refract Surg*, 2004;30:1102-1106.
- Abdelwahab MT, Kugelberg M, Kugelberg U, Zetterstrom C, After-cataract evaluation after using balanced salt solution distilled deionized water and 5-fluorouracil with a sealed-capsule irrigation device in the eyes of 4-week-old rabbits, *J Cataract Refract Surg*, 2006;32:1955-1960.
- Vasavada AR, Shah SK, Praveen MR, et al., Pars plicata posterior continuous curvilinear capsulorhexis, *J Cataract Refract Surg*, 2011;37:221-223.
- Tassignon MJ, De Groot V, Vrensen GF, Bag-in-the-lens implantation of intraocular lenses, *J Cataract Refract Surg*, 2002;28:1182-1188.
- Tassignon MJ, De Veuster I, Godts D, et al., Bag-in-the-lens intraocular lens implantation in the pediatric eye, *J Cataract Refract Surg*, 2007; 33:611-617.
- Moreno-Montañés J, Barrio-Barrio J, García-Layana A, Combined cataract surgery and 25-gauge sutureless vitrectomy for posterior lentiglobus, *J Cataract Refract Surg*, 2007;33:380-382.
- Chee KY, Lam GC, Management of congenital cataract in children younger than 1 year using a 25-gauge vitrectomy system, *J Cataract Refract Surg*, 2009;35:720-724.
- Rumelt S, Stolovich C, Segal ZI, Rehany U, Intraoperative enoxaparin minimizes inflammatory reaction after pediatric cataract surgery, *Am J Ophthalmol*, 2006;141:433-437.