

Effective Surgical Management of Ectatic Corneal Dystrophies

Vishal Jhanji and Rasik B Vajpayee

Centre for Eye Research Australia, University of Melbourne, Royal Victorian Eye and Ear Hospital

Abstract

The management options for ectatic disorders of the cornea range from contact lenses to corneal transplantation. Although contact lenses and spectacles are effective in the early stages, advanced corneal ectasias require surgical measures including partial- and full-thickness keratoplasty. In recent years, a variety of novel treatment modalities have emerged, which include collagen cross-linking, intra-stromal implants and the use of femtosecond lasers for performing keratoplasties. This article outlines a few important surgical approaches that can be used for the management of ectatic corneal disorders.

Keywords

Corneal ectasia, keratoconus, keratoplasty, deep lamellar keratoplasty, automated lamellar therapeutic keratectomy, 'tuck-in' lamellar keratoplasty, Intacs

Disclosure: The authors have no conflicts of interest to declare.

Received: 22 December 2009 **Accepted:** 15 April 2010 **Citation:** *European Ophthalmic Review*, 2010;4:65–9 DOI: 10.17925/EOR.2010.04.01.65

Correspondence: Rasik B Vajpayee, Centre for Eye Research Australia, University of Melbourne, 32 Gisborne Street, East Melbourne, Victoria 3002, Australia.
E: rasikv@unimelb.edu.au

Corneal ectasias represent a group of disorders characterised by tectonic corneal weakness or thinning, decreased visual acuity and irregular astigmatism.¹ These disorders comprise primary conditions such as keratoconus and pellucid marginal degeneration and iatrogenic corneal ectasia, which may occur after refractive procedures such as laser *in situ* keratomileusis (LASIK) surgery.

In recent years, a variety of treatment modalities have emerged, which include novel collagen cross-linking, intra-stromal implants and recent techniques in central and peripheral lamellar keratoplasty. This article reviews important surgical approaches to the management of ectatic corneal diseases.

Deep Lamellar Keratoplasty

Penetrating keratoplasty (PKP) for corneal disease has enjoyed a relatively high success rate compared with transplantation of other tissues. However, endothelial graft rejection is observed in approximately 20% of low-risk cases undergoing PKP.² Over time, a variable number of keratoconus patients experience one or more endothelial rejection episodes causing graft decompensation. Deep lamellar keratoplasty (DLK) is a surgical technique that can eliminate the risk of corneal endothelial graft rejection, with comparable optical results to PKP. DLK has been successfully used to treat various corneal pathologies that spare the corneal endothelium.^{3,4}

The concept of a 'true' deep anterior lamellar keratoplasty (DALK) extending down to Descemet's membrane (DM) is relatively new, and older literature does not expand on the actual depth of 'deep' lamellar keratoplasty. Gasset reported a series of keratoconus patients in the late 1970s who underwent 'conectomy' and received

full-thickness grafts stripped of DM transplanted into relatively deep lamellar beds. Another technique introduced as 'full-thickness lamellar keratoplasty' involved placing a full-thickness graft, including DM and endothelium, into a deep lamellar bed. Histopathology of this technique showed that the presence of donor DM delayed wound healing in the donor DM–host stromal interface. This provided a rationale for stripping donor DM in subsequent DALK techniques.

Dissection of host tissue 'close to' the DM and the term 'deep lamellar keratoplasty' was first introduced by Archilla in 1984, who demonstrated the use of intra-stromal air injection to facilitate the removal of diseased host corneal tissue. The first study of the results of DLK compared with PKP in keratoconus was reported by Sugita and Kondo in 1997.⁵ They showed that post-operative visual acuity was similar after DLK and PKP in cases of keratoconus. Recently, DALK has gained credit due to improvements in surgical techniques and the availability of new surgical instruments and visco-elastics that have helped to improve surgical success and reduce surgery time.

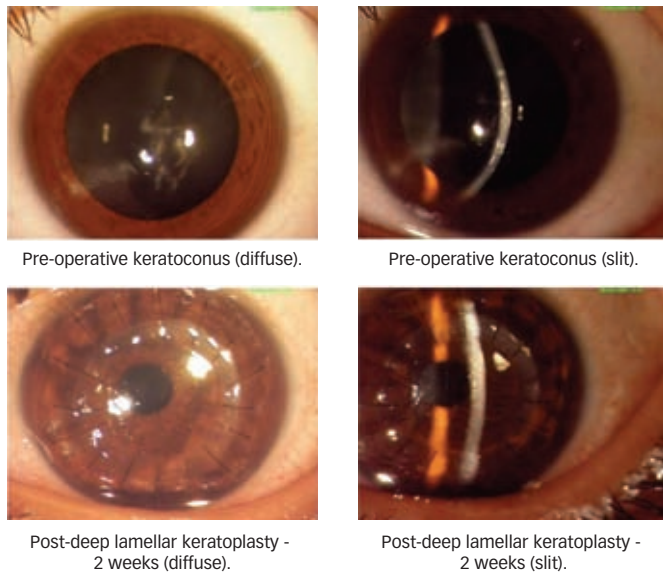
Deep Lamellar Keratoplasty Techniques

The classic technique for DLK involves the removal of host tissue layer by layer until the deep stroma or the DM is bared. While stromal fibres are difficult to visualise when the amount of tissue becomes minimal, injection of irrigation fluid causes swelling of stromal fibres, which can then be manipulated. The two techniques that have become popular in recent times are the Melles and 'big bubble' techniques.

Melles Technique

Melles et al.⁶ have described air injection for facilitating the dissection of corneal stroma. The surgical technique involves injection of air into

Figure 1: Deep Lamellar Keratoplasty for Keratoconus



the anterior chamber; this creates a mirror reflex to guide surgical instruments directly into the space between DM and the posterior stroma. The difference in the refractive index between air and corneal tissue creates a reflex of the surgical knife, and the distance between the instrument and reflex can be used to judge the amount of stromal tissue. The blunt end of a microsurgery knife is used to dissect the stroma down to the DM, using the reflection of the knife observed at the air-to-endothelium interface as a guide. A blunt spatula is inserted into the loose space between the DM and the stromal fibres to create a pocket. After creation of a small DM detachment with balanced salt solution (BSS), visco-dissection is performed to further extend DM detachment. After complete dissection of DM, the overlying stroma is removed to expose the smooth surface of DM.

Modifications to the Melles Technique

Shimmura et al.⁹ have slightly modified the Melles technique by performing anterior lamellar keratectomy prior to air injection. Senoo et al.¹⁰ have used a sclero-limbal approach for performing DLK. The method uses trabeculectomy to detach DM. A flap is made, as in trabeculectomy, and the region directly above DM is reached under direct vision. DM is detached by hydro-delamination and visco-elastic material is used to maintain the supra DM space. Parmar et al.¹¹ used a 5mm-long scleral incision for corneal dissection close to the level of the DM. Using this technique, a scleral pocket incision is created with a crescent knife and dissection is carried into the clear cornea. Visco-elastic is injected into the scleral pocket for facilitating the separation of DM from the corneal stroma.

Funnell et al.⁷ compared the outcomes and complications of deep lamellar keratoplasty using the Melles technique and penetrating keratoplasty (PK) for keratoconus. There was no significant difference in the proportion of patients achieving 6/9 or better between the PK and DLK groups. The study found that DLK causes less astigmatism and also has the advantage of no endothelial graft rejection. In another study, Watson et al.⁸ compared the DLK and PK using Melles technique in patients with keratoconus. They found that best corrected visual acuity, refractive results and complication rates were similar in both groups.

Big Bubble Technique

Archilla introduced the technique of air injection between the DM and the overlying corneal stroma. In this technique a 26-gauge needle connected to a tuberculin syringe filled with air is inserted obliquely into the stroma up to the corneal mid-periphery. Air is injected and corneal stromal trephination is performed. Dissection is facilitated with a spatula to separate the DM from the deeper stromal layers.¹²

Anwar et al.¹³ modified Archilla’s technique by performing corneal trephination before air injection. About 60–80% of the corneal stroma is trephined with the help of a suction trephine. A 27-gauge needle is attached to an air-filled syringe and the needle is bent at about 60° angulation 5mm from its tip. The plunger of the air-filled syringe is depressed until one of the ‘big bubbles’ is achieved. The injected air forms an almost circular bubble between the DM and the deepest stroma. A partial thickness keratectomy is performed with the help of a Beaver blade leaving a layer of corneal stroma in place. Using a sharp-tipped blade held tangentially to the cornea, a small nick is made in the corneal stroma. Dissection can be carried out in this plane with the help of a spatula and long scissors.

The donor lenticule is prepared using a standard technique. Since DLK does not involve replacement of DM or endothelium, the donor quality criteria are not stringent. DM and endothelium are stripped off from the donor button, which is then sutured over the host bed using 10-0 monofilament nylon sutures. The disparity between host cut and donor button is usually between 0.25 and 0.5mm, the diameter of the graft button being larger.¹⁶ Some corneal surgeons prefer to use a ‘same size’ or an undersized donor button in patients with keratoconus (see *Figure 1*).⁴

Al-Torbak et al.¹⁶ performed DALK in 127 eyes with keratoconus. At the last follow-up, 74% of all eyes achieved a best corrected visual acuity of 20/50 or better. Intra-operative perforation of DM occurred in 13% of cases. The main complications included graft-host vascularisation, stromal graft rejection, graft infection and persistent epithelial defect. In another study, Fontana et al.,¹⁷ evaluated big bubble DALK in 78 eyes with keratoconus. Big bubble was achieved in 64% of cases. Intra-operative micro-perforations occurred in 15% of cases. Mean uncorrected visual acuity improved from 20/500 to 20/60 at the end of two years. Michieletto et al.¹⁸ evaluated deep lamellar keratoplasty in 10 eyes of 10 patients who underwent DALK using the big bubble technique. The authors concluded that there may be a high risk of perforation of the Descemet’s membrane when pre-operative total pachymetry is below the limit of 250 microns.

Modifications to the Big Bubble Using Air Injection

Fournie et al.¹⁴ have described a modification of Anwar’s big bubble technique. The initial air injection is made in the superficial corneal stroma. The aim of the first air injection is to induce corneal emphysema and facilitate superficial lamellar keratectomy. Subsequent dissection is carried out with the help of visco-elastic. Recently, Parathasarathy et al.¹⁵ reported a method of using a small air bubble in the anterior chamber to help determine whether a successful big bubble has been achieved. The small bubble helps the surgeon to assess the extent of the big bubble in cases where the cornea is opaque or when air diffusion into the peripheral cornea prevents direct visualisation into the anterior chamber. The major complication encountered during DLK is intra-operative perforation of the DM. The incidence of Descemet’s membrane perforation during

DALK depends on the surgical technique and the expertise of the surgeon. Reported incidences vary in different studies.^{16,18,19} Keratoconus patients are more prone to Descemet's membrane ruptures than patients with other diseases, due to either thinner corneas or an intrinsic property of the disease.

DM perforation can be in the form of a micro- or a macro-perforation. Micro-perforations in the peripheral cornea can be managed by careful stromal dissection and air injection at the end of the surgery. If a micro-perforation occurs in the central cornea, there is a risk of perforation of the double anterior chamber in the post-operative period. Injection of a mixture of SF6 with air, or a mixture of C3F8 with air into the anterior chamber can also be used for temporarily sealing micro-perforations, or for flattening the secondary anterior chamber that tends to form after perforation.²¹

Conversion to a PKP may be required in some cases. In such a scenario, a complete dissection of the host cornea should be carried out. Trypan blue dye (0.01%) may be used to delineate any retained pieces of DM as well as to facilitate dissection of the trephined host cornea.²²

A rather rare complication after DLK is corneal stromal graft rejection, which is characterised by sudden-onset decreased vision and subepithelial infiltrates, with or without stromal oedema or anterior segment activity.²³ These cases are treated with prednisolone acetate one per cent drops, gradually tapered over four to six weeks.

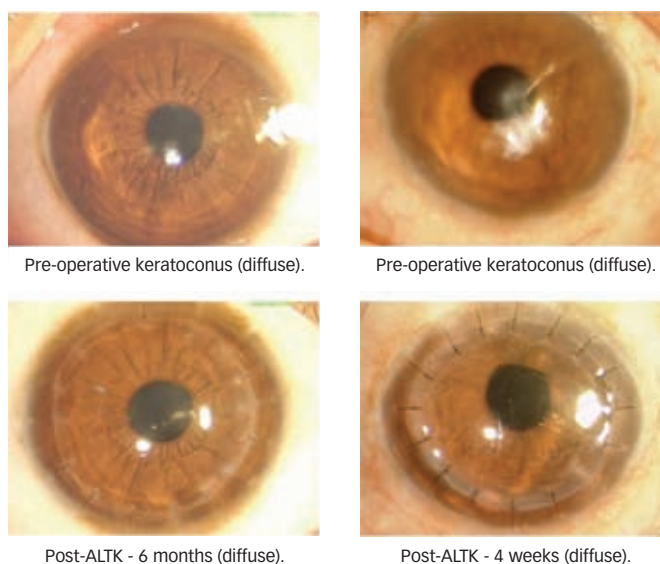
Automated Lamellar Therapeutic Keratectomy

Microkeratome-assisted lamellar keratoplasty is another novel technique used for surgical treatment of keratoconus and other corneal pathologies sparing the endothelium.^{24,25} The major advantage of automated lamellar therapeutic keratoplasty (ALTK) is that the donor cut is smooth, which eliminates the risk of interface haze that can otherwise result in poor visual quality. Also, the dissection is easy to perform and shortens surgical time considerably. The surgical technique offers more control in the depth of dissections and can be fairly standardised. The surgery does not require dissection up to the level of DM, therefore reducing the chances of perforation of DM.

ALTK was primarily developed to treat cases of keratoconic corneas with a minimum corneal thickness of 380 μ .²⁵ A 250 μ anterior corneal disc of the host is excised by a micro-keratome and a 350 μ -thick donor corneal disc is transplanted. The donor lenticule is also harvested using a micro-keratome and an artificial anterior chamber. The desired diameter of the donor lenticule is achieved by using different suction rings. Ring 0 is used for corneas with an average simulated keratometric reading up to 55D, and ring 1 is used for corneas with an average simulated keratometric reading above 55D (see *Figure 2*).

Busin et al.²⁵ evaluated the visual and refractive results of ALTK in patients with keratoconus with a minimal corneal thickness of 380 microns. All patients underwent a standard ALTK surgical procedure. At the end of one year, best spectacle-corrected visual acuity $\geq 20/40$ and refractive astigmatism $\leq 4D$ was achieved in the majority of patients. The major complications reported in this study included irregular astigmatism (22%), high-degree astigmatism requiring secondary intervention (12%), epithelial interface ingrowth (2%) and cataract formation (2%).

Figure 2: Automated Lamellar Therapeutic Keratectomy for Keratoconus



ALTK = automated lamellar therapeutic keratoplasty.

'Tuck-in' Lamellar Keratoplasty

'Tuck-in' lamellar keratoplasty (TILK) is a special technique of partial-thickness corneal transplantation that has been described for cases of advanced peripheral corneal-thinning disorders like keratoglobus, pellucid marginal degeneration (PMD) or cases with a combination of keratoconus and PMD.^{26,27}

Surgical Technique

The surgery involves the creation of a partial-thickness groove of 180–240 μ m on the host cornea using a Hessburg Barron vacuum trephine and the excision of a central anterior stromal disc. Subsequently, a peripheral intra-stromal pocket is created circumferentially in the corneal periphery up to a point 0.5mm further away from the limbus. The donor preparation involves fixing a corneo-scleral donor button in an artificial chamber. An initial partial-thickness incision is made up to a depth of 300 μ m and superficial corneal tissue is excised, leaving a central full-thickness graft with a peripheral partial-thickness flange of about 2.5–3mm. The tissue is punched from the endothelial side with hand-held trephines. The DM of the donor lenticule is stripped after staining with 0.1ml of 0.06% Trypan Blue. The flange of the donor lenticule is tucked into the peripheral intra-stromal pocket of the host created previously, and sutured with 16 10-0 monofilament sutures. In the presence of inferior thinning, in cases of PMD with keratoconus only, an inferior 180° peripheral intra-stromal pocket is created instead of a circumferential pocket.

The central full-thickness graft provides tectonic support to the central cornea while the thin peripheral flange tucked into the intra-stromal pocket integrates into the host and provides tectonic support to the peripheral cornea. Moreover, there is no damage to the recipient's limbal stem cells as dissection of the limbal region is avoided, which subsequently promotes healing of epithelium at the graft–host junction.

We performed TILK in 12 eyes of 12 patients with combined keratoconus and PMD, and keratoglobus.²⁷ The best corrected visual

Figure 3: 'Tuck-in' Lamellar Keratoplasty for Keratoglobus

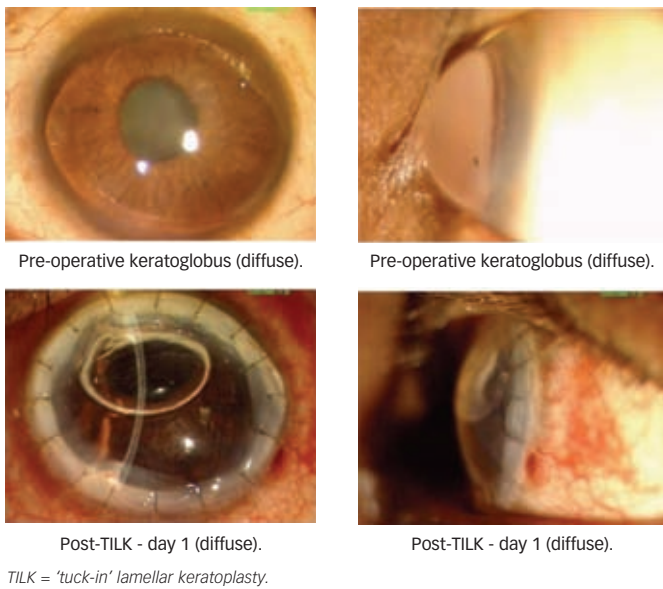



Figure 4: Intacs for Keratoconus



acuity improved from 20/120 pre-operatively to $\geq 20/80$ at the last follow-up. There was a significant decrease in average keratometry, refractive astigmatism and spherical equivalent. There was no significant corneal interface haze or corneal vascularisation seen in any of the eyes (see Figure 3).

Intacs

Intacs are polymethylmethacrylate segments designed to be surgically inserted into the deep corneal stroma to flatten the central cornea. An important advantage of using Intacs is that the prolate shape of the cornea is preserved over the central optical zone, unlike laser and incisional procedures, which play a role in the maintenance of contrast sensitivity and improved visual acuity outcomes. Intacs were initially approved by the US Food and Drug Administration (FDA) in 1999 for correction of myopia from -1.00 to -3.00D, with 1.00D or less of astigmatism. However, with the advent of the excimer laser at about the same time, Intacs were not popular for refractive correction. Intacs have now been approved for use in patients with mild to moderate keratoconus who have a clear visual axis, an upper limit of keratometry readings in the range of 55–57D

and a minimum corneal thickness of 450 μ . Intacs come in many different sizes and there are potentially many different combinations that can be used to achieve both flattening of the central cornea and reduce the astigmatism. In pure nipple cones it is best to use two symmetrical Intacs. If the patient is not severely myopic, smaller symmetrical Intacs could be used so as not to overcorrect and induce hyperopia.

The surgical procedure involves the creation of corneal tunnels at about 70% corneal depth using two Sinsky hooks and a mechanical spreader. Intacs segments are implanted in the respective corneal tunnels, maintaining a space of approximately 2.0mm between their ends. The incision site is sutured using a single 10-0 nylon stitch (see Figure 4).²⁸ Recently, femtosecond laser has been used to create channels. Besides being quick, femtosecond results in a high degree of certainty of the depth of placement of rings.

The technique may be associated with the occurrence of small epithelial defects that are evident on the first post-operative day. Deposits surrounding the ring segments are occasionally seen and may increase over time, but are not associated with effects on visual acuity. Infection most commonly occurs as a result of a loose stitch or as a result of wound gape from migration of the Intacs to the site of the wound.

Results

In 2001, Colin et al. published the first series of 10 patients with one-year follow-up. Intacs inserts of 0.45mm thickness were placed in the inferior cornea and 0.25mm inserted superiorly. At post-operative month 12, uncorrected visual acuity was significantly better than pre-operative values.²⁹

In 2003, Boxer Wachler reported the results of 74 eyes of patients with keratoconus using asymmetrical Intacs. The study concluded that asymmetrical Intacs implantation can improve both uncorrected and best spectacle-corrected visual acuity and can reduce irregular astigmatism.³⁰

In 2005, Alio et al. performed a prospective study to evaluate the effect of implanting one versus two intra-corneal rings in patients with keratoconus. A single Intac was placed inferiorly in cases where the topographic pattern did not cross the 180° meridian. Two Intacs were placed in cases where the topographic pattern crossed the 180° meridian. At one year, the mean uncorrected visual acuity improved from 20/100 to 20/32 in the first group and from 20/400 to 20/63 in the second group.³¹

In 2005, Rabinowitz et al. compared the results of a femtosecond laser with the mechanical spreader for inserting Intacs in patients with keratoconus. Both groups showed a significant reduction in average keratometry, spherical equivalent, best corrected visual acuity, uncorrected visual acuity, surface regularity index (SRI) and surface asymmetry index (SAI). The laser group performed better in all parameters except for a change in SRI.³² ■

1. Tan DT, Por YM, Current treatment options for corneal ectasia, *Curr Opin Ophthalmol*, 2007;18(4):284–9.
2. Kirkness CM, Ficker LA, Steele AD, Rice NSC, The success of penetrating keratoplasty for keratoconus, *Eye*, 1990;4:673–88.
3. Vajpayee RB, Tyagi J, Sharma N, et al., Deep anterior lamellar keratoplasty by big-bubble technique for treatment corneal stromal opacities, *Am J Ophthalmol*, 2007;143(6):954–7.
4. Noble BA, Agrawal A, Collins C, et al., Deep Anterior Lamellar Keratoplasty (DALK): visual outcome and complications for a heterogeneous group of corneal pathologies, *Cornea*, 2007;26(1):59–64.
5. Sugita J, Kondo J, Deep lamellar keratoplasty with complete removal of pathological stroma for vision

- improvement, *Br J Ophthalmol*, 1997;81:184–8.
6. Melles GRJ, Lander F, Rietveld FJR, et al., A new surgical technique for deep stromal, anterior lamellar keratoplasty, *Br J Ophthalmol*, 1999;83:327–33.
 7. Funnell CL, Ball J, Noble BA, Comparative cohort study of the outcomes of deep lamellar keratoplasty and penetrating keratoplasty for keratoconus, *Eye*, 2006;20(5):527–32
 8. Watson SL, Ramsay A, Dart JK, et al., Comparison of deep lamellar keratoplasty and penetrating keratoplasty in patients with keratoconus, *Ophthalmology*, 2004;111(9):1676–82.
 9. Shimmura S, Shimazaki J, Omoto M, et al., Deep lamellar keratoplasty (DLKP) in keratoconus patients using viscoadaptive viscoelastics, *Cornea*, 2005;24(2):178–81.
 10. Senoo T, Chiba K, Terada O, et al., Deep lamellar keratoplasty by deep parenchyma detachment from the corneal limbs, *Br J Ophthalmol*, 2005;89(12):1597–1600.
 11. Parmar P, Salman A, Kalavathy CM, et al., Simplified technique for deep anterior lamellar keratoplasty, *Cornea*, 2007;26(6):707–8.
 12. Archilla EA, Deep lamellar keratoplasty dissection of host tissue with intrastromal air injection, *Cornea*, 1984–1985; 3(3):217–18.
 13. Anwar M, Teichmann KD, Big-bubble technique to bare Descemet's membrane in anterior lamellar keratoplasty, *J Cataract Refract Surg*, 2002;28(3):398–403.
 14. Fournie P, Malecaze F, Couillet J, Arne JL, Variant of the big bubble technique in deep anterior lamellar keratoplasty, *J Cataract Refract Surg*, 2007;33:371–5.
 15. Parthasarathy A, Por YM, Tan DT, Use of a "small-bubble technique" to increase the success of Anwar's "big-bubble technique" for deep lamellar keratoplasty with complete baring of Descemet's membrane, *Br J Ophthalmol*, 2007;91(10):1369–73.
 16. Al-Torbak AA, Al-Motowa S, Al-Assiri A, et al., Deep anterior lamellar keratoplasty for keratoconus, *Cornea*, 2006;25(4):408–12.
 17. Fontana L, Parente G, Tassinari G, Clinical outcomes after deep anterior lamellar keratoplasty using the big-bubble technique in patients with keratoconus, *Am J Ophthalmol*, 2007;143(1):117–24.
 18. Michieletto P, Balestrazzi A, Balestrazzi A, et al., Factors predicting unsuccessful big bubble deep lamellar anterior keratoplasty, *Ophthalmologica*, 2006;220(6):379–82.
 19. Pakrou N, Fung S, Selva D, et al., Deep lamellar keratoplasty in the treatment of keratoconus, *Ophthalmologica*, 2006;220:164–9.
 20. Leccisotti A, Descemet's membrane perforation during deep anterior lamellar keratoplasty: prognosis, *J Cataract Refract Surg*, 2007;33(5):825–9.
 21. Den S, Shimmura S, Tsubota K, Shimazaki J, Impact of the descemet membrane perforation on surgical outcomes after deep lamellar keratoplasty, *Am J Ophthalmol*, 2007;143(5):750–54.
 22. Sharma N, Jhanji V, Titiyal JS, et al., Use of Trypan Blue Dye for identification of remnants of host corneal tissue during conversion of Deep Anterior Lamellar Keratoplasty to Penetrating Keratoplasty, *J Cataract Refract Surg*, 2008; 34(8):1242–5.
 23. Watson SL, Tuft SJ, Dart JK, Patterns of rejection after deep lamellar keratoplasty, *Ophthalmology*, 2006;113(4):556–60.
 24. Vajpayee RB, Vasudendra N, Titiyal JS, et al., Automated lamellar therapeutic keratoplasty (ALTK) in the treatment of anterior to mid-stromal corneal pathologies, *Acta Ophthalmol Scand*, 2006; 84(6):771–3.
 25. Busin M, Zambianchi L, Arffa RC, Microkeratome-Assisted Lamellar Keratoplasty for the Surgical Treatment of Keratoconus, *Ophthalmology*, 2005;112:987–97.
 26. Vajpayee RB, Bhartiya P, Sharma N, Central lamellar keratoplasty with peripheral intralamellar tuck: a new surgical technique for keratoglobus, *Cornea*, 2002;21(7):657–60.
 27. Kaushal S, Jhanji V, Sharma N, et al., Tuck In Lamellar Keratoplasty (TILK) for corneal ectasias involving corneal periphery, *Br J Ophthalmol*, 2008;92(2):286–90.
 28. Rabinowitz YS, INTACS for keratoconus, *Int Ophthalmol Clin*, 2006;46(3):91–103.
 29. Colin J, Cochener B, Savary G, et al., INTACS inserts for treating keratoconus: one-year results, *Ophthalmology*, 2001;108:1409–14.
 30. Boxer Wachler BS, Christie JP, Chandra NS, et al., Nepomuceno Intacs for keratoconus, *Ophthalmology*, 2003;110:1031–40.
 31. Alio JL, Artola A, Hassanein A, et al., One or 2 Intacs segments for the correction of keratoconus, *J Cataract Refract Surg*, 2005;31:943–53.
 32. Rabinowitz YS, Li X, Ignacio TS, Maguen E, INTACS inserts using the femtosecond laser compared to the mechanical spreader in the treatment of keratoconus, *J Refract Surg*, 2006;22(8):764–71.