

# Perforating Keratoplasties with Non-circular Shapes and Intrastromal Refractive Correction of Presbyopia with the Femtec® Femtosecond Laser

a report by  
**Mark Tomalla**

Senior Physician, Clinic for Refractive and Ophthalmic Surgery, Clinic Niederrhein, Duisburg

DOI: 10.17925/EOR.2009.02.01.45

This article will concentrate on the performance of perforating keratoplasties (pKPL) using the Femtec® femtosecond laser (fs-laser) (20/10 Perfect Vision AG, Heidelberg, Germany) and on the non-circular decagonal transplant form, which we now use routinely in pKPL. At the end of this report, we will discuss our preliminary experience and results with intrastromal presbyopia correction. In our clinic, we work with the latest generation of the Femtec fs-lasers. This laser system has a patented spherical patient interface; the design of the curvature means that only moderate suction energy is needed to connect the eye to the laser. The treatment itself is performed with minimum applanation, i.e. the natural curvature of the eye is maintained during the procedure, which is less traumatic for the endothelium; therefore, no vision blackouts occur during the surgery.

The fs-laser is an infrared laser that works with considerably less heat stress than other laser systems. Using this laser, we can intrastromally separate the corneal tissue with extremely high precision and without using a scalpel. It is recommended that the laser be used preferentially in transparent tissue to achieve the optimal effect, i.e. extremely precise cuts at any desired site on and in the cornea; however, we have also used the laser on scarred and cloudy tissue and achieved excellent results.

We wish to state that we use the fs-laser for several applications in our everyday clinic routine, for example for tunnel preparation prior to implantation of intracorneal ring segments in the treatment of progressive keratoconus, in astigmatic keratotomies (AK) cuts and in flap preparation in the laser-assisted *in situ* keratomileusis (LASIK) procedure. We now perform lamellar keratoplasties and pKPL exclusively with the fs-laser. We have also succeeded in performing endothelial transplantations (or posterior lamellar keratoplasties).

## Performing Perforating Keratoplasties with the Femtec Femtosecond Laser

We performed our first pKPL with the fs-laser in 2005 and attained promising post-operative results. To date, we have treated about 30 eyes with perforating keratoplasty, all with the Femtec fs-laser. We generally perform the surgery according to the following procedure.

We begin with the preparation of the donor cornea in the artificial anterior chamber. We make the first cut intrastromally at a depth of up to 1,500µm and draw it up towards the epithelium, sparing the epithelium, usually selecting 90° to the corneal curvature as the angle of incision. The diameter and angle of incision are identical for the donor and recipient cornea thanks to the extremely high precision of the laser. The recipient cornea is prepared just as precisely; the mechanical pressure on the bulbus during the procedure is only about 35mmHg. Here, too, we begin the fs-laser incision at a depth of up to 1,500µm and conduct it up towards the epithelium. The recipient

cornea usually nestles spontaneously in the prepared donor cornea of the opened eye. The precise preparation of the transplant pays off. Then we start fixation with four situation sutures before we make the continuous suture.

During the surgery, trepanation with the fs-laser is always carried out intrastromally from the endothelium to the epithelium. The entire procedure is performed under visual control. The size of the transplant can be selected *ad lib* to a maximum of 9mm. Based on our surgical experience, we always select an identical diameter and an incision angle of exactly 90° for the preparation of the donor and recipient cornea. In this procedure, the eye remains a closed and thus stable system for as long as possible. The preparation is considerably quicker, safer and less traumatic than with the usual mechanical methods.

We have observed a safe and precise application of the fs-laser in pKPL even in completely clouded corneas or corneas with inhomogeneous tissue thickness. Our experience confirms the published reports on the safe and effective performance of pKPL with the Femtec fs-laser.<sup>1,2</sup> We can also confirm the performance of extremely precise cuts or incisions at any desired site on the cornea.<sup>3</sup>

## Our Patient Data Up to 24 Months After the Procedure

We have observed a stable anterior chamber and well-adapted, clear transplants without folds in all of the patients operated so far. There was a marked increase in visual acuity (VA) (see Table 1 and Figure 1), and wound healing was rapid. Below, we present the data of three patients as examples.

### Patient A

Patient A is now 80 years old. We examined her for the first time in 1999. She had undergone several surgeries on the right eye. In 1981, she received cerclage after a plombage operation and laser coagulation in the retinal foramen. In 1988, a cataract surgery with



Mark Tomalla is a Senior Physician at the Clinic for Refractive and Ophthalmic Surgery in Duisburg, a position he has held since 2005. He has also been a Specialist in Ophthalmology and Assistant Medical Director at the same institution since 1995. He is a member of the German Society of Ophthalmologists (DOG), the German Committee of Refractive Surgery (KRC), the Coalition for Refractive Implants (VRI), the American Society of Cataract and Refractive Surgery (ASCRS) and the European Society of Cataract and Refractive Surgery (ESCRS). His career highlights include performing the world's first Femtec laser-controlled penetrating keratoplasty and endothelial transplantation. Dr Tomalla undertook post-graduate training as a specialist examiner for the Medical Council Nordrhein and received his doctorate from the Heinrich-Heine University in Düsseldorf.

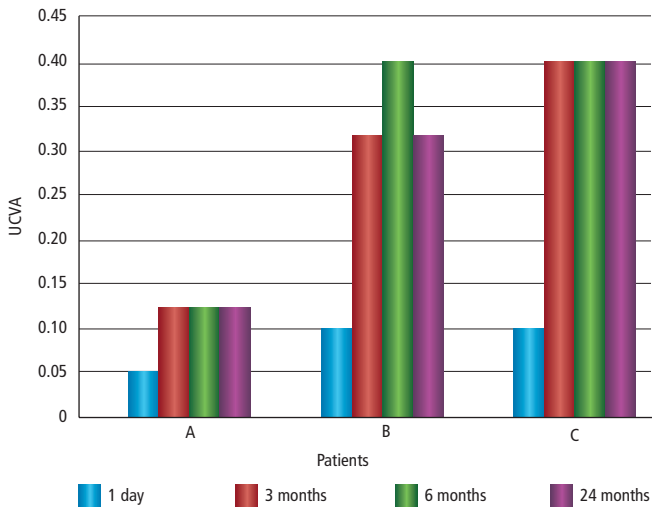
E: dr.mark.tomalla@web.de

Table 1: Perforating Keratoplasties with Femtosecond Laser – Post-operative Patient Data

	Patient A	Patient B	Patient C
Pre-operative UCVA	Hand movement, correct light projection	Hand movement, correct light projection	Hand movement, correct light projection
Post-operative UCVA			
First day	0.05	0.1	0.1
Three months	0.125	0.32	0.4
Six months	0.125	0.4	0.4
24 months	0.125	0.32	0.4
Post-operative diagnosis			
First day	Cornea well adapted, transplant clear and without folds	Transplant well integrated	Transplant well integrated
Three months			
Six months			
24 months	Stable state	Stable state	Stable state

UCVA = uncorrected visual acuity.

Figure 1: Perforating Keratoplasties with Femtosecond Laser – Post-operative Patient Data



UCVA = uncorrected visual acuity.

implantation of an anterior chamber lens was performed, and the cerclage was shifted after that. In 1999, the patient was already suffering from pronounced corneal decompensation after a vitrectomy with silicon oil filling. Her VA was limited to light perception and hand movements. After the first keratoplasty, her post-operative VA was 0.03. In 2003, an examination showed corneal decompensation with a dense scar to the limbus. VA was limited to hand movement. In July 2005, we decided on a re-transplantation, i.e. another pKPL, which we performed with the fs-laser.

Patient B

This 79-year-old woman suffered from Fuchs endothelial dystrophy. In 1992, she underwent a first corneal transplantation in the left eye. The cornea was totally cloudy and showed inhomogeneous tissue structure. When the patient came to us in July 2005, her VA was limited to hand movement. The patient also had a cataract.

Patient C

This 62-year-old woman suffered from bilateral keratoconus. Pre-operative VA in the left eye was limited to hand movement. There was a cataract and completely cloudy cornea with central and lower peripheral corneal scars.

Post-operative results

One day after pKPL with the fs-laser, patient A had VA of 0.05. The cornea was well adapted immediately after the procedure. Her VA was 0.125 after both three months and 24 months. The transplant was clear and without folds. Patients B and C had VA of 0.1 one day after the operation. The transplants were smoothly integrated into the remaining recipient corneas. There were discrete Descemet folds, but these disappeared three months after the operation. A marked and stable increase in VA could be observed in both patients (see Table 1 and Figure 1).

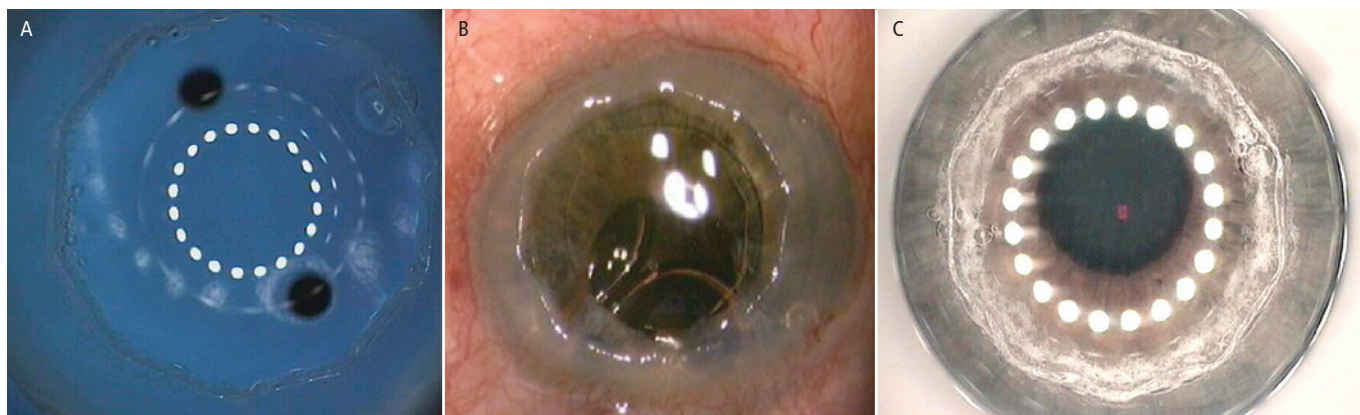
Overall, we can state that a rapid and marked improvement in VA was found in the 30 patients in whom we have performed pKPL with the fs-laser. The transplants were well-integrated and the anterior chamber stable. Thanks to excellent wound healing, we were able to remove the sutures six months after the procedure. No problems have occurred to date in the endothelial or epithelial areas. Markedly improved vision, e.g. uncorrected visual acuity (UCVA) up to 0.4, can be observed up to 24 months after the procedure. The transplants also remained well-adapted over the long term in all patients.

The Use of Non-circular Decagonal Transplant Forms

We have now applied a new decagonal, non-circular transplant form in some patients (see Figure 2). Using the Femtec fs-laser, we have long operated with ‘cuts’ of almost any size and form. Therefore, it was logical to pursue the development of an optimal transplant form. In co-operation with Dr Sugita of Japan, 20/10 Perfect Vision has developed special software that enables surgeons to prepare a non-circular, e.g. decagonal, transplant form in pKPL. We have now used this non-circular transplant form in the first patients. The noteworthy advantages of a decagonal transplant form are that the donor cornea can be positioned precisely, simply and easily, there is no rotation or decentration during suturing – that is we do not need fixation sutures – and double suturing is no longer necessary. Only a simple, continuous suture is needed.

Our short-term post-operative patient data (up to three months post-operation) confirm good VA, stable refraction, less astigmatism (stable at mean two diopters) and rapid wound healing. Discrete Descemet folds occurred immediately post-operation, but disappeared after two weeks. Recent publications on the topic of alternative or optimised transplant forms in the performance of pKPL with the fs-laser report a number of transplant forms. Most of the publications concern the top hat form, which was found to be biomechanically more stable than the traditional round, mushroom, zigzag or Christmas tree form.<sup>4,5</sup>

**Figure 2: Non-circular Decagonal Transplant Forms**



A: donor cornea after preparation with the femtosecond laser; B: Open host cornea after preparation with the femtosecond laser; C: Cornea after surgery.

Price and Price reported one-year post-operative results of pKPL performed with the fs-laser using the top hat form. They see an advantage in that the "...top hat configuration allowed for an increased area of wound healing..."<sup>6</sup> Farid et al. report similarly good results using the zigzag form. This form is also supposed to be biomechanically stable with good wound healing and good refractive results.<sup>7</sup> Steinert et al., who also prepared a top hat form in pKPL with the fs-laser, were correct in noting that the initial induced astigmatism is most influenced by the suture.<sup>8</sup> We believe that the suture and the form of the transplant influence possible rotation. In our opinion, the possibility of rotation is much greater with the zigzag form and the traditional round form than with a decagonal, non-circular form.

In the decagonal transplant form, the 10 'corners' are distributed evenly over the entire transplant form, which is then optimally protected against rotations. The decagonal transplant can be stably sutured without rotations. In the zigzag form, small peaks are created. Theoretically, there can be too many peaks: the greater the number of peaks, the rounder the transplant and the more susceptible it is to rotations. After surgery, we check the wound for leakage in all transplant forms – for this, the eye is filled with balanced salt solution (BSS) and tonicised, then checked for leakage with a swab. If a fistula effect is observed, a single-point suture may be made.

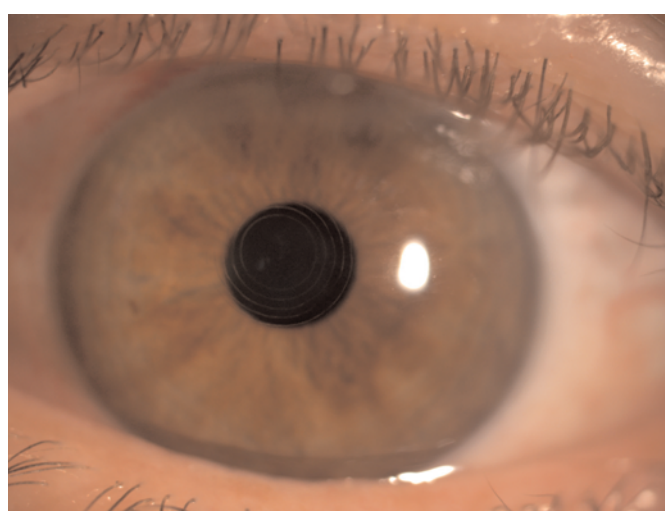### Conclusions

In our opinion, the application of non-circular transplant forms such as the decagonal form is a promising approach that combines the compactness and strength of an almost cylindrical shape with the stability given by the angles of the polygonal design.

Using the fs-laser in pKPL, the surgeon has the possibility of selecting the diameter of the transplant and the angle of incision *ad lib*. Visual control is maintained throughout the surgery. Thanks to the high precision enabled by the laser, it is easy to prepare donor and recipient cornea with identical parameters. Each pKPL can also be adapted individually to the patient's needs. The 30 pKPLs we have performed to date and our patient data, which range up to 24 months post-operatively, show that the Femtec fs-laser is extremely safe, precise and effective for use in pKPL.

The new, improved surgical standard is also seen in the preparation of novel, non-circular transplant forms, such as the decagonal form. The decagonal

**Figure 3: Patient A One Day Post-operatively**



Clearly visible are the rings in the middle of the pupil.

transplant prevents rotation or decentration. Fixation sutures are not necessary and a single suture is all that is required. In our opinion, the use of non-circular transplant forms is an extremely promising approach.

### Non-invasive Intrastromal Correction of Presbyopia – Future Applications

At the moment, the Clinic for Refractive and Ophthalmosurgery in Duisburg is participating in a multicentre trial of intrastromal presbyopia correction in co-operation with Gerd Auffarth and Mike Holzer of the University Eye Clinic Heidelberg, who are directing the study. These data will be used as the basis for application for the CE mark. Dr Luis Antonio Ruiz from Bogota was the first person to successfully perform intrastromal presbyopia correction with the Femtec.

The advantages of non-invasive intrastromal refractive correction are obvious: the procedure has no impact at all on the endothelium or the corneal surface, has an extremely low risk of infection, is followed by a very rapid healing phase and leaves the structural integrity of the cornea intact to a very large degree.

The first study group of patients identified and enrolled in our study consisted of presbyopic patients with VA of +0.75D distance and 2–4D

Table 2: IntraCOR Procedure with Femtec – Case Reports

Patient	Pre-op. UCVA	4 Weeks Post-op. UCVA	UCVA Change	Pre-op. UCNVA SLOAN Chart	4 Weeks Post-op. UCNVA SLOAN Chart	UCNVA Change
C	0.6	1.0	0.4	0.32	0.5	0.18
E	0.7	1.0	0.3	0.12	0.4	0.28
J	0.5	0.6	0.1	0.16	0.5	0.34

Table 3: IntraCOR Procedure with Femtec – Mean Values (preliminary results)

Patients	Pre-op. UCVA	4 Weeks Post-op. UCVA	UCVA Change	Pre-op. UCNVA SLOAN Chart	4 Weeks Post-op. UCNVA SLOAN Chart	UCNVA Change
n=16	0.72	0.8	0.08	0.19	0.38	0.19

UCVA = uncorrected visual acuity; UCNVA = uncorrected near visual acuity.

near vision. In the meantime, in Duisburg we have treated 20 patients, as planned, with an intrastromal refractive correction, which we performed using the Femtec femtosecond laser. Prior to the treatment itself, it is important to mark the Purkinje reflex precisely, i.e. the optical axis must be depicted exactly on the macula. The vacuum ring must be placed according to this marking, whereby the marking represents the centre of the treatment. Due to the low vacuum volume, tilting of the interface should be avoided and the patient should remain still and not move during treatment.

In the IntraCOR procedures performed thus far in the first study group, we have found that all patients could read better without correction post-operatively compared with pre-operatively. In terms of near vision, we measured with log charts an increase of up to six lines in one patient. In distance vision, two patients lost one (Snellen) line due to clouding, which occurred immediately post-operatively. However, a

rehabilitation phase of more than three months must be expected with this treatment.

Our patients were between 48 and 69 years of age, and the number of subjects in the first study group was limited by protocol to 20.

Tables 2 and 3 present detailed and convincing data of three patients, and Figure 3 shows one patient's eye one day post-operatively. After four weeks of follow-up, we can report a significant improvement in mid- and near vision in the first 11 patients. Even distance vision has improved slightly post-operatively in our patients.

It is planned to include and treat other forms of ametropia (myopia, hyperopia and astigmatism) in this multicentre study and to document the treatment data to receive further CE approval for this thrilling IntraCOR procedure. ■

1. Meltendorf C, Schroeter J, Bug R, et al., Corneal trephination with the femtosecond laser, *Cornea*, 2006;25:1090–92.

2. Holzer MP, Rabsilber TM, Auffarth GU, Penetrating keratoplasty using femtosecond laser, *Am J Ophthalmol*, 2007;143:524–6.

3. Touboul D, Salin F, Mortemousque B, et al., Advantages and disadvantages of the femtosecond laser microkeratome, *J Fr Ophthalmol*, 2005;28(5):535–46.

4. Bahar I, Kaiserman I, McAllum P, Rootman D, Femtosecond

5. Farid M, Kim M, Steinert RF, Results of penetrating keratoplasty performed with a femtosecond laser zigzag incision initial report, *Ophthalmology*, 2007;114(12):2208–12.

6. Price FW Jr, Price MO, Femtosecond Laser Shaped Penetrating Keratoplasty: One-year Results Utilizing a Top-hat Configuration, *Am J Ophthalmol*, 2008;145(2):210–14.

7. Steinert RF, Ignacio TS, Sarayba MA, Top hat-shaped penetrating keratoplasty using the femtosecond laser, *Am J Ophthalmol*, 2007;143(4):689–91.

8. Farid M, Kim M, Steinert RF, Results of penetrating keratoplasty performed with a femtosecond laser zigzag incision initial report, *Ophthalmology*, 2007;114(12):2208–12.

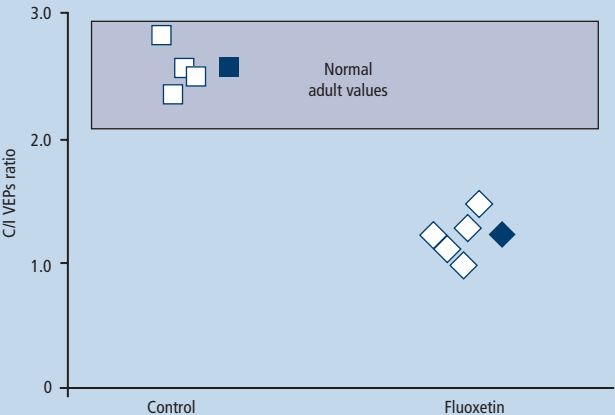
Antidepressant Restores Plasticity in the Adult Visual Cortex

Antidepressant fluoxetine may prove an effective treatment for amblyopia, according to a team of Italian and Finnish scientists at Scuola Normale Superiore, Consiglio Nazionale delle Ricerche and the University of Helsinki. Trials on rats revealed that long-term administration of the antidepressant reinstates a degree of ocular dominance plasticity in the visual system, similar to that observed at early stages of brain development, and promotes full recovery of vision in adult amblyopic animals. ■

Figure 1: The ocular dominance (OD) shift in response to monocular deprivation (MD) is a classic model of plasticity in the visual system. OD was assessed functionally as the ratio of VEPs amplitudes in response to stimulation of the contralateral and ipsilateral eye (C/I VEP ratio) in adult MD rats. The C/I VEP ratio is around 2.5 in normal adult animals. MD in control rats did not change binocularity in the visual cortex contralateral to the deprived eye (C/I VEP ratio 2.56±0.13, n=5). In contrast, fluoxetine-treated adult rats showed an OD shift in favor of the non-deprived eye after MD (C/I VEP ratio 1.2±0.1, t test p<0.001, n=4).

Source: Vetencourt JFM, et al., Science, 2008;320:385–8.

Figure 1: Reinstatement of Ocular Dominance Plasticity in Adulthood Following Chronic Antidepressant Treatment





EASY  
HANDLING

SURGICAL  
FREEDOM

ABSOLUTE  
CONTROL



# NEW HORIZONS

THE VERSATILE FEMTOSECOND LASER WORKSTATION

- > Newest Generation High Speed System
- > One System for all Femto-Applications
- > Anatomically Correct Eye Fixation
- > CustomFlap™ and Innovative Therapeutic Procedures
- > Free Choice of Surgical Parameters

20/10 PERFECT VISION AG  
Am Taubenfeld 21/1  
69123 Heidelberg, Germany  
Phone +49 6221 7502-0  
Fax +49 6221 7502-166  
E-Mail: info@2010pv.com

EMPOWERED BY SPHERICAL INTERFACE