

Better Monitoring of Age-related Macular Degeneration with Preferential Hyperacuity Perimetry

a report by

Michael Stur

Medical Retina Specialist, Department of Ophthalmology, Medical University of Vienna

DOI: 10.17925/EOR.2009.02.01.87

Worsening vision is an almost inevitable consequence of ageing. Age-related macular degeneration (AMD) in its advanced stage is the major cause of visual deterioration among the elderly of the industrialised world.^{1,2} Developing countries are rapidly closing the gap, and it is expected that in coming years the burden of AMD will dramatically increase in those countries as well.³ Despite the recent development of efficient therapeutic solutions, early detection of the advanced stage of AMD is still in its infancy. This article describes the benefits of a preferential hyperacuity perimetry (PHP) device in assisting early detection of advanced AMD, thereby possibly improving the outcome of treatment.

Progression of Age-related Macular Degeneration

AMD is a bilateral degenerative disease that affects the macula, the central portion of the retina. AMD occurs in two major patterns, starting with the atrophic non-exudative form (dry AMD) and eventually developing to the neovascular exudative form (wet AMD, or choroidal neovascularisation [CNV]). The non-exudative form is defined by pigmentary changes in the retinal pigment epithelium (RPE) and extracellular accumulation of debris material (drusen) between choroid and RPE. At this stage, these changes have little impact on vision – most patients retain good visual acuity – and the disease is mostly asymptomatic, although some patients report mild changes in visual acuity, blurring, decreased contrast sensitivity and weak adaptation to darkness. Prevalence of these early and intermediate stages of AMD is estimated at 15% among persons above 55 years of age,^{4,5} increasing from 2% for those 50–59 years of age to above 30% for those over 75 years of age.

Patients at risk are advised to take supplementary vitamins and to quit smoking. However, within five years over 6% of eyes diagnosed with dry AMD will develop a CNV lesion.⁴ CNV lesions can be classified as occult or classic according to their appearance on fluorescein angiography (FA). Occult lesions are more difficult to detect and develop relatively slowly. In the more aggressive classic lesion, the Bruch's membrane ruptures and choroidal blood vessels invade the subretinal space. Usually, the CNV lesion erupts at an extrafoveal location, but choroidal blood vessels rapidly proliferate towards the fovea. These *de novo* blood vessels characteristically leak, leading to haemorrhage and inflammatory processes. A secondary complication is retinal and/or RPE elevation due to the accumulation of subretinal and/or sub-RPE fluid, which can shift photoreceptors from their original position in the retina, resulting in metamorphopsia (perception of distorted lines). In some cases the photoreceptor layer can detach from the RPE layer, triggering the death of photoreceptors and leading to scotoma (loss of vision in defined areas of the visual field). These processes cause irreversible damage that, when reaching subfoveal

areas, affects central vision. If untreated, symptoms such as blurring, scotoma (holes in the visual field) and metamorphopsia rapidly worsen until vision deteriorates to legal blindness within several weeks or months. Although the prevalence of CNV is only 10–15% among patients with dry AMD, it is responsible for over 85% of blindness resulting from this disease.^{5–7} In some rare cases, a person affected by CNV may find his or her world changed overnight. In a person who loses vision in one eye as a result of CNV, the risk of developing advanced AMD in the second eye is as high as 43% within five years.⁸

Choroidal Neovascularisation Cannot Be Cured, But Treatment Can Stop Its Deterioration

CNV cannot be cured, but if caught in time its progression can be stopped. Until recently the gold standard for treatment of CNV was photodynamic therapy (PDT), which consists of intravenous injection of a photoactivating agent such as verteporfin (Visudyne, Novartis) and activation of this agent using a laser light source. In the retina, photoactivation occludes the exposed choroidal blood vessels and blocks their proliferation for some time. In recent years, since the realisation that blood vessels proliferate due to the normal presence of angiogenic agents in the retina, effective antiangiogenic strategies have been developed. Such treatments, including intravitreal injection of antiangiogenic factors such as bevacizumab (Avastin, Genentech) and ranibizumab (Lucentis, Genentech), also block choroidal neovascularisation and stop the rapid growth of blood vessels. A number of studies report that with sustained treatment regimens and frequent intravitreal injections vision can be partially restored.^{7,9}

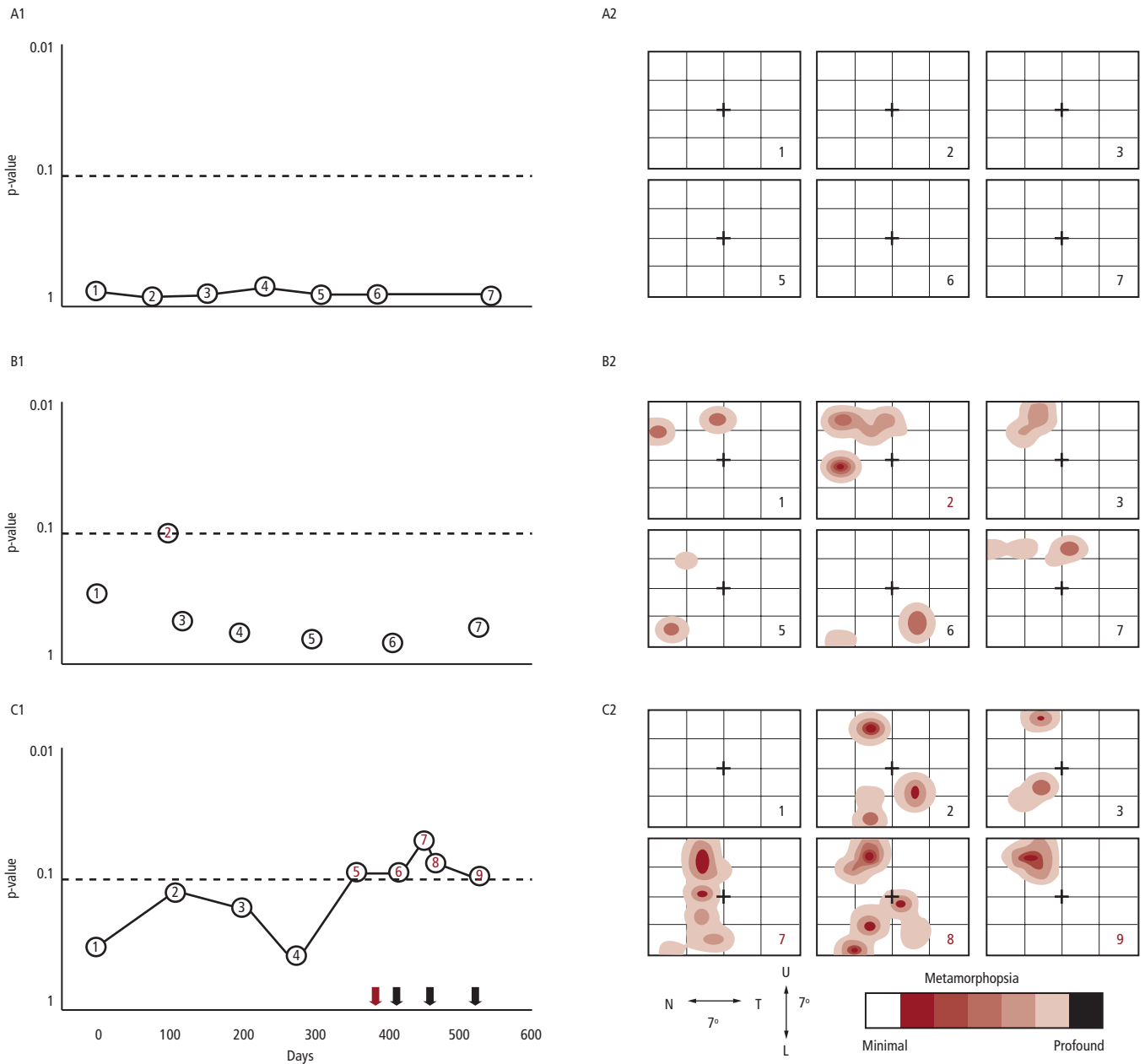
Early Detection Is a Key Factor in Therapeutic Success

The efficacy of any treatment is crucially dependent on early detection of the conversion event.¹⁰ Indeed, the first Treatment of Age-related Macular Degeneration with Photodynamic Therapy study group (TAP) and Verteporfin in Photodynamic Therapy study group (VIP) reports demonstrated that earlier detection enhanced the benefit of photodynamic therapy.¹¹ According to the MARINA and ANCHOR studies, smaller lesion size at baseline (i.e. earlier detection) also predicts a better treatment outcome in ranibizumab-treated



Michael Stur is a medical retina specialist in the Department of Ophthalmology at the Medical University of Vienna. He has been principal investigator in many multicentre trials such as the TAP study group and the VIP trial. Professor Stur graduated from the University of Vienna in 1977 and achieved certification as an ophthalmologist in 1985 and habilitation in 1989.

Figure 1: Three Representative Examples of Patients Monitored with Preferential Hyperacuity Perimetry Over a Period of 15 Months



Left panels (A1, B1, C1) show the time course of probability that a patient performed a preferential hyperacuity perimetry (PHP) test consistent with the non-exudative form. Values >0.1 (points below the dotted horizontal line) are considered within normal limits (WNL). Right panels (A2, B2, C2) show spatial maps of visual field abnormalities recorded by PHP tests at the times designated by the numbers at the lower right corner of each map. The cross at the centre of each map represents the fovea. Dark colours indicate severe visual field defects. A1–A2: This patient remained non-exudative throughout the study. All tests performed by this patient were WNL. B1–B2: As in A, this patient did not develop a choroidal neovascularisation (CNV) lesion during the study. Except for the second test, all tests were WNL. A re-test performed weeks following the second test was again WNL, supporting that the outside normal limit (ONL) test was a false-positive. C1–C2: In this case a CNV lesion was diagnosed on day 392 of the study (red arrow), and a series of ranibizumab intravitreal injections was started shortly after (black arrows). In this example, the first ONL PHP (test 5) was performed on day 357 of the study, before CNV diagnosis with fluorescein angiography (FA). All subsequent PHP tests were ONL as well.

patients.^{12,13} Unfortunately, the majority of CNVs are large and subfoveal at diagnosis,¹⁴ explaining why treatment with even the most advanced techniques is only partially successful. For example, in patients treated with ranibizumab, visual acuity improves in only 40% of cases when the CNV lesion is classic, and in only 34% of cases when the lesion is occult.^{9,15} Because the non-exudative form of AMD may remain stable for many years, it is currently impossible to predict when, and if at all, a patient with non-exudative AMD will develop a CNV lesion. In the best of cases, high-risk patients will undergo a biomicroscopy examination at the clinic once every several months, a frequency that may be too low to catch a conversion in time. To

complicate things even more, in occult CNV the neovascularisation is often contained beneath the RPE and the CNV lesion is harder to detect with biomicroscopy, even to an experienced eye. Often, an occult lesion may remain undetected for many months until the lesion transforms into the classic and more aggressive form.

Management of High-risk Age-related Macular Degeneration

The gold standard for CNV diagnosis is FA, in which a dye is intravenously injected and leakage of the dye is imaged a few seconds later in the retina. In principle, early detection of CNV could be

enhanced if FA were routinely performed at each visit to the clinic, but FA is expensive and time-consuming and can have side effects. Recently, optical coherence tomography (OCT) has emerged as an important imaging technique that could assist the practitioner in reaching more educated decisions, but the reproducibility and accuracy of OCT have yet to be demonstrated.

Another category of examination deals with the visual perception of the patient. A common and easy-to-use 'tool' used by practitioners to obtain such information is the Amsler grid. The Amsler grid is a square tabloid of horizontal and vertical lines that can help in the detection of visual abnormalities. The patient is asked to cover one eye and with the examined eye to look for blurring, missing segments or waviness of the lines while fixating on the centre of the grid. Unfortunately, the Amsler grid suffers from low performance due to a number of psychophysical effects, such as unforced fixation (difficulty of maintaining the gaze on a fixed point), cortical completion (filling in of missing or distorted information by the brain) and perceptual crowding (difficulty of detecting minute peculiarities in a visual scene loaded with details).¹⁶

Foresee Preferential Hyperacuity Perimetry

The Foresee PHP is a psychophysical test that was developed to answer the shortcomings of the Amsler grid and to provide a better way of mapping visual field abnormalities associated with CNV.^{17,18} The PHP test takes advantage of the sensitive visual function of hyperacuity, which enables one to perceive minute misalignments of objects relative to each other. In the PHP test, visual field abnormalities are mapped with stimuli that are projected immediately after the gaze is attracted to the centre of the visual field (thereby enforcing fixation), localised (solving the crowding problem) and briefly flashed (solving the cortical completion problem, since filling in is a time-dependent mechanism).

The PHP test is based on the competition theory, which postulates that visual attention is attracted to the most prominent source of visual information. The test consists of a series of hyperacuity stimuli successively flashed on a touch screen. Each stimulus is a vertical or horizontal dotted line, including a localised misalignment of several dots. Minute misalignments, in the order of fractions of degrees, are normally perceived as waves or artificial distortions (ADs). The patient's task is to mark the location of the perceived wave on the touch screen. It should be noted that in CNV photoreceptors may be shifted away from their normal position due to RPE elevation, thereby creating the perception of distortion. Hence, if a stimulus is flashed at a retinal location that falls on a CNV lesion, the patient may perceive a pathological distortion (PD) in addition to the AD. According to the competition theory, if the PD is small compared with the AD, visual attention is preferentially drawn to the AD and the PD is overlooked. The opposite occurs if the PD is considerably larger relative to the AD. An interesting case is when the PD and the AD are comparable in size. In this case the patient may perceive the two distortions and, hence, mark them both. The PHP takes advantage of this preferential looking principle to quantify the degree of metamorphopsia perceived by the patient. At the end of the test, a Bayesian classifier – pre-trained with a normative database comprising hundreds of tests performed by diagnosed CNV and intermediate AMD patients – calculates the probability that this test was produced by an intermediate AMD patient or by a CNV patient.

Foresee^{PHP}[®]

You Foresee They See

Visit our booth 1705

*Free
Phone
Strap*



New Standard in Early Detection of CNV

- Detect CNV lesion before patients feel any symptoms
- Patient friendly
- Automated test results
- Fast return on investment



NOTAL VISION[®]
Your sight is our Vision

www.notalvision.com

Clinical Results of Preferential Hyperacuity Perimetry

A number of studies have been conducted to demonstrate the value of PHP in assisting the practitioner in early detection of CNV. The first PHP study demonstrated that PHP is significantly superior to the Amsler grid in terms

Regular testing with preferential hyperacuity perimetry can detect choroidal neovascularisation resulting from age-related macular degeneration even before the appearance of symptoms, and in some cases even before clear biomicroscopy evidence is observed.

of both sensitivity (the proportion of positive results among patients with CNV) and specificity (the proportion of negative results among patients with no CNV).¹⁶ A multicentre study was conducted to confirm these results, demonstrating that PHP can detect recent-onset CNV with a sensitivity of 82% and a specificity of 88%,¹⁸ which compares with a sensitivity of 70% and a specificity of 95% for manual reviews of colour stereo photographs by a group of retina specialists (thereby simulating biomicroscopy). These results demonstrate that the PHP can help in detecting small lesions that may be missed in biomicroscopy, even by skilled practitioners.

My Experience of Long-term Monitoring of Non-exudative Age-related Macular Degeneration Patients with Preferential Hyperacuity Perimetry

In this report I describe my experience with long-term monitoring of non-exudative AMD patients with PHP. Eyes with high-risk AMD characteristics were monitored over the course of 15 months, with PHP tests performed at regular three-month intervals unless the PHP test yielded an outside normal limits (ONL) result; in such cases a re-test was performed within two weeks. If the re-test was also ONL, further tests (biomicroscopy and FA) were conducted to confirm or rule out the occurrence of a CNV lesion. Detailed results of this study will be published in a peer-reviewed journal. The majority of patients did not

deteriorate to the exudative form during the period of the study. Most tests performed by these patients were within normal limits (WNL). Two examples are illustrated in panels A and B of *Figure 1*.

A small number of patients developed a CNV lesion during the study. Following diagnosis, these patients started a monthly regimen of intravitreal injections (bevacizumab or ranibizumab) while PHP monitoring continued. In most of these patients the PHP test was ONL before or on the same day as the diagnosis. An example of such a case is shown in panel C of *Figure 1*.

Conclusions

Regular testing with PHP can detect CNV resulting from AMD even before the appearance of symptoms, and in some cases even before clear biomicroscopy evidence is observed. This provides an earlier opportunity to initiate treatment of CNV, thereby increasing the likelihood of favourable long-term visual prognosis. In a long-term study conducted with PHP, most conversions to CNV were identified with the PHP prior to or on the same day as diagnosis. A small rate of false-positive tests was also observed, but often these PHP defects correlated with some type of

Preferential hyperacuity perimetry can help in detecting small lesions that may be missed in biomicroscopy, even by skilled practitioners.

macular pathology other than CNV. Thus, it is possible that evaluation of visual field abnormalities with a PHP test may be further refined by comparing the test results with previous tests by the same patient – rather than comparing each test with the normative database – as a base for determining the possibility of a CNV conversion. Increasing the frequency of monitoring utilising the PHP test may prove instrumental in assisting early diagnosis of CNV, thereby significantly improving the visual outcome of treatment. It is anticipated that the diagnostic value of this technology will be further enhanced in the near future with the introduction of the Foresee home test device.¹⁹ ■

- Pascolini D, Mariotti SP, Pokharel GP, et al., 2002 global update of available data on visual impairment: a compilation of population-based prevalence studies, *Ophthalmic Epidemiol*, 2004;11(2):67–115.
- Jager RD, Mieler WF, Miller JW, Age-related macular degeneration, *N Engl J Med*, 2008;358(24):2606–17.
- Nazimul H, Rohit K, Anjli H, Trend of retinal diseases in developing countries, *Exp Rev Ophthalmol*, 2008;3(1):43–50.
- The Age-Related Eye Disease Study Research Group. Potential public health impact of the Age-Related Eye Disease Study results. AREDS Report No. 11, *Arch Ophthalmol*, 2003;121:1621–4.
- Klein R, Klein BE, Linton KL, Prevalence of age-related maculopathy. The Beaver Dam Eye Study, *Ophthalmology*, 1992;99:933–43.
- Ferris FL 3rd, Fine SL, Hyman L, Age-related macular degeneration and blindness due to neovascular maculopathy, *Arch Ophthalmol*, 1984;102(11):1640–42.
- Spaide RF, Laud K, Fine HF, et al., Intravitreal bevacizumab treatment of choroidal neovascularization secondary to age-related macular degeneration, *Retina*, 2006;26(4):383–90.
- Age-Related Eye Disease Study Research Group, A Simplified Severity Scale for Age-Related Macular Degeneration. AREDS Report No. 18, *Arch Ophthalmol*, 2005;123:1570–74.
- Rosenfeld PJ, Brown DM, Heier JS, et al.; MARINA Study Group, Ranibizumab for neovascular age-related macular degeneration, *N Engl J Med*, 2006;355(14):1419–31.
- Loewenstein A, The significance of early detection of age-related macular degeneration, *Retina*, 2007;27(7):873–8.
- Blinder KJ, Bradley S, Bressler NM, et al.; Treatment of Age-related Macular Degeneration with Photodynamic Therapy Study Group; Verteporfin in Photodynamic Therapy Study Group, Effect of lesion size, visual acuity, and lesion composition on visual acuity change with and without verteporfin therapy for choroidal neovascularization secondary to age-related macular degeneration: TAP and VIP report no. 1, *Am J Ophthalmol*, 2003;136(3):407–18.
- Boyer DS, Antoszyk AN, Awh CC, et al.; MARINA Study Group, Subgroup analysis of the MARINA study of ranibizumab in neovascular age-related macular degeneration, *Ophthalmology*, 2007;114(2):246–52.
- Kaiser PK, Brown DM, Zhang K, et al., Ranibizumab for predominantly classic neovascular age-related macular degeneration: subgroup analysis of first-year ANCHOR results, *Am J Ophthalmol*, 2007;144(6):850–57.
- Sivaprasad S, Hammond C, Jackson H, Chong V, Proportion of treatable subtypes of choroidal neovascular membranes in age-related macular degeneration, *International Congress Series*, 2005;1282:312–16.
- Brown DM, Kaiser PK, Michels M, et al.; ANCHOR Study Group. Ranibizumab versus verteporfin for neovascular age-related macular degeneration, *N Engl J Med*, 2006;355(14):1432–44.
- Loewenstein A, Malach R, Goldstein M, et al., Replacing the Amsler grid: a new method for monitoring patients with age-related macular degeneration, *Ophthalmology*, 2003;110(5):966–70.
- Alster Y, Bressler NM, Bressler SB, et al.; Preferential Hyperacuity Perimetry Research Group. Preferential Hyperacuity Perimeter (PreView PHP) for detecting choroidal neovascularization study, *Ophthalmology*, 2005;112(10):1758–65.
- Goldstein M, Loewenstein A, Barak A, et al.; Preferential Hyperacuity Perimeter Research Group. Results of a multicenter clinical trial to evaluate the preferential hyperacuity perimeter for detection of age-related macular degeneration, *Retina*, 2005;25(3):296–303.
- Pollack A, Katz H, Manor Y, Performance of Elderly Subjects in Self Operation of the Home Macular Perimetry (HMP) Test, ARVO Meeting, 2008; abstract 258/A567.