

Case Report of Isolated Schwannoma— A Rare Eyelid Tumor

Sudhir Singh, MS,¹ Subodh Saraf, MS,² Divyesh Goswami, MD³ and Sumit Singh, DOMS⁴

1. Senior Consultant and Head of Department, Department of Ophthalmology, JW Global Hospital & Research Centre, Mount Abu, Rajasthan, India; 2. Ophthalmology Registrar, Global Health Institute of Ophthalmology, Sirohi, Rajasthan, India; 3. Consultant Pathologist, JW Global Hospital & Research Centre, Mount Abu, Rajasthan, India; 4. Consultant Ophthalmologist, Mathura, Uttah Pradesh, India

Abstract

Schwannoma (neurilemmoma) is a benign tumor of the peripheral nerve arising from Schwann cells that form the neural sheath. Schwannoma of ophthalmic interest is rare. Although it has been reported in relation to the orbit, and less frequently with the uveal tract and conjunctiva, instances of eyelid Schwannoma are extremely uncommon. We report a case of a 18-year-old male who developed eyelid Schwannoma. The mass was surgically removed by excisional biopsy. The histopathologic examination showed Schwannoma.

Keywords

Benign tumour, eyelid, histopathology, Schwannoma

Disclosure: Sudhir Singh, MS, Subodh Saraf, MS, Divyesh Goswami, MD and Sumit Singh, DOMS, have no conflicts of interest to declare. No funding was received for the publication of this article.

Received: April 15, 2013 **Accepted:** May 28, 2014 **Citation:** *US Ophthalmic Review*, 2014;7(2):143–5 DOI: 10.17925/USOR.2014.07.02.143

Correspondence: Sudhir Singh, MS, Ophthalmology, Senior Consultant & HOD, Department of Ophthalmology, JW Global Hospital & Research Centre, Mount Abu, Rajasthan 307501, India. E: drsudhirsingh@gmail.com

Case Report

An 18-year-old male presented to us with a 6-month history of slowly enlarging, painless mass in his right upper lid resulting in progressive ptosis. Ocular examination was suggestive of a firm, nontender nodule 2 × 1 × 1 cm in size on the left upper lid. The mass was nonadherent to the skin and was mobile on palpation.

There were no clinical findings indicative of neurofibromatosis (see *Figures 1 and 2*).

The patient was operated under local anesthesia. Two silk sutures were taken near the lid margin to provide traction if required during surgery. The globe was secured with an entropion plate. Lid crease incision was performed superficial to tarsal plate. The lesion was isolated from the surrounding tissue by blunt dissection. The capsule was present over the lesion. Dissection was easily carried out in the extra capsular plane except for the lower portion of around 2 × 2 mm, which was found adherent with tarsal plate. The lesion was excised completely along with some part of tarsal plate. No communication with the supraorbital nerve could be identified (see *Figures 3 and 4*).

The tarsal plate was sutured with 6-0 vicryl continuous sutures. Skin was sutured with interrupted 6-0 vicryl. Eyelid movements were present on table. Patient's ptosis was recovered on first post op day (see *Figures 5 and 6*).

Gross Examination

The tumor was an encapsulated nodular lesion 2.4 x 1.7 x 1.5 cm in size. The consistency was firm with whitish appearance at cross section (see *Figures 7 and 8*).

Microscopic Examination

H & E stained sections showed alternating areas of highly cellular (Antoni A) and hypocellular (Antoni B). The spindle cells of the Antoni A cells, which contain elongated nuclei arranged in fascicles, nuclei tend to palisade (see *Figure 9*).

Antoni B area homogenous acellular material, in which the cells were more oval, and had rounded nuclei, clear cytoplasm, and less basement membrane, was loosely entwined within a clear myxoid matrix.

Discussion

Proliferating Schwann cells of the peripheral nerve make up Schwannoma—a rare benign neurogenic tumor. It is a neoplasm that occurs wherever Schwann cells are present, that is, in any myelinated peripheral nerve. In most cases, while schwannoma is sporadically manifested as a single benign neoplasm, the presence of multiple Schwannoma is usually indicative of neurofibromatosis-2. Our patient had isolated eyelid Schwannoma with no family history or clinical findings of neurofibromatosis-1 or -2.

Figure 1: Right Eye Upper Lid Ptosis Due to the Schwannoma

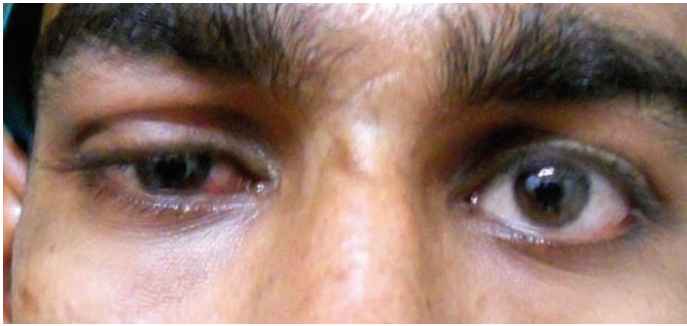

Figure 2: Clinical Appearance of the Right Eye Upper Lid Schwannoma During Examination

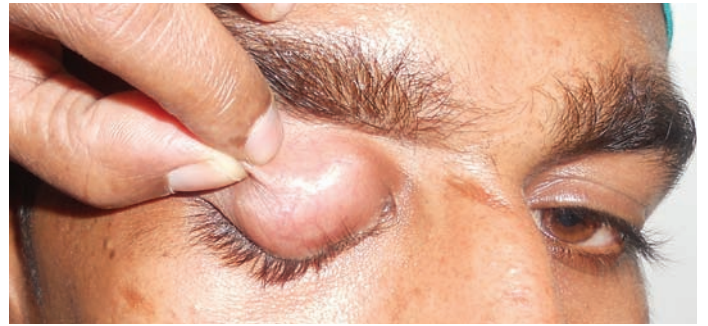

Figure 3: Appearance of the Schwannoma After Dissection from the Surrounding Lid Structures Just Before Excision

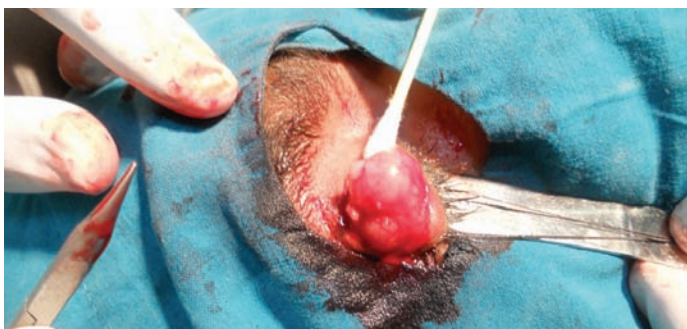

Figure 4: Showing Tarsal Plate Button Holing After Complete Excision of the Schwannoma

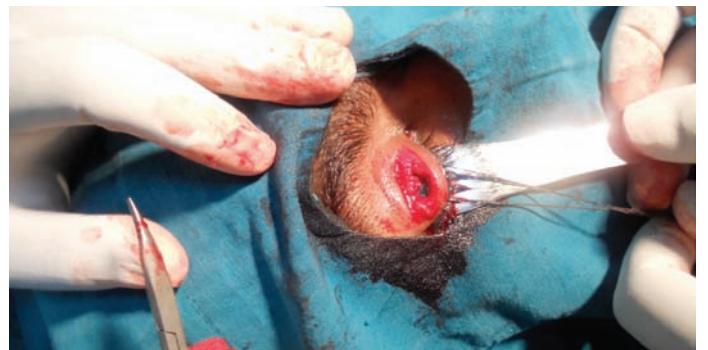

Figure 5: First Post-operative Day Photograph Showing that Right Eye Upper Lid Ptosis was Fully Recovered

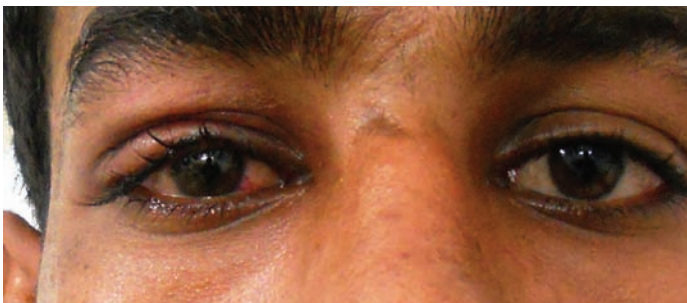

Figure 6: First Post-operative Day Photograph Showing No Lagophthalmos in Right Eye Upper Lid

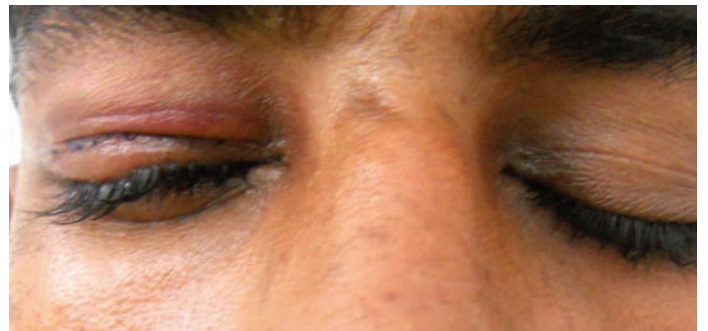

Figure 7: Gross Appearance (2.4 x 1.7 x 1.5 cm) of the Schwannoma After Excision

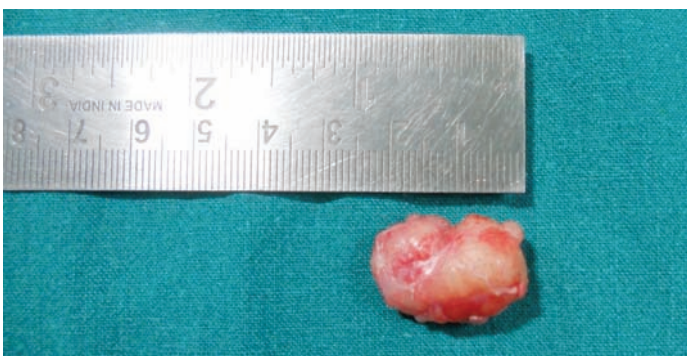
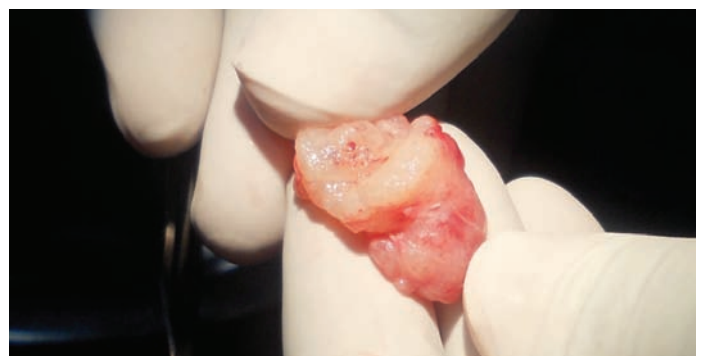
Figure 8: Cross-section of the Specimen Showing Whitish Appearance



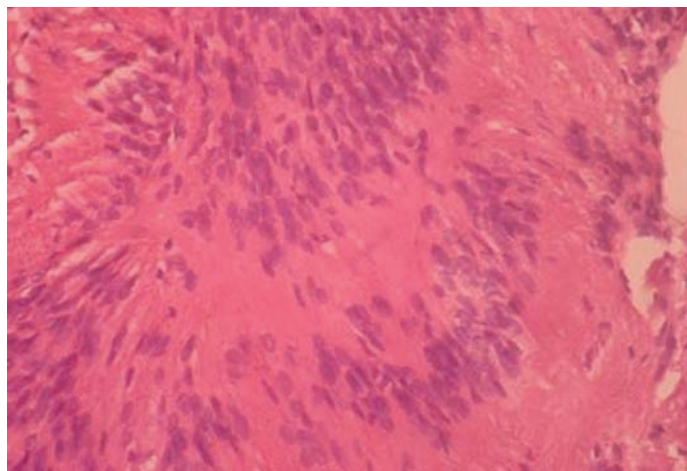
Clinically, the tumor is a solid, slowly progressive and painless mass. Due to its rarity and unusual location, eyelid Schwannoma is frequently confused with other diagnosis, such as chalazion or inclusion cyst. In our case, the patient presented with solid slowly enlarging, painless mass of 6-month duration. Literature suggests that the tumor, though rare, can be present in both upper and the lower eyelids. Macroscopically, they appear to be well demarcated, they usually grow very slowly, and are asymptomatic. Microscopically, they may demonstrate a biphasic pattern with areas of highly cellular (Antoni type A) and myxoid matrix (Antoni type B).¹ The cells tend to align themselves into compact parallel rows, with intermittent dense anucleate zones. In other locations, a poor prognosis has been described if the cells are fusiform, contain melanin granules, or if epithelioid cells are present.¹ Nevertheless, malignant transformation has not been reported in eyelid Schwannomas.

The most important feature in its diagnosis remains the strong reactivity to S100 protein by immunohistochemistry, particularly in Antoni type A areas. Despite sometimes striking cytologic atypia, mitotic figures are rare. It is postulated that degenerative changes occur due to the long period of time over which large Schwannomas develop.¹

The age range in the adult group of published cases (>40 years) was between 19 and 63. The size of the tumor ranges from few millimetres to 3.5 cm.²

Management of Schwannoma of the eyelid is complete excision with clear margin to establish the histopathologic diagnosis and prevent recurrence. Incomplete removal is associated with eventual recurrence and more

Figure 9: Hematoxylin and Eosin Stain



Hematoxylin and eosin (original magnification 40 x) stain section features were fusiform cells with elongated nuclei arranged in fascicles, tends to palisade.

aggressive behaviour. There have been anecdotal reports of malignant changes in a previously incompletely excised benign Schwannoma. The swelling also tends to transgress tissue planes and grow rapidly on incomplete excision.^{3,4} An attempt to preserve continuity of nerve should be made, but this is not always possible and does not appear to have any major consequences at this site. ■

Informed consent was received from the patient involved in the study.

1. Elena López-Tizón, Enrique Mencia-Gutiérrez, Esperanza Gutiérrez-Díaz, José R Ricoy, Schwannoma of the eyelid: report of two cases, *Dermatology Online Journal*, 2007;13:12.
2. Patil SB, Kale SM, Jaiswal S, Khare N, Schwannoma of upper eyelid: A rare differential diagnosis of eyelid swellings, *Indian J Plast Surg*, 2010;43:213–5.
3. Shields JA, Guibor P, Neurilemoma of the eyelid resembling a recurrent chalazion, *Arch Ophthalmol*, 1984;102:1650.
4. Shields JA, Kiratli H, Shields CL, et al., Schwannoma of the eyelid in a child, *J Pediatr Ophthalmol Strabismus*, 1994;31:332–3.