First Postoperative Day Visual Outcome Following 6 mm Manual Small Incision Cataract Surgery Using Intratunnel Phacofracture Technique

Sudhir Singh, MS

Senior Consultant and Head, Department of Ophthalmology, JW Global Hospital & Research Centre, Mount Abu, Rajasthan, India

Abstract

Object: To study first postoperative day visual outcome following 6 mm manual small incision cataract surgery (MSICS) using intratunnel phacofracture technique. **Design:** Retrospective design. **Setting:** Tertiary eye care centre. **Participants:** A total of 216 patients who underwent MSICS performed by a single surgeon at the JW Global Hospital & Research Centre, Mount Abu, India from April 2012 to March 2013. Cataract patients with any other ocular comorbidity were not included. One hundred and thirty-six cataract patients (72 male/64 female) with a mean age of 59.75 years (range 40–80 years) were included in the study. All surgeries were performed by a single surgeon using the 6 mm MSICS intratunnel phacofracture technique. **Outcome measures:** The first postoperative uncorrected visual acuity (UCVA), best corrected visual acuity (BCVA), and rates and types of complications were recorded. **Results:** A total of 136 surgeries were performed using the 6 mm MSICS intratunnel phacofracture technique. All the surgeries were performed by a single experienced surgeon. The mean UCVA and mean BCVA at first postoperative day were 0.367 (Snellen equivalent 20/46) and 0.226 (Snellen equivalent 20/33) log MAR units, respectively. No serious peri- and postoperative complications were encountered. **Conclusions:** The 6 mm MSICS is a safe, fast, and low-cost cataract extraction technique. It is an effective alternate to costly phacoemulsification.

Keywords

MSICS, intratunnel, phacofracture, SICS, cataract

Disclosure: Sudhir Singh, MS, has no conflicts of interest to declare.

Received: October 29, 2013 **Accepted**: March 14, 2014 **Citation**: *US Ophthalmic Review,* 2014;7(1):26–30 *DOI: 10.17925/USOR.2014.07.01.26*

Correspondence: Sudhir Singh, MS, Senior Consultant and Head, Department of Ophthalmology, JW Global Hospital & Research Centre, Mount Abu, Rajasthan 307501, India. E: drsudhirsingh@gmail.com

Cataract is the leading cause of avoidable blindness in the world.[1] Manual small incision cataract surgery (MSICS) and phacoemulsification (phaco) are the most popular methods of cataract extraction today. MSICS is significantly faster, less expensive, and less technology-dependent than phaco, and has been extensively practiced in developing countries such as India. It has similar advantages of phaco in the rehabilitation of the cataract blind. It is also easier for a surgeon trained in extracapsular cataract extraction (ECCE) surgery to master MSICS than phaco. There is no dependence on the phaco machine, and the learning curve is less steep than that of phaco. MSICS was propagated for high-quality, high-volume cataract surgery at the Aravind Eye Hospital, India[2,3] and in Nepal.[4]

The most commonly practiced MSICS techniques are Blumenthal, visco-expression, irrigating wire vectis, and fish hook needle. These techniques require a 7 to 9 mm large incision, which leads to more astigmatism. Therefore, if the nucleus is managed to be removed through a sub-6 mm incision at the appropriate site it would result in approximately the same astigmatism as 3.2 mm phaco.[5–8] Using our technique, intratunnel phacofracture, all type cataracts can be managed through a sub-6 mm incision. Hence results are similar to phaco. To the best of our knowledge, this is the first study to study postoperative day visual outcome following 6 mm MSICS using the intratunnel phacofracture method of nucleus delivery.

Review of Literature

A common feature of the MSICS techniques reviewed in the literature is that the nucleus is prolapsed into the anterior chamber (AC). The nucleus may then be removed by any of the following techniques:

- Nucleus delivery using an irrigating vectis[2,3,9,10] or a curved cystitome—the fish hook.[4]
- Using two instruments to sandwich the nucleus between them.[11–13]
- Bisecting the nucleus into two using two instruments: one as the 'cutter;' the other, usually a vectis, as the board.[11,14,15]
- Using a snare similar to the tonsillar snare.[11]
- Dividing the nucleus into three parts (trisection) using a triangular instrument and a vectis.[16]
- Using an AC maintainer and a Sheet's glide (the Blumenthal technique).[11,17]
- Viscoexpression of the nucleus.
- Intratunnel phacofracture technique (our technique).

Material and Methods

We examined the records of 216 patients who underwent MSICS performed by a single experienced surgeon (SS) at the JW Global Hospital & Research Centre, Mount Abu, India from April 2012 to March 2013. Informed consent was taken from all patients. We included all cases with immature senile cataracts (IMSC), mature senile cataracts (MSC), hypermature senile cataracts (HMSC), posterior subcapsular cataract (PSC), posterior polar cataracts (PPC), and nuclear cataracts. Cataracts patients with any other ocular comorbidity were not included One hundred and thirty-six cataract patients (72 male/64 female) with a mean age of 59.75 years (range 40–80 years) were included in the study. Cataracts patients with good fixation and without any other ocular comorbidity were included. A full preoperative ophthalmic examination was performed. Preoperative data collection for each eye included the patient's age and gender, preoperative visual acuity (VA) (uncorrected and best corrected VA [UCVA and BCVA]) and details of slit-lamp examination. Intraocular pressure was recorded by Sctiøtz tonometry in all cases. The posterior pole was examined with slit-lamp biomicroscopy and indirect ophthalmoscopy. Axial length measurements and keratometry recordings were taken and Sanders-Retzlaff-Kraff (SRK)-II formula was used to calculate the intraocular lens (IOL) power required. First-day postoperative vision was assessed by unaided VA and pin hole (PH) VA.

Surgical Technique

Six mm Manual Small Incision Cataract Surgery with Intratunnel Phacofracture Technique

All surgeries were performed under peribulbar/topical anesthesia by a SS. A 4/0 silk bridle suture was placed beneath the tendon of the superior rectus muscle. A superotemporal quadrant for the right eye and a superonasal quadrant for the left eye was chosen if K1 and K2 difference was equal or less than 1.0 diopter (D). If the K1 and K2 difference was more than 1.0 D then the incision was made on a steeper axis. A fornix-based conjunctival flap at the limbus with a chord length of approximately 6.5 mm was made. After careful dissection of the Tenon's capsule, light cautery was applied. A 6 mm scleral frown incision, 1.5 mm from the limbus, was made with a No. 15 Bard Parker blade (see *Figure 1*). A funnel-shaped sclerocorneal pocket incision was created with a steel crescent knife. One side port was made 90° apart on either side of the scleral tunnel with a 15° knife temporally in right eye and nasally in the left eye. With a 2.8 mm keratome, the AC was entered 1.5 mm into the clear cornea. The AC is entered with 1.5 mm in clear cornea with help of 3.2 mm keratotome (see *Figure 2*).

The hydroxylpropyl methylcellulose (HPMC) 2 % viscoelastic was injected into the AC. The central circular capsulorhexis (CCC) was made with help of 26 gauze needle capsulotome. If glow was poor then the capsule was stained with trypan blue dye under the air bubble. Then viscoelastic was injected and CCC performed. The size of CCC depends on the size of the nucleus. It may vary from 5.5 mm to 7.5 mm (see *Figure 3*).

If the nucleus size was anticipated to be large then two relaxing incisions were made at the CCC margins. The hydrodessection was made with 26 gauze cannula place on 2 cc syringe filled with irrigating fluid. The internal incision of the tunnel was enlarged sideways to 7 mm with a 5.1 mm keratotome (see *Figure 4*).

Enough viscoelastic was placed between the cornea and the superior surface of the nucleus to protect the endothelium and between the nucleus and iris to keep the iris away from nucleus. The nucleus was rotated within the capsule using a Sinskey hook. The nucleus was prolapsed into the AC using a Sinskey hook. A Sinskey hook was used to retract the capsulorrhexis to engage the equator and lever one pole out of the nucleus outside the capsular bag and the rest of the nucleus was rotated into the AC. If the nucleus was too large then two or three relaxing incisions were made at the capsulorrhexis margins at equidistance (see *Figure 5*).

Figure 1: Fornix-based Conjuctival Flap, Cautary, and Partial Scleral Groove Demonstration

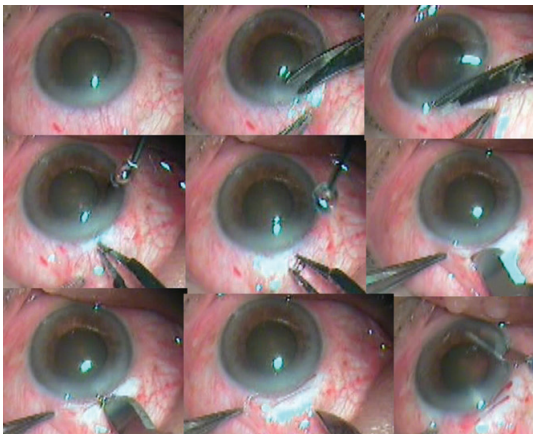

Figure 2: Corneoscleral Tunnel Making Demonstration

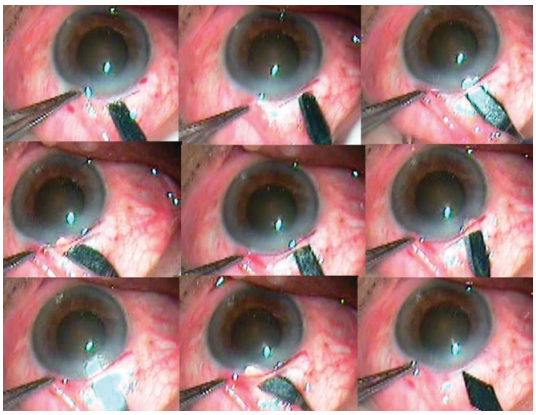

Figure 3: Capsular Staining and Capsulorhexis Creation with Needle Capsulotome

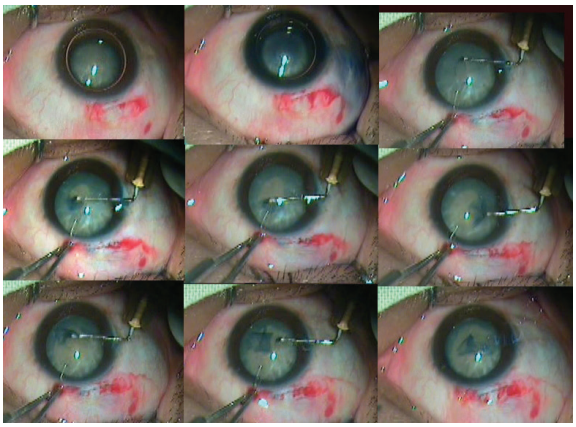

Figure 4: Tunnel Enlargement with 5.1 mm Keratotome and Enlargement of the Internal Incision with 2.8 mm Keratome

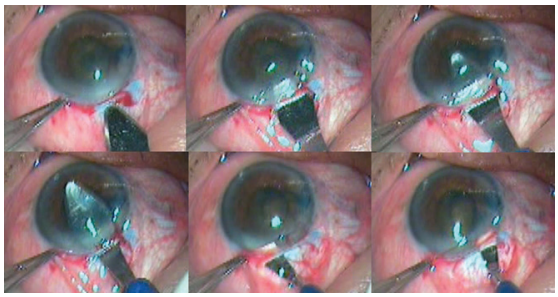

Figure 5: Nucleus Rotation and Prolapse in Anterior Chamber

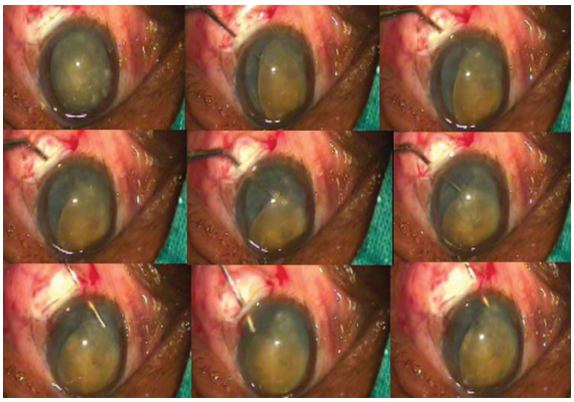

The globe was stabilized and a small Levis lens loop (AA 1915 from Appasamy Associates, Tamil Nadu, India) was introduced through the tunnel and positioned between the iris and the nucleus. The nucleus was engaged in the lens loop and slowly withdrawn from the AC while the posterior lip of the tunnel is depressed. Once the nucleus was engaged in the tunnel then the wire vectis was pulled posteriorly and upwards. This caused breaking and removal of a part of the nucleus; the other part remains engaged in the tunnel. By using a viscoelastic the engaged part of the nucleus was pushed back into the AC and rotated so its longitudinal axis coincided with the longitudinal axis of the tunnel. Again, viscoelastic was placed between the cornea and superior surface of the nucleus and between the nucleus and iris. The lens loop was introduced through the tunnel and positioned between the iris and the remaining part of the nucleus. Part of the nucleus was engaged in the lens loop and slowly withdrawn from the AC while the posterior lip of the tunnel was depressed. In most cases, the remaining part of the nucleus came out. If it continued to break down, then the remaining part was again pushed into the AC with help of viscoelastic and the previous steps were repeated till it came out (see *Figure 6*).

The remaining cortical matter clean up was performed with a direct 23 gauge Simcoe irrigating aspirating cannula. The AC was formed with viscoelastics. A single piece of polymethylmethacrylate (PMMA) IOL of 6 mm optic size and 12.5 mm total size was implanted into the capsular bag. The AC was washed out thoroughly by Simcoe IA cannula using Ringer's lactate solution. The conjunctival flap is reposited back and cauterized at the edges. Tunnel and side ports were hydrated. A 0.5 cc subconjuctival gentamycin with dexamethasone injection was given (see *Figure 7*). Tobramycin 0.3 % with dexamethasone eye drops were administered three times a day for 30 days. Moxifloxacin 0.3 % eye drops were administered three times a day for the first 5 days and then discontinued. The patients were examined the next day.

Figure 6: Demonstration of Intratunnel Phacofracture Using Levis Lens Loop

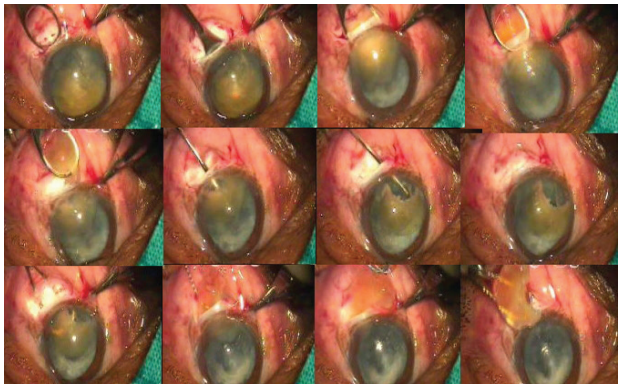

Figure 7: Irrigation Aspiration, Intraocular Lens Implantation, Wound Sealing, and Conjuctival Flap Repositioning

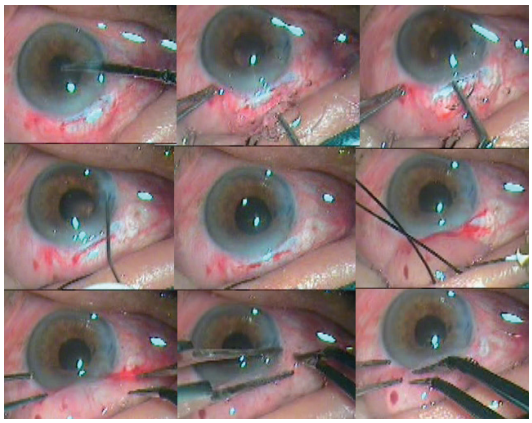

The UCVA, BCVA, and slit-lamp examination findings were recorded (available at www.youtube.com/watch?v=OrmqCWOZIXA&feature=youtu.be).

Results

A total of 216 cases 6 mm MSICS with intratunnel phacofracture of which 136 satisfied the above-mentioned inclusion criteria were reviewed. The mean age at presentation was 59.75 years (range 40–80 years) with a male:female ratio of 1.3:1. (see *Table 1*).

Of the 136 patients, 45 (33.08 %) had IMSC, 10 (7.35 %) had MSC, 26 (19.11 %) had HMSC, 7 (5.14 %) had PSC, 12 (8.82 %) had PPC and 36 (26.47 %) had nuclear cataracts (see *Table 2*).

Of the 136 patients, the first postoperative day UCVA were: 7 (5.14 %) had 6/6, 29 (21.32 %) had 6/9, 32 (23.52 %) had 6/12, 48 (35.29 %) had 6/18,

Table 1: Patient Demographic Data

Patients	Number (%)	Mean Age (Range) In Years
Male	72 (52.94)	59.16 (40–80)
Female	64 (47.06)	60.50 (45–75)
Total	136 (100)	59.75 (40–80)

Table 2: Types of Cataracts

Type of Cataracts	Patient Number (%)
Immature senile cataracts	45 (33.08)
Mature senile cataracts	10 (7.35)
Hypermature senile cataracts	26 (19.11)
Posterior subcapsular cataract	12 (8.82)
Posterior polar cataracts	7 (5.14)
Nuclear cataract	36 (26.47)

Table 3: First Postoperative Uncorrected Visual Acuity

Visual Acuity	Patient Number (%)	Patient Cumulative Number (%)
6/6	7 (5.14)	7 (5.14)
6/9	29 (21.32)	36 (26.47)
6/12	32 (23.52)	68 (50.00)
6/18	48 (35.29)	116 (85.29)
6/24	16 (11.76)	132 (97.05)
6/36	4 (2.94)	136 (100)

16 (11.76 %) had 6/24, and only 4 (2.94%) had 6/36. Cumulatively 50 % presented with 6/12 or better UCVA and 85.29 % had 6/18 or better UCVA (see *Table 3*). The mean UCVA was 0.367 log MAR (Snellen equivalent 20/46).

Of the 136 patients, the first postoperative day BCVA were: 20 (14.70 %) had 6/6, 56 (41.17 %) had 6/9, 48 (35.29 %) had 6/12, nine (6.61 %) had 6/18, one (0.73 %) had 6/24, and two (1.47 %) had 6/36. Cumulatively 55.88 % presented with 6/9 or better UCVA and 91.17 % had 6/12 or better UCVA (see *Table 4*). The mean BCVA was 0.226 (Snellen equivalent 20/33).

The most frequent postoperative complication encountered was transient corneal edema: nine out of 136 patients had mild corneal edema, four out of 136 patients had moderate corneal edema, and one out of 136 had severe corneal edema. All these cases recovered well with topical steroids within a week (see *Table 5*).

Discussion

Cataracts are the leading cause of blindness worldwide[1] and it accounts for 50 % of the world's blind. MSICS is already a proven technique for cataract extraction in terms of safety and efficacy. The outcomes following MSICS compared with phaco, which is the gold standard, suggests that it is a safe alternative. The advantages of MSICS as a low-cost, equally effective technique make it an attractive alternate for the developing world.[8,18,19] A prospective trial comparing 3.2 mm incisions with 5.5 mm incisions in Japan showed a difference in astigmatism of 0.3 D.[5] A study from Mumbai, India showed temporal and superotemporal tunnels to induce less astigmatism compared with superior tunnels for MSICS.[6] A study comparing endothelial cell loss and surgically induced astigmatism between ECCE, MSICS, and phaco showed induced astigmatism occurred slightly more in MSICS than phaco, but much less than ECCE. There was no significant difference in the endothelial cell loss between the three techniques.[7] The average astigmatism was 0.7 D in the phaco and 0.88 D in the MSICS (p=0.1) in the Nepal study.[8] In our study, all sizes and hardness nuclei were removed from 6 mm width tunnel using the intratunnel phacofracture method. The mean first postoperative day UCVA and BCVA log MAR were 0.367 (Snellen equivalent 20/46) and 0.23, respectively (Snellen equivalent 20/33). The surgical results obtained in our study compare favorably with those mentioned in the literature for MSICS. However, to the best of our knowledge; there are no prior reports of the first visual outcomes and complications in 6 mm MSICS using the intratunnel phacofracture technique. So a sub-6 mm scleral incision at the appropriate site is the major factor to attain visual outcomes similar to 3.2 mm incision phaco surgery. However, large nuclei remain the hurdle in MSICS. Various methods of nucleus size reduction are described in the literature; however, in these cases, maneuvers were performed inside the AC. In our method, phacofracture was performed inside the tunnel, so there were less chances of endothelium damage. There were few postoperative complications, like mild transient corneal edema at first postoperative day. Only one case had severe corneal edema. This subsided in a week. Drawbacks of the study are the retrospective study design. We recommend further studies to document results using 6 mm MSICS using intratunnel phacofracture technique.

Table 4: First Postoperative Best Corrected Visual Acuity

Visual Acuity	Patient Number (%)	Patient Cumulative Number (%)
6/6	20 (14.70)	20 (17.17)
6/9	56 (41.17)	76 (55.88)
6/12	48 (35.29)	124 (91.17)
6/18	9 (6.61)	133 (97.79)
6/24	1 (0.73)	134 (98.52)
6/36	2 (1.47)	136 (100)

Table 5: Details of First Postoperative Day Complications

Cataract Types	UCVA	BCVA	Complication
NS++++	6/24	6/12	Mild corneal edema
MSC	6/18	6/12	Mild corneal edema
Immature senile cataracts	6/18	6/12	Mild corneal edema
Posterior subcapsular cataract	6/18	6/12	Mild corneal edema
Posterior subcapsular cataract	6/24	6/12	Mild corneal edema
NS++++	6/18	6/12	Mild corneal edema
Immature senile cataracts	6/18	6/12	Mild corneal edema
Hypermature senile cataracts	6/24	6/18	Mild corneal edema
NS+++	6/18	6/12	Mild corneal edema
Hypermature senile cataracts	6/24	6/18	Moderate corneal edema
Hypermature senile cataracts	6/24	6/18	Moderate corneal edema
Hypermature senile cataracts	6/36	6/36	Moderate corneal edema
Posterior polar cataracts	6/24	6/18	Moderate corneal edema
Immature senile cataracts	6/36	6/36	Severe corneal edema

BVCA = best corrected visual acuity; NS = nuclear sclerosis; NS+ = nuclear sclerosis grade 1; NS++ = grade 2; NS+++ = grade 3; NS++++ = grade 4; UVCA = uncorrected visual acuity.

Conclusion

Six mm MSICS using the intratunnel phacofracture technique is a safe, effective, reproducible, and economical technique. It is an alternative to expensive phaco. ■

1. Thylefors B, Negrel AD, Pararajasegram R, Dadzie KY, Global data on blindness, *Bull World Health Organ,* 1995;73:115–21.
2. Venkatesh R, Muralikrishnan R, Balent LC, et al., Outcomes of high volume cataract surgeries in a developing country, *Br J Ophthalmol*, 2005;89:1079–83.
3. Natchiar G, *Manual small incision cataract surgery: An alternative technique to instrumental phacoemulsification*, Madurai: Aravind Publication, 2000.
4. Henning A, Kumar J, Yorston D, Foster A, Sutureless cataract surgery with nucleus extraction: Outcome of a prospective study in Nepal, *Br J Ophthalmol,* 2003;87:266–70.
5. Oshika T, Nagahara K, Yaguchi S, et al., Three year prospective randomized evaluation of intraocular lens implantation through 3.2 and 5.5 mm incisions, *J Cataract Refract Surg*,1998;24:509–14.
6. Gokhale NS, Sawhney S, Reduction in astigmatism in manual MSICS through change in astigmatism site, *Indian J Ophthalmol*, 2005;53:201–3.
7. George R, Rapauliha P, Sripriya AV, et al., Comparision of endothelial cell loss and surgically induced astigmatism following conventional extracapsular cataract surgery, manual small incision surgery and phacoemulsification, *Ophthal Epidemiol*, 2005;12:293–7.
8. Gogate PM, Kulkarni SR, Krishnaiah S, et al., Safety and efficacy of phacoemulsification compared with manual small incision cataract surgery by a randomized controlled clinical trial: Six weeks results, *Ophthalmology*, 2005;112:869–74.
9. Gogate PM, Wormald RP, Deshpande M, et al., Extracapsular cataract surgery compared with manual small incision cataract surgery in community eye care setting in Western India: A randomized controlled trial, *Br J Ophthalmol*, 2003;87:673–9.
10. Wormald RP, Phacoemulsification vs. small incision manual cataract surgery: An expert trial, *Am J Ophthalmol*, 2007;143:143–4.
11. Basti S, Vasavada AR, Thomas R, Padmanabhan P, Extracapsular cataract extraction: Surgical techniques, *Indian J Ophthalmol*, 1993;41:19–21.
12. Fry LL, The phacosandwich technique. In: Rozakis GW, Anis AY, et al., editors, *Cataract surgery: Alternative small incision techniques*, Thorofare, NJ: Slack Inc., 1990;71–110.
13. Bayramlar H, Cekic O, Totan Y, Manual tunnel incision extra capsular cataract extraction using the sandwich technique, *J Cataract Refract Surg*, 1999;25:312–5.
14. Kansas P, Phacofracture. In: Rozakis GW, Anis AY, et al., editors, *Cataract surgery: Alternative small incision techniques*, Thorofare, NJ: Slack Inc.; 1990;45–70.
15. Duch Mestres F, Mathieu A, Torres F, et al., Intra-operative complications of planned extra capsular cataract extraction versus manual nucleofragmentation, *J Cataract Refract Surg*, 1996;22:1113–5.
16. Hepsen IF, Cekic O, Bayramlar H, Totan Y, Small incision extracapsular cataract surgery with manual phaco trisection, *J Cataract Refract Surg*, 2000;26:1048–51.
17. Blumenthal M, Ashkenazi I, Fogel R, Assia EI, The gliding nucleus, *J Cataract Refract Surg*, 1993;19:435–7.
18. Gogate P, Deshpande M, Nirmalan PK, Why do phacoemulsification? Manual small-incision cataract surgery is almost as effective, but less expensive, *Ophthalmology*, 2007;114:965–8.
19. Ruit S, Tabin G, Chang D, et al., A prospective randomized clinical trial of phacoemulsification vs manual sutureless small-incision extracapsular cataract surgery in Nepal, *Am J Ophthalmol*, 2007;143:32–8.