

## Insight and Advancement in Hereditary Retinal Degenerations

Eric J Sigler<sup>1</sup> and John J Huang<sup>2</sup>

1. Chief Resident, Department of Ophthalmology and Visual Science, Yale University School of Medicine;
2. Associate Professor, Department of Ophthalmology and Visual Sciences, Director of Ocular Immunology and Uveitis and Director of Clinical Trials and Translational Research, Yale University

### Abstract

Hereditary retinal degenerations comprise a diverse group of inherited genetic defects in one or more retinal or retinal pigment epithelial cellular proteins. Traditionally, anatomic classification based on clinical and histopathological phenotype has been used to organise these disorders. In the modern era of advanced molecular biological techniques and genetic screening the current classification system may soon become obsolete, due to the fact that significant overlap between different retinal degenerations has been observed, resulting from variation in gene expression, common genetic pathways and variable inheritance patterns. In this article, we review the various clinical disease entities, emphasise a genetic classification system and give special attention to recent advances in molecular biology and gene therapy.

### Keywords

Retinitis pigmentosa, Leber congenital amaurosis, pattern dystrophy, Stargardt's disease, Best vitelliform dystrophy, X-linked retinoschisis

**Disclosure:** The authors have no conflicts of interest to declare.

**Acknowledgement:** This research is supported by grants from Research to Prevent Blindness Challenge Grant, Allergan Horizon Grant and Connecticut Lions Eye Research Foundation.

**Received:** 19 October 2010 **Accepted:** 20 February 2011 **Citation:** *European Ophthalmic Review*, 2011;5(1):74–77 DOI: 10.17925/EOR.2011.05.01.74

**Correspondence:** John J Huang, Assistant Professor, Department of Ophthalmology and Visual Sciences, Director of Uveitis Service, Faculty of Vitreo-Retina Service and Director of Clinical Trials and Translational Research, Yale University, 40 Temple Street, Suite 3D, New Haven, CT 06510, US. E: john.huang@yale.edu

Retinitis pigmentosa (RP) is a group of disorders whose main clinical features include diffuse photoreceptor dysfunction, diminished electroretinogram (ERG) and progressive visual field loss. The disorders affect approximately one in 5,000 people worldwide.<sup>1</sup> Clinical features often include peripheral retinal pigment epithelial atrophy, 'bone spicule' pigment clumping, waxy optic disk pallor and arteriolar attenuation. Patients often experience nyctalopia as an early symptom followed by progressive visual field loss and eventual central vision loss. Pigmented vitreous cells, posterior subcapsular cataract and cystoid macular oedema have also been associated with RP.

Interestingly, RP has been associated with all forms of mendelian inheritance patterns. It appears that autosomal dominant is the most common identifiable inheritance pattern, present in approximately 15–25% of cases. Autosomal recessive inheritance is also common, as is the absence of any family history. X-linked and mitochondrial variants have also been described. There are over 100 genes that have been identified and implicated in the disease.<sup>1,2</sup> These defects are organised by chromosome in the RetNet subdivision of the Online Mendelian Inheritance in Man database (OMIM™). Many mutations, including the first gene discovered to cause RP, are defects in rhodopsin (RHO), the pan-rod photopigment. Many novel genetic defects in products involved in the visual pigment transduction pathway continue to be described. Among these are RHO, RDS/peripherin, pre-messenger RNA (mRNA) processing factor 31 (PRPF31), RP31, Prominin 1 (PROM1), RP GTPase regulator (RPGR) and RP25. In addition, there is a wide range of disease severity and phenotypic expressivity linked to specific mutations. This is especially evident in analysis of the

*RDS/peripherin* gene<sup>3</sup> located on chromosome 6p, whose product localises to a protein present in the peripheral outer rod segment. Various mutations may occur with a wide range of phenotypes, ranging from pattern dystrophies to Stargardt's disease, to RP, even within the same family.

There has been no proven effective treatment for RP. Observations that patients taking vitamin A may have a slower decline in ERG and photoreceptor function led to a randomised controlled trial investigating vitamin A and E supplementation.<sup>3,4</sup> The results demonstrated a role for vitamin A supplementation in retarding ERG amplitude loss but no obvious significant effect on vision and visual field loss. A subsequent analysis of patients deemed to have more accurate visual field measurement demonstrated slower rates of visual field loss in those using vitamin A.<sup>5,6</sup> Larger trials with longer follow-up are needed to completely assess the efficacy of this treatment. However, many retinal specialists recommend 15,000IU of vitamin A palmitate in patients with RP, excluding women who may be pregnant or are planning to become pregnant.

The future of RP treatment will rest upon pharmacogenetic and molecular biological techniques for replacing defective genes, restoring the function of defective proteins and preventing abnormal photoreceptor function; with the use of implantable electrical devices in advanced cases. Gene therapy has undergone many recent advances, particularly involving delivery of functional genes through viral vectors, especially the adeno-associated viral vector (AAV),<sup>7,8</sup> which has been shown to efficiently transmit DNA to both

photoreceptor and retinal pigment epithelium (RPE) cells.<sup>7-9</sup> Several essential characteristics of this therapy must be considered in order to evaluate therapeutic feasibility.<sup>10</sup> They include: must be a monogenic loss-of-function mutation (which comprises only a small fraction of RP pathology), the specific genetic defect must be identifiable, the transgene vector must have low immunogenicity and the expression of the transgene must occur long term. Despite these obstacles, significant progress has been made in this area. In mice, AAVV delivery via subretinal injection has been used to prevent expression of non-functional RHO and deliver functional RHO, resulting in improved ERG response.<sup>11</sup> Another strategy that has been investigated is the use of vectors to photosensitize cells in the retina other than photoreceptors. Intravitreal injection of AAVV in rats has shown to be capable of inducing expression of an additional opsin, channelopsin 2 (CHOP2), in retinal ganglion cells, leading to an improved ERG response. As the vast array of genetic defects and expressions of RP are elucidated along with advancements in molecular biological techniques, gene delivery and protein-protein interaction will no doubt become a major player in the future of treatment.

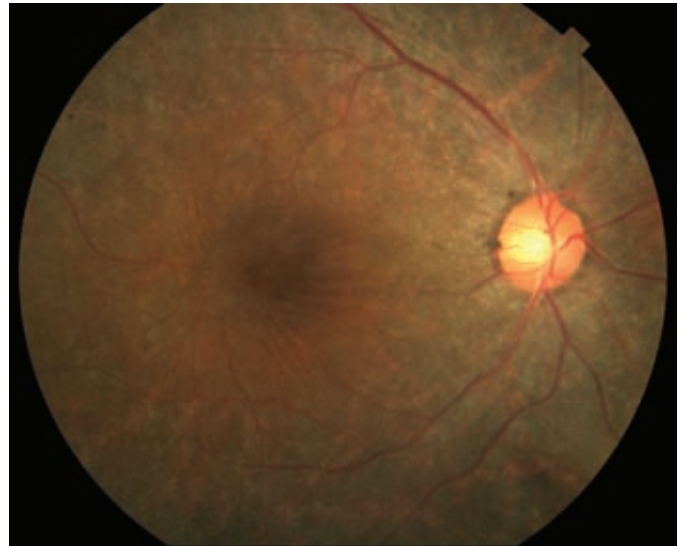
Furthermore, significant progress is being made in the field of retinal prosthesis.<sup>12-16</sup> These devices include some method of transmitting electrical signals to remaining inner retinal cells in patients with damaged photoreceptors. The feasibility of this technology was determined by showing that significant proportions of the inner retinal elements, namely ganglion cells, remain histologically intact, even in patients with significant photoreceptor loss from RP.<sup>14</sup> The first US clinical trial was performed by Optobionics with an artificial silicone retina consisting of a subretinal microphotodiode array.<sup>15</sup> The device was found to be safe, with many patients developing evidence of improved visual function. Currently, the most advanced device employs an epiretinal microarray sponsored by Second Sight Medical Products and is currently in phase II clinical trials. This employs a tiny camera mounted on the patient's eyeglasses that transmits a digital image to the intraocular microarray, which in turn transmits the image to electric impulses that can be detected by the retina (see *Figure 1*).<sup>16</sup>

### Leber Congenital Amaurosis

Leber's congenital amaurosis (LCA) is a group of visual disorders characterised by infantile onset, recessive inheritance and severe visual loss secondary to severe rod-cone dysfunction.<sup>17,18</sup> Classically, these diseases have been classified as infantile-onset RP. The incidence is rare, occurring in between one in 30,000 and one in 80,000 live births. Affected children develop severe visual loss and wandering nystagmus and often demonstrate the oculo-digital reflex. Patients typically have amaurotic pupils and absent ERG response.<sup>19</sup> Early in the disease course, the fundus often appears normal. Many patients eventually develop pigmentary retinopathy and, rarely, bone spicule formation. Cataract and keratoconus may be associated. At least 14 gene mutations have been identified and are thought to account for approximately 70% of cases.<sup>20-23</sup> These genes are involved in phototransduction, structural proteins, the vitamin A cycle and outer photoreceptor segment phagocytosis. Affected patients typically have visual acuity ranging from 20/200 to no light perception. Visual acuity usually remains stationary or shows slow progressive decline.

Although the disorder is heterogenous in terms of underlying defect, molecular diagnosis is important for genetic counselling and possible treatment.<sup>21,24</sup> In the pre-genomic era, there were no effective treatments for the disorder. Recently, two clinical trials have investigated the use

**Figure 1: Retinitis Pigmentosa with Diffuse Peripheral Pigmentary Alteration, Retinal Vascular Attenuation, Cystoid Macular Oedema and Mild Optic Nerve Pallor**



of a recombinant AAVV-delivered coding sequence of *RPE65*, a gene expressed by the RPE and necessary for the visual pigment cycle.<sup>25,26</sup> *RPE65* is normally required for the regeneration of 11-*cis* retinal for phototransduction. LCA2 is caused by mutations in the 65Da gene product, which is an RPE-specific protein. Initial evidence for the use of this therapy has come about through observations that while photoreceptors are dysfunctional from birth, photoreceptor cell death occurs later in the disease process. In addition, a naturally occurring animal model (Swedish Briard Dog) has been used to show improved visual function with subretinal delivery of AAVV *RPE65*.<sup>23-27</sup> Interestingly, this method of delivery, using complementary DNA (cDNA) delivered via viral vector, has been shown to cause sustained expression of the gene product in animal models. Bainbridge et al. investigated three young adult patients by administering subretinal AAVV *RPE65*.<sup>28</sup> Of these, one patient developed evidence of visual improvement, measured by microperimetry and dark adapted perimetry as well as subjective tests of visual mobility. There were no severe untoward complications of transvitreal/subretinal delivery of the vector. There were, however, no significant visual changes in acuity or Goldmann perimetry. Maguire et al. performed a similar trial with subretinal delivery of AAVV *RPE65* to three young adults with LCA2.<sup>29</sup> All patients developed improved pupillary responses, decreased amplitude of nystagmus and improved subjective visual acuity. One patient developed a macular hole that was thought to be related to a pre-existing epiretinal membrane that was not removed prior to surgery. Both of these trials, although unmasked and non-placebo-controlled, represent steps forward in treatment in a previously untreatable blinding retinal disorder. With longer follow-up, larger trials and improved techniques, the efficacy of this treatment will continue to be elucidated. As described above, retinal prostheses may also be a feasible option in the near future for patients with LCA.

### X-linked Retinoschisis

X-linked retinoschisis, or inherited splitting of the foveal nerve fibre layer, is the leading cause of macular degeneration in young males, with a prevalence between one in 15,000 and one in 30,000 males.<sup>30,31</sup> The disorder follows typical X-linked inheritance with no male-male transmission, carrier females and affected males.<sup>32</sup> The disorder is

caused by several identified mutations in retinoschisin, a retinal protein product of the gene *RS1*.<sup>33–35</sup> *RS1* maps to the distal arm of the X-chromosome (Xp22). Retinoschisin is a secreted protein that likely participates in cell–cell interaction. Genetic defects cause failure of secretion or failure of extracellular polymerisation and cell adhesion. Clinically, the disorder has a heterogenous set of features. There appears to be a bimodal distribution of age at diagnosis.<sup>36</sup> Patients may present in infancy with squinting and nystagmus with severe vision loss or at school age with decreased visual acuity. Interestingly, there appears to be no correlation with specific genetic mutation and disease severity, even within affected families. Visual acuity can range from 20/20 to severe visual loss.<sup>37,38</sup> Physical exam discloses a wheel-like pattern of foveal retinal splitting often extending to the retinal periphery. These findings may be dramatic in childhood but typically become less obvious with time as schisis cavities regress, often leaving a pattern of hyperpigmentation over time. Diagnosis is suspected with typical fundus features as well as the presence of diminished B-wave amplitude on ERG with relatively preserved A wave, reflecting damage to inner retinal elements.

The disease course may be variable, but typically demonstrates variable visual loss that is stable initially, with eventual decline beginning in the fourth to fifth decade of life.<sup>30,31,37,38</sup> Furthermore, additional retinal complications such as macular traction/detachment, vitreous haemorrhage and peripheral retinal breaks may occur.<sup>39</sup> Genetic testing is available and is an important component of diagnosis and genetic counselling for patients and their families. Low vision aids and appropriate refraction are major elements for supportive treatment. A recent report described the use of topical dorzolamide, which appears useful in decreasing cystic retinal spaces and gives possible improvement in vision.<sup>40</sup> The usefulness of this treatment modality requires further investigation and follow-up.

Genetic therapy for X-linked retinoschisis may be feasible, but will have some unique challenges. Mouse models of the disorder exist and have recently been used to attempt gene-delivery-based rescue.<sup>41,42</sup> The use of AAV gene replacement has been shown to be capable of improving B-wave ERG. This treatment modality may have some role in treatment, but will likely apply to eyes with early diagnosis with preserved retinal structural elements. Time and experience will tell whether this animal-modelled treatment may extrapolate to human disease.

## Stargardt's Disease

Stargardt's disease, or fundus flavimaculatus, is an autosomal, recessively inherited form of macular degeneration and is the most common macular dystrophy in patients under 50 years of age.<sup>43</sup> The disorder affects approximately one in 10,000 individuals. The most common genetic defect is in *ABCA4* on chromosome 1p, whose product is the ATP-binding cassette transporter protein.<sup>44</sup> The protein localises to rod outer segments. Stargardt's disease can be highly variable in terms of clinical features. As with several other genes implicated in hereditary retinal dystrophies, patients with deficiencies in *ABCA4* can display Stargardt's phenotype, an RP-like picture, or pattern dystrophy even within the same family.<sup>44–47</sup> Several mutations have and continue to be identified and there is some evidence that different mutations may be associated with distinct phenotypes and disease severity.<sup>44–46</sup>

Patients are typically young and present with gradual decline in visual acuity ranging from mild impairment to visual acuity of 20/200. Physical examination reveals loss of foveolar reflex, deep yellow 'pisciform' subretinal deposits and pathognomonic dark choroid on fluorescein angiogram.<sup>46–48</sup> The angiographic finding is related to diffuse blockage by excess RPE lipofuscin accumulation.<sup>46</sup> Visual field testing is often normal early in the disease course but progresses to central scotoma.<sup>47</sup> ERG is typically normal early in the disease but may progress to prolonged implicit times or generalised depression of amplitude late in the disease course.<sup>48</sup> Histopathological studies support the notion that the underlying genetic defect leads to the accumulation of lipofuscin,<sup>49</sup> a metabolic waste product and subsequent retinal and RPE dysfunction as a result of photoreceptor cell loss.<sup>49–50</sup>

Although genetic advances are being made in understanding Stargardt's disease, the molecular mechanisms by which the disease manifests are not well understood. There is currently no proven treatment; further research will be needed to investigate the feasibility of gene therapy for Stargardt's disease.

The classification, diagnosis and now treatment of hereditary retinal degeneration have changed significantly in our era of molecular biology and genetic evaluation. The genetic testing allows for accurate diagnosis, while providing information for counselling for the patient and the family. Advances in molecular biology have provided potential treatment through gene and drug therapy. ■

1. Weleber RG, Gregory-Evans K, Retinitis pigmentosa and allied disorders. In: Ryan SJ (ed.), *Retina*, St Louis: Mosby, 2001;362–470.
2. Leroy BP, Kailasanathan A, De Laey J-J, et al., Intrafamilial Phenotypic Variability in families with RDS mutations: exclusion of ROM1 as a genetic modifier for those with Retinitis Pigmentosa, *Br J Ophthalmol*, 2007;91:89–93.
3. Berson EL, Treatment of retinitis pigmentosa with vitamin A, *Digit J Ophthalmol*, 1998;4:1–4.
4. Berson EL, Rosner B, Sandberg MA, et al., Vitamin A supplementation for retinitis pigmentosa, *Arch Ophthalmol*, 1993;111:1456–9.
5. Berson EL, Rosner B, Sandberg MA, et al., A randomized trial of vitamin A and vitamin E supplementation for retinitis pigmentosa, *Arch Ophthalmol*, 1993;111:761–72.
6. Massof RW, Finkelstein D, Supplemental vitamin A retards loss of ERG amplitude in retinitis pigmentosa, *Arch Ophthalmol*, 1993;111:751–4.
7. Smith A, Bainbridge JW, Ali R, Prospects for retinal gene replacement therapy, *Trends Genet*, 2009;25(4):156–65.
8. Bainbridge JW, et al., Gene therapy progress and prospects: the eye, *Gene Ther*, 2006;13:1191–7.
9. Surace EM, Auricchio A, Versatility of AAV vectors for retinal gene transfer, *Vision Res*, 2008;48:353–9.
10. O'Reilly M, Palfi A, Chadderton N, et al., RNA interference-mediated suppression and replacement of human rhodopsin in vivo, *Am J Hum Genet*, 2007;81:127–35.
11. Tomita H, Sugano E, Yawo H, et al., Restoration of visual response in aged dystrophic RCS rats using AAV mediated Channelopsin-2 gene transfer, *Invest Ophthalmol Vis Sci*, 2007;48:446–54.
12. Chader GJ, Weiland J, Humayun MS, Artificial vision: needs, functioning and testing of retinal prosthesis, *Prog Brain Res*, 2009;175:317–32.
13. Stone J, Barlow W, Humayun M, de Juan Jr. E, Milam A, Morphometric analysis of macular photoreceptors and ganglion cells in retinas with retinitis pigmentosa, *Arch Ophthalmol*, 1992;110:1634–9.
14. Santos A, Humayun M, de Juan Jr. E, et al., Preservation of the inner retina in retinitis pigmentosa. A morphometric analysis, *Arch Ophthalmol*, 115;1997:511–5.
15. Peachey N, Chow A, Subretinal implantation of semiconductor-based photodiodes: progress and challenges, *J Rehabil Res Devel*, 1999;36:371–6.
16. Humayun M, Intraocular retinal prosthesis, *Trans Am Ophthalmol Soc*, 2001;99:271–300.
17. Hollander AJ, Roepman R, et al., Leber congenital amaurosis: genes, proteins and disease mechanisms, *Prog Retina Eye Res*, 2008;27(4):391–419.
18. Leber T, Über retinitis pigmentosa und angeborene amaurose, *von Graefes Arch Ophthalmol*, 1869;15:1–25.
19. Franceschetti A, Dieterle P, Diagnostic and prognostic importance of the electroretinogram in tapetoretinal degeneration with reduction of the visual field and hemeralopia, *Confin Neurol*, 1954;14:184–6.
20. Koenekoop RK, An overview of Leber congenital amaurosis: a model to understand human retinal development, *Surv Ophthalmol*, 2004;49:379–98.
21. Stone EM, Leber congenital amaurosis—a model for efficient genetic testing of heterogeneous disorders: LXIV Edward Jackson Memorial Lecture, *Am J Ophthalmol*, 2007;144:791–811.
22. Paunescu K, Wabbel B, Preisling M, et al., Longitudinal and cross-sectional study of patients with early onset severe retinal dystrophy associated with RPE 65 mutations, *Graefes Arch Clin Exp Ophthalmol*, 2005;243:417–26.
23. Acland GM, Aguirre GD, Ray J, et al., Gene therapy restores vision in a canine model of childhood blindness, *Nat Genet*, 2001;28:92–5.
24. Narfström K, Katz ML, Bragadottir R, et al., Functional and structural recovery of the retina after gene therapy in the RPE65 null mutation dog, *Invest Ophthalmol Vis Sci*, 2003;44:1663–72.
25. Narfström K, Katz ML, Ford M, et al., In vivo gene therapy in young and adult RPE65<sup>-/-</sup> dogs produces long-term visual improvement, *J Hered*, 2003;94:31–7.
26. Le Meur G, Stieger K, Smith AJ, et al., Restoration of vision in RPE65-deficient Briard dogs using an AAV serotype 4 vector that specifically targets the retinal pigmented epithelium, *Gene Ther*, 2007;14:292–303.
27. Aguirre GK, Komáromy AM, Cideciyan AV, et al., Canine and human visual cortex intact and responsive despite early retinal blindness from RPE65 mutation, *PLoS Med*, 2007;4:e230.

28. Bainbridge J, Smith AJ, Barker S, et al., Effect of gene therapy on visual function in Leber's congenital amaurosis, *N Engl J Med*, 2008;358:2231-9.
29. Maguire AM, Simonelli F, Pierce AA, et al., Safety and efficacy of gene transfer for Leber's congenital amaurosis, *N Engl J Med*, 2008;358:2240-8.
30. Forsius H, Krause U, Helve J, et al., Visual acuity in 183 cases of X-chromosomal retinoschisis, *Can J Ophthalmol*, 1973;8:385-93.
31. De La Chappelle A, Alitalo T, Forsius H, X-linked juvenile retinoschisis, In: Wright AF, Jay B (eds), *Molecular Genetics of Inherited Eye Disorders*, Switzerland: Harwood Academic Publishers, 1994;339-57.
32. Sauer CG, Gehrig A, Warneke-Wittstock R, et al., Positional cloning of the gene associated with X-linked juvenile retinoschisis, *Nat Genet*, 1997;17:164-70.
33. Grayson C, Reid SN, Ellis JA, et al., Retinoschisin, the X-linked retinoschisis protein, is a secreted photoreceptor protein, and is expressed and released by Weri-Rb1 cells, *Hum Mol Genet*, 2000;9:1873-9.
34. George ND, Yates JR, Bradshaw K, Moore AT, Infantile presentation of X linked retinoschisis, *Br J Ophthalmol*, 1995;79:653-7.
35. Pimenides D, George ND, Yates JR, et al., X-linked retinoschisis: clinical phenotype and RS1 genotype in 86 UK patients, *J Med Genet*, 2005;42:e35.
36. George ND, Yates JR, Moore AT, Clinical features in affected males with X-linked retinoschisis, *Arch Ophthalmol*, 1996;114:274-80.
37. Deutmann AF, *The Hereditary Dystrophies of the Posterior Pole of the Eye*, Assen: Van Gorcum, 1971.
38. Kellner U, Brummer S, Foerster MH, Wessing A, X-linked congenital retinoschisis, *Graefes Arch Ophthalmol*, 1990;228:432-7.
39. Regillo CD, Tasman WS, Brown GC, Surgical management of complications associated with X-linked retinoschisis, *Arch Ophthalmol*, 1993;111:1080-6.
40. Apushkin MA, Fishman GA, Use of dorzolamide for patients with X-linked retinoschisis, *Retina*, 2006;26:741-5.
41. Zeng Y, Takada Y, Kjellstrom S, et al., RS-1 gene delivery to an adult Rs1h knockout mouse model restores ERG b-wave with reversal of the electronegative waveform of X-linked retinoschisis, *Invest Ophthalmol Vis Sci*, 2004;45(9):3279-85.
42. Min SH, Molday LL, Seeliger MW, et al., Prolonged recovery of retinal structure/function after gene therapy in an Rs1h-deficient mouse model of X-linked juvenile retinoschisis, *Mol Ther*, 2005;12:644-51.
43. Blacharski PA, Newsome DA (eds), *Fundus flavimaculatus. Retinal Dystrophies and Degenerations*, New York: Raven Press, 1988;135-59.
44. Bonin P, Passot M, De Laey JJ (eds), Triolaire-Colton M-Th, Le signe du silence choroidien dans les degenerences tapetoretiniennes posterieures. International Symposium on Fluorescein Angiography, *Doc Ophthalmol Proc Ser*, 1976;9:461-3.
45. Eage Jr RC, Lucier AC, Bernardino Jr VB, Yanoff M, Retinal pigment epithelial abnormalities in fundus flavimaculatus. A light and electron microscopic study, *Ophthalmol*, 1980;87:1189-200.
46. Valverde D, Riviero-Alvarez R, Aguirre-Lamban J, et al., Spectrum of the ABCA4 gene mutations implicated in severe retinopathies in Spanish patients, *Invest Ophthalmol Vis Sci*, 2007;48:985-90.
47. Beit-Ya'acov A, Mizrab-Meisssonier L, Obolensky A, et al., Homozygosity for a novel ABCA4 founder splicing mutation is associated with progressive and severe Stargardt-like disease, *Invest Ophthalmol Vis Sci*, 2007;48:4308-14.
48. Sandberg MA, Jacobson SG, Berson EL, Foveal cone electroretinograms in retinitis pigmentosa and juvenile macular degeneration, *Am J Ophthalmol*, 1979;88:702-7.
49. Birnbach CD, Jarvelainen M, Possin DE, Milam AH, Histopathology and immunocytochemistry of the neurosensory retina in fundus flavimaculatus, *Ophthalmol*, 1994;101:1211-9.
50. Delori FC, Staurenghi G, Arend O, Dorey CK, *In vivo* measurement of lipofuscin in Stargardt's disease—fundus flavimaculatus, *Invest Ophthalmol Vis Sci*, 1995;36:2327-31.