

## Combination Therapy for Wet Age-related Macular Degeneration

Albert J Augustin and Stephan Scholl

Department of Ophthalmology, Karlsruhe

### Abstract

Increasing appreciation of the complexity of the wet type of age-related macular degeneration (AMD) has made combination therapy an area of current intense interest. Administered in dual or triple combinations, the current therapeutic mainstays – corticosteroids, verteporfin photodynamic therapy (V-PDT) and inhibitors of vascular endothelial growth factor (VEGF) – have more potential to successfully treat the various pathogenetic factors contributing to wet AMD than any single-therapy approach. The different mechanisms of action involved in combination therapy are intended to reduce inflammation, eradicate current and future choroidal neovascularisation and lessen VEGF expression. Evidence from clinical trials demonstrates visual acuity benefits, lower re-treatment rates and longer treatment-free intervals with combination therapies compared with monotherapies. This article summarises the rationale and the clinical evidence that support the use of double and triple combination therapy in wet AMD.

### Keywords

Age-related macular degeneration, wet type, intravitreal anti-VEGF agents, choroidal neovascularisation, intravitreal corticosteroids, verteporfin photodynamic therapy

**Disclosure:** The preparation of this report was supported by QLT Inc.

**Acknowledgement:** The author wishes to thank Margaret E Phelan for assistance in preparing this article for publication.

**Received:** 19 October 2009 **Accepted:** 24 November 2009 *DOI: 10.17925/EOR.2009.03.02.98*

**Correspondence:** Albert J Augustin, Augenklinik, Moltkestrasse 90, 76133 Karlsruhe, Germany. E: albertjaugustin@googlemail.com

### Wet Age-related Macular Degeneration – A Multifactorial Disease

Once considered to be primarily a vascular disease arising from angiogenesis, choroidal neovascularisation (CNV) secondary to age-related macular degeneration (AMD), or wet AMD, is now viewed as a complex multifactorial disease with numerous non-vascular components. As proposed by Spaide, the vascular component consists of endothelial cells, circulating endothelial progenitor cells and pericytes. The extravascular component consists of inflammatory cells, including retinal pigment epithelial (RPE) cells, lymphocytes, macrophages and granulocytes.<sup>1</sup>

As shown in *Figure 1*, the cascade of wet AMD begins with oxidative stress of the RPE and progresses to RPE dysfunction, followed by release of inflammatory and fibrosis mediators and pro-angiogenic factors, especially vascular endothelial growth factor (VEGF), inappropriate growth of new vessels, exudation, haemorrhage and, ultimately, disciform scar formation.<sup>2-8</sup>

### The Rationale for Combination Therapy

The current therapeutic mainstays to treat wet AMD are intravitreal corticosteroids, verteporfin photodynamic therapy (V-PDT) and intravitreal anti-VEGF agents. Corticosteroids treat and prevent inflammation, block the upregulation of VEGF, narrow the gaps between endothelial cells in the capillary walls and limit fibrosis, which in turn minimises retina scarring.<sup>9,10</sup> V-PDT, a two-stage process involving administration of verteporfin for injection and non-thermal red light,

targets the vascular component of wet AMD by producing local damage to the neovascular endothelium, which results in vessel occlusion.<sup>11</sup> Anti-VEGF drugs target angiogenesis, which has been identified as a leading culprit in neovascular and exudative eye diseases.<sup>12</sup>

In the TAP clinical trials, V-PDT was shown to reduce the risk of further vision loss in patients with predominantly classic subfoveal CNV secondary to AMD,<sup>13</sup> with beneficial outcomes sustained at two and five years.<sup>14,15</sup> At one- and two-year follow-up, improved visual acuity (VA) was shown in some patients.<sup>16</sup> In the landmark ANCHOR and MARINA clinical trials, the anti-VEGF agent ranibizumab, injected intravitreally on a monthly basis, was shown to improve VA, with benefit maintained at 24 months.<sup>17,18</sup> These results were the first meaningful vision improvements in significant numbers of patients with wet AMD. They also stimulated considerable off-label use of intravitreal bevacizumab,<sup>19-21</sup> which is derived from the same recombinant humanised monoclonal antibody as ranibizumab.<sup>22</sup>

However, as monotherapies, steroids, V-PDT and anti-VEGF agents cannot treat the multifactorial pathogenesis of wet AMD. Thus, combination therapies are now of intense interest. Their different mechanisms of action have greater potential to successfully treat the various pathogenetic factors contributing to wet AMD than any monotherapy. By utilising different and quite possibly complementary or synergistic mechanisms of action, combination therapy is intended to reduce inflammation, eradicate current CNV, prevent future CNV and lessen VEGF expression. It is highly likely that retina specialists

will increasingly use combination therapy to treat patients with ocular angiogenesis, including wet AMD.

### The Evolution of Combination Therapies

Combination therapy for wet AMD began in earnest after V-PDT was approved for use in 2000. The first dual combinations involved V-PDT plus intravitreal triamcinolone. When the anti-VEGF agent pegaptanib became the first agent in its class approved for use, studies of combination therapies of this drug plus a steroid or V-PDT followed. Subsequent availability of the anti-VEGF agent ranibizumab generated considerable excitement because, as noted above, it demonstrated meaningful vision benefit for the first time in patients with wet AMD. Combination therapy with ranibizumab or the similar agent bevacizumab and a steroid, V-PDT, or both, followed.

Therefore, the treatment options have expanded considerably over the past decade. Currently, combination therapies including ranibizumab or bevacizumab plus V-PDT with and without a steroid are being intensely investigated. The overall goal is to produce vision benefits comparable to those produced with ranibizumab monotherapy but with a reduced need for re-treatment. A brief review of the clinical evidence that supports combination therapy in wet AMD follows.

### Combination Therapies

#### Verteporfin Photodynamic Therapy plus Intravitreal Triamcinolone

Overall results from two prospective trials favoured this combination over V-PDT monotherapy. Specifically, combination therapy was associated with fewer lines of vision lost and a lower rate of moderate vision loss at one year compared with V-PDT monotherapy.<sup>23</sup> In addition to maintaining VA, combination therapy was also significantly better than V-PDT monotherapy in reducing lesion size and foveal thickness.<sup>24</sup> Notably, there was a significantly lower re-treatment rate with combination therapy versus monotherapy ( $p=0.04$ ).<sup>24</sup>

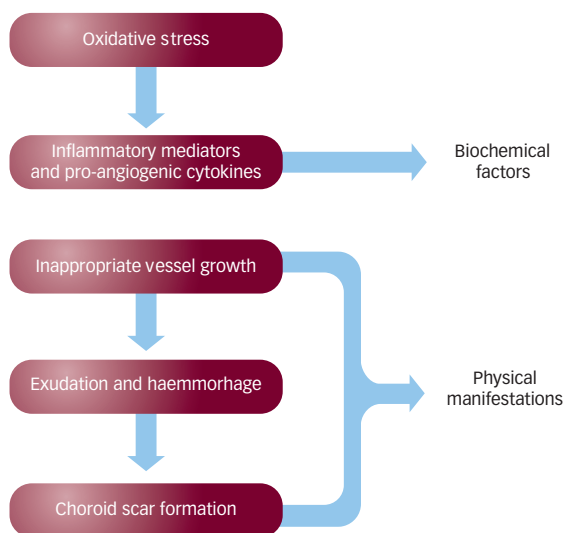
#### Verteporfin Photodynamic Therapy plus Anti-vascular Endothelial Growth Factor Therapies with or without Steroids

With the availability of anti-VEGF drugs, clinical trials of dual combinations – V-PDT plus an anti-VEGF agent – and triple combinations – V-PDT plus an anti-VEGF agent plus a steroid – have been carried out or are now under way (see *Table 1*). Dual combination trials comparing V-PDT plus ranibizumab with either V-PDT or ranibizumab monotherapy include FOCUS, PROTECT, MONT BLANC and DENALI.

The results of FOCUS, a multicentre, randomised, single-blind, controlled clinical trial, showed better efficacy with V-PDT plus ranibizumab than with V-PDT alone.<sup>25</sup> At 12 months, 95 of the 105 (91%) V-PDT plus ranibizumab-treated patients and 38 of the 56 (68%) V-PDT monotherapy patients had lost fewer than 15 letters from baseline VA ( $p<0.001$ ). Patients treated with combined therapy also required less V-PDT re-treatment. Ranibizumab was associated with an increased risk of serious intraocular inflammation, possibly related to the use of an early formulation of this agent, yet affected patients on average still experienced VA benefit.<sup>25</sup>

In the prospective, multicentre PROTECT study, V-PDT was administered at baseline and, if fluorescein leakage was present, at months three, six

**Figure 1: The Cascade of Wet Age-related Macular Degeneration**



and nine; ranibizumab was administered at baseline and at months one, two and three. Combination therapy was given on the same day. At nine months all lesions were inactive and all cases of macular oedema and subretinal fluid had resolved. Although this study was small (32 patients), it showed that same-day administration of V-PDT plus ranibizumab was not associated with severe vision loss or severe ocular inflammation.<sup>26</sup> In a subanalysis of the PROTECT trial, the effects of the above-described regimen on retinal anatomy, choroidal perfusion and visual function were assessed. The vascular effects were immediate photothrombosis of the CNV and surrounding choroid. Retinal sensitivity also improved immediately and continued over time, although some choroidal malperfusion remained.<sup>27</sup> As noted, this study and its subanalysis were small in size and non-comparative; nevertheless, the results showed the safety and efficacy of combination therapy given on the same day, which would certainly be more convenient to patients and potentially lower the risk of retinal toxicity.

MONT BLANC is a 24-month randomised, double-blind, European multicentre trial comparing V-PDT plus ranibizumab with ranibizumab alone in 255 subjects. Standard-fluence V-PDT (or placebo) was administered at baseline and then at intervals of at least three months as required, based on pre-defined re-treatment criteria. Ranibizumab was administered as three 'loading doses' followed by monthly treatment as needed based on pre-defined re-treatment criteria.<sup>28</sup> In a preliminary analysis of one-year results, mean VA improvement from baseline in the combination therapy group (2.5 letters) was shown to be non-inferior to that in the ranibizumab monotherapy group (4.4 letters). The percentage of patients with a three-month treatment-free interval after the last loading dose was similar (96 and 92% in the combination and ranibizumab monotherapy groups, respectively). *Post hoc* analysis showed that 85% of patients in the combination therapy group, compared with 72% in the ranibizumab monotherapy group, had a treatment-free interval of at least four months. Median time to first re-treatment was extended by approximately one month in the combination group (month six) compared with the monotherapy group (month five). There were no unexpected safety findings and the adverse event incidence was similar between groups.<sup>28</sup> As noted, this is a preliminary analysis; final results are awaited before firm conclusions can be drawn.

**Table 1: Randomised Controlled Clinical Trials of Dual and Triple Combination Therapies**

Trial	Treatment	Main Outcome Results	Comments
FOCUS	V-PDT + ranibizumab versus V-PDT monotherapy	Loss of <15 letters from baseline: p<0.001 for PDT + ranibizumab versus PDT monotherapy	Less V-PDT retreatment was required in patients treated with combination therapy
MONT BLANC	V-PDT + ranibizumab versus ranibizumab monotherapy	Combination therapy non-inferior to ranibizumab monotherapy in mean change from baseline VA and proportion of patients with at least a 3-month treatment-free interval after month 2	This is a preliminary analysis of 1-year results from a 2-year trial
DENALI	Ranibizumab + standard-fluence V-PDT versus ranibizumab + reduced-fluence V-PDT versus ranibizumab monotherapy	Change from baseline in BCVA at month 12 and treatment-free interval of at least 3 months until month 12	The 1-year results of this 2-year trial are expected in 2010
RADICAL	V-PDT+ ranibizumab ± dexamethasone versus ranibizumab monotherapy	Fewer re-treatments with combination therapies than with ranibizumab monotherapy, and similar VA outcomes among all treatment groups	This is a preliminary analysis of 1-year results from a 2-year trial
PDEX II	V-PDT + ranibizumab + dexamethasone versus ranibizumab monotherapy	Change in VA at 1 year	Results expected at end of 2009

BCVA = best corrected visual acuity; VA = visual acuity; V-PDT = verteporfin photodynamic therapy.

DENALI is a two-year multicentre, controlled study in which approximately 300 patients were randomised to receive either same-day ranibizumab plus standard-fluence V-PDT, same-day ranibizumab plus reduced-fluence V-PDT or ranibizumab monotherapy.<sup>29</sup> Reduced-fluence V-PDT is of interest because it may have effects on CNV closure that are equivalent to standard fluence therapy, but with a less detrimental effect on the choroidal vasculature.<sup>30</sup> In the first two DENALI treatment groups, ranibizumab is given at baseline and months one and two, and then as needed; in the third group, ranibizumab is administered monthly for the first year and as needed for the second year. V-PDT will be administered at baseline and then every three months as needed. Monthly follow-up will consist of VA and optical coherence tomography (OCT) assessments, with re-treatment based on OCT findings. One-year results are expected in 2010.<sup>29</sup>

The combination of V-PDT plus bevacizumab is also of interest. Lazic et al. gave V-PDT, bevacizumab or both in combination to 165 patients. At one month, there was increased VA and fewer re-treatments with combination therapy than with either agent alone, with these benefits maintained at three months. Each treatment significantly reduced central foveal thickness (p<0.0001 for all three-month versus baseline comparisons). Three pigment epithelial tears (all in the bevacizumab group), 12 posterior vitreous detachments (four in the combination group and eight in the bevacizumab group) and seven cataract progressions (three in the combination group and four in the bevacizumab group) were noted.<sup>31</sup>

Combination therapy with pegaptanib has also been studied,<sup>32,33</sup> but this drug has been largely replaced by ranibizumab and bevacizumab.

### Triple Combinations

Triple combinations with V-PDT, an anti-VEGF agent and a steroid represent the next logical step in treating wet AMD. In a non-comparative, interventional case series, triple combination therapy with V-PDT, bevacizumab and dexamethasone was administered to 104 patients.<sup>34</sup> Dexamethasone was chosen instead of triamcinolone because it has a shorter half-life, a lower risk of elevated intraocular pressure and an increased anti-inflammatory potency. Bevacizumab was chosen instead of ranibizumab because the latter had not yet been approved for use. To lessen the potential for detrimental effect on the

choroidal vasculature, V-PDT was administered at a reduced light dose, specifically 600mW/cm<sup>2</sup> for 70 seconds instead of 83 seconds (or 84% of the standard light dose). Dexamethasone and bevacizumab were intravitreally injected approximately 16 hours after laser treatment. Over a mean follow-up period of 40 weeks (range 22–to 60 weeks), VA increased by a mean of 1.8 lines and retinal thickness decreased by a mean of 182µm (p<0.01 for both comparisons versus baseline). Eighty-one of 104 patients (78%) showed a satisfactory response to one course of triple therapy. This sustained benefit with one course of triple therapy is an important contrast to the need to administer anti-VEGF monotherapy on a continuing monthly basis to maintain benefit in many patients. In addition to significant and sustained VA improvement after only one cycle of treatment, no serious adverse events and no ocular events were noted.<sup>34</sup>

In another prospective case series, Veritti et al. gave V-PDT plus ranibizumab plus modified juxtasclear triamcinolone to 30 patients. V-PDT was given as standard fluence/standard irradiance (50J/cm<sup>2</sup>, 600mW/cm<sup>2</sup>), reduced fluence/standard irradiance (25J/cm<sup>2</sup>, 600mW/cm<sup>2</sup>) or reduced fluence/reduced irradiance (25J/cm<sup>2</sup>, 300mW/cm<sup>2</sup>). Over six months of follow-up in this prospective case series, no angiographic leakage occurred in any treatment group.<sup>35</sup>

Our above-described results with triple therapy<sup>34</sup> stimulated the multicentre, randomised, single-blind RADICAL trial, in which V-PDT plus ranibizumab plus or minus dexamethasone was compared with ranibizumab monotherapy. A total of 162 subjects were randomly assigned to one of four treatment groups:

- quarter-fluence V-PDT (180mW/cm<sup>2</sup> for 83 seconds to deliver 15J/cm<sup>2</sup>) followed within two hours by ranibizumab and then dexamethasone;
- half-fluence V-PDT (300mW/cm<sup>2</sup> for 83 seconds to deliver 25J/cm<sup>2</sup>) followed within two hours by ranibizumab and then dexamethasone;
- half-fluence V-PDT (as just described) followed within two hours by ranibizumab; or
- ranibizumab alone.<sup>36</sup>

Recently reported preliminary results showed that, overall, fewer re-treatments were required with the combination therapies than with ranibizumab monotherapy at one year, and the differences in the

number of re-treatments between combination therapies and ranibizumab monotherapy were statistically significant. VA improvements appeared to be similar among treatment groups but were inconclusive because the confidence intervals were wide. There were no unexpected safety findings and the adverse event incidence was similar across treatment groups.<sup>36</sup> As with the MONT BLANC trial, these are preliminary, not final, results, and the conclusions of the trial are awaited with interest.

Lastly, V-PDT, ranibizumab plus dexamethasone is also being compared with ranibizumab monotherapy in PDEX II, a single-blind trial of 60 patients. Change in VA at one year is the primary outcome measure, and results are expected by the end of 2009.<sup>37</sup>

### Summary

With no single treatment able to address the complex multifactorial pathogenesis of wet AMD, combination therapies are now being intensely studied. Targeting different disease components with different therapies that have different mechanisms of action has more potential to successfully treat the numerous pathogenetic factors involved than any monotherapy. Evidence from clinical trials demonstrates numerous benefits of combination therapy, including

improved VA outcomes, lower re-treatment rates and longer treatment-free intervals. Therapy that will improve vision with as few administrations as possible, ideally in one cycle, while maintaining efficacy and tolerability is the goal. Triple combination therapy with a steroid, V-PDT and an anti-VEGF agent now appears most capable of achieving this. Combination therapy to treat patients with wet AMD will be increasingly used by retina specialists. ■



Albert J Augustin is a Professor of Ophthalmology and Chairman of the Department of Ophthalmology at Klinikum Karlsruhe in Germany. Prior to this, he was a Professor of Ophthalmology at the University of Mainz, where he was Head of the Retina Section and Laboratory for Pathophysiology of the Eye and Assistant Medical Director at Bonn University Eye Hospital. Professor Augustin is the recipient of numerous awards, including the Film Prize (1st place) of the

German Society of Ophthalmic Surgeons and the 'Gedenkjahresstiftung' Prize of the University of Wuerzburg. He has published a number of books and over 120 papers as author or co-author. Professor Augustin is a member of numerous medical organisations, including the American Academy of Ophthalmology (AAO), the Association for Research in Vision and Ophthalmology (ARVO), Euretina, the Retina Society, the Club Jules Gonin, the American Society of Cataract and Refractive Surgery (ASCRS), the American Society of Retina Specialists (ASRS) and the Macula Society.

- Spaide RF, Perspectives: rationale for combination therapies for choroidal neovascularization, *Am J Ophthalmol*, 2006;141:149–56.
- Schlingemann RO, Role of growth factors and the wound healing response in age-related macular degeneration, *Graefes Arch Clin Exp Ophthalmol*, 2004;242:91–101.
- Grossniklaus HE, Miskala PH, Green WR, et al., Histopathologic and ultrastructural features of surgically excised subfoveal choroidal neovascular lesions: submacular surgery trials report no. 7, *Arch Ophthalmol*, 2005;123:914–21.
- Kent D, Sheridan C, Choroidal neovascularization: a wound healing perspective, *Mol Vis*, 2003;9:747–55.
- Kannan R, Zhang N, Sreekumar PG, et al., Stimulation of apical and basolateral VEGF-A and VEGF-C secretion by oxidative stress in polarized retinal pigment epithelial cells, *Mol Vis*, 2006;12:1649–59.
- Bainbridge JW, Mistry AR, Thrasher AJ, et al., Gene therapy for ocular angiogenesis, *Clin Sci (Lond)*, 2003;104:561–75.
- Ambati J, Ambati BK, Yoo SH, et al., Age-related macular degeneration: etiology, pathogenesis, and therapeutic strategies, *Surv Ophthalmol*, 2003;48:257–93.
- Grossniklaus HE, Green WR, Choroidal neovascularization, *Am J Ophthalmol*, 2004;137:496–503.
- Möhle R, Green D, Moore MA, Constitutive production and thrombin-induced release of vascular endothelial growth factor by human mega-karyocytes and platelets, *Proc Natl Acad Sci U S A*, 1997;94:663–8.
- Augustin AJ, Scholl S, Kirchoff J, Treatment of neovascular age-related macular degeneration: Current therapies, *Clin Ophthalmol*, 2009;3:175–82.
- Visudyne [package insert], East Hanover, NJ, Novartis Pharmaceuticals Corp, 2007.
- Michels S, Schmidt-Erfurth U, Rosenfeld PJ, Promising new treatments for neovascular age-related macular degeneration, *Expert Opin Investig Drugs*, 2006;15:779–93.
- Photodynamic therapy of subfoveal choroidal neovascularization in age-related macular degeneration with verteporfin: one-year results of 2 randomized clinical trials—TAP report. Treatment of age-related macular degeneration with photodynamic therapy (TAP) Study Group, *Arch Ophthalmol*, 1999;117:1329–45.
- Bressler NM, Treatment of Age-Related Macular Degeneration with Photodynamic Therapy (TAP) Study Group, Photodynamic therapy of subfoveal choroidal neovascularization in age-related macular degeneration with verteporfin: two-year results of 2 randomized clinical trials—TAP Report 2, *Arch Ophthalmol*, 2001;119:198–207.
- Kaiser PK, Treatment of age-related macular degeneration with photodynamic therapy (TAP) Study Group, Verteporfin therapy of subfoveal choroidal neovascularization in age-related macular degeneration: 5-year results of two randomized clinical trials with an open-label extension: TAP report no. 8, *Graefes Arch Clin Exp Ophthalmol*, 2006;244:1132–42.
- Anand R, Bressler NM, Bressler SB, et al., Writing Committee for the TAP Study Group, Improvement after verteporfin therapy, *Arch Ophthalmol*, 2003;121:415–16.
- Brown MD, Kaiser PK, Michels M, et al., ANCHOR Study Group, Ranibizumab versus verteporfin for neovascular age-related macular degeneration, *N Engl J Med*, 2006;355:1432–44.
- Rosenfeld PJ, Brown DM, Heier JS, et al.; MARINA Study Group, Ranibizumab for neovascular age-related macular degeneration, *N Engl J Med*, 2006;355:1419–31.
- Rich RM, Rosenfeld PJ, Puliafito CA, et al., Short-term safety and efficacy of intravitreal bevacizumab (Avastin) for neovascular age-related macular degeneration, *Retina*, 2006;26:495–511.
- Spaide RF, Laud K, Fine HF, et al., Intravitreal bevacizumab treatment of choroidal neovascularization secondary to age-related macular degeneration, *Retina*, 2006;26:383–90.
- Bashshur ZF, Bazarbachi A, Schakal A, et al., Intravitreal bevacizumab for the management of choroidal neovascularization in age-related macular degeneration, *Am J Ophthalmol*, 2006;142:1–9.
- Avastin [package insert], South San Francisco, CA, Genentech, Inc., 2008.
- Chan WM, Lai TY, Wong AL, et al., Combined photodynamic therapy and intravitreal triamcinolone injection for the treatment of subfoveal choroidal neovascularisation in age related macular degeneration: a comparative study, *Br J Ophthalmol*, 2006;90:337–41.
- Arias L, Garcia-Arumi J, Ramon JM, et al., Photodynamic therapy with intravitreal triamcinolone in predominantly classic choroidal neovascularization: one-year results of a randomized study, *Ophthalmology*, 2006;113:2243–50.
- Heier JS, Boyer DS, Ciulla TA, et al., for the FOCUS Study Group, Ranibizumab combined with verteporfin photodynamic therapy in neovascular age-related macular degeneration: year 1 results of the FOCUS Study, *Arch Ophthalmol*, 2006;124:1532–42.
- Schmidt-Erfurth U, Wolf S, PROTECT Study Group, Same-day administration of verteporfin and ranibizumab 0.5 mg in patients with choroidal neovascularisation due to age-related macular degeneration, *Br J Ophthalmol*, 2008;92:1628–35.
- Kiss CG, Simader C, Michels S, et al., Combination of verteporfin photodynamic therapy and ranibizumab: effects on retinal anatomy, choroidal perfusion and visual function in the PROTECT study, *Br J Ophthalmol*, 2008;92:1620–27.
- QLT announces 12-month results from Novartis sponsored MONT BLANC study evaluating standard-fluence Visudyne® combination therapy, press release, 15 July 2009. Available at: www.qltinc.com (accessed 13 October 2009).
- DENALI Trial, data on file, QLT and Novartis.
- Michels S, Hansmann F, Geitzenauer W, et al., Influence of treatment parameters on selectivity of verteporfin therapy, *Invest Ophthalmol Vis Sci*, 2006;47:371–6.
- Lazic R, Gabric N, Verteporfin therapy and intravitreal bevacizumab combined and alone in choroidal neovascularization due to age-related macular degeneration, *Ophthalmology*, 2007;114:1179–85.
- Kaiser PK, VERITAS Study Group, Verteporfin therapy in combination with pegaptanib or triamcinolone for wet AMD: 6-month results of the VERITAS trial [Abstract 2870], Presented at the Annual Meeting of the Association for Research in Vision and Ophthalmology, 8 May 2007, Fort Lauderdale, FL.
- Kaiser PK, for the VERITAS Study Group, VERITAS 6-month interim analysis. Presented at the Annual Meeting of the Association for Research in Vision and Ophthalmology, 8 May 2007, Fort Lauderdale, FL.
- Augustin AJ, Puls S, Offermann I, Triple therapy for choroidal neovascularization due to age-related macular degeneration: verteporfin PDT, bevacizumab, and dexamethasone, *Retina*, 2007;27:133–40.
- Veritti D, Lanzetta P, Cascavill ML, et al., Triple therapy for choroidal neovascularization due to age-related macular degeneration. ranibizumab, modified juxtasclear triamcinolone acetate, and verteporfin PDT [Abstract A598], Presented at the Annual Meeting of the Association for Research in Vision and Ophthalmology, 4 May 2009, Fort Lauderdale, FL.
- QLT announces positive results from the evaluation of Visudyne® combination therapy, press release, 2 June 2009. Available at: www.qltinc.com (accessed 13 October 2009).
- Triple therapy – PDT plus IVD and intravitreal ranibizumab versus Lucentis monotherapy to treat age-related macular degeneration (PDEX). Available at: clinicaltrials.gov/ct/show/NCT00390208 (accessed 13 October 2009).