

Clinical Optic Disc Evaluation in Glaucoma

Alexandre SC Reis,^{1,2} Andrew Toren³ and Marcelo T Nicolela⁴

1. Research Fellow, Department of Ophthalmology and Visual Sciences, Dalhousie University, Halifax, Nova Scotia, Canada;

2. Research Fellow, Department of Ophthalmology, University of Sao Paulo, Brazil; 3. Resident; 4. Associate Professor, Department of Ophthalmology and Visual Sciences, Dalhousie University, Halifax, Nova Scotia, Canada

Abstract

Examination of the optic nerve head (ONH) is essential for the diagnosis of glaucoma and assessment of its progression. Slit-lamp biomicroscopy with a handheld lens is the best method of ONH examination since it provides good stereopsis and magnification. ONH stereo photographs are complementary and may identify findings missed on slit-lamp examination. As a result of its subjective nature, a standardised approach should be utilised for clinical ONH evaluation, including an assessment of ONH size and careful evaluation of the neuroretinal rim contour, the presence of retinal nerve fibre layer (RNFL) defects and optic disc haemorrhages. Other aspects, such as peripapillary chorioretinal atrophy, vessel alterations and asymmetry between fellow eyes, might help differentiate normal from glaucomatous eyes. Progressive changes in the appearance of the ONH or RNFL are best identified with optic disc photographs or automated devices. The findings of clinical ONH evaluation are of greater value when corroborated with other aspects of clinical examination and clinical test.

Keywords

Optic disc, open-angle glaucoma, ophthalmoscopy, stereo photography, retinal nerve fibre layer, clinical examination, optic disc haemorrhage

Disclosure: The authors have no conflicts of interest to declare

Received: 15 October 2011 **Accepted:** 7 March 2012 **Citation:** *European Ophthalmic Review*, 2012;6(2):92–7 DOI: 10.17925/EOR.2012.06.02.92

Correspondence: Marcelo T Nicolela, Department of Ophthalmology and Visual Sciences, Dalhousie University, 1276 South Park Street, Room 2035, Halifax, NS, Canada, B3H 2Y9. E: nicolela@dal.ca

The detection of structural damage to the optic nerve head (ONH) is central to the diagnosis of glaucoma and is extremely important for monitoring patients at risk of glaucoma or with established disease. Glaucoma, by definition, is an optic neuropathy and therefore specific attention must be directed to the examination of the optic nerve. The ONH is the site at which the dropout of retinal ganglion cells is identified most easily with current clinical techniques and is postulated as the primary site for damage in glaucoma.^{1–3} Careful evaluation of the ONH and peripapillary tissues can usually identify early glaucomatous damage before detectable visual field loss occurs.^{4,5}

The main difficulties in the clinical assessment of the ONH relate to its inherent subjectivity, and to the overlapping spectrum and large diversity in the appearance of normal and diseased discs. Early progressive glaucomatous changes in the ONH are subtle and may be missed without careful serial examinations of the individual's optic disc. Additionally, there is currently no quick, simple, inexpensive, specific, sensitive and objective method of ONH analysis by which glaucoma is reliably diagnosed and progression detected.

Clinicians should be aware that optic disc evaluation requires not only an understanding of the normal disc appearance and the pathological process of glaucoma, but also training and clinical experience. It is essential to associate the findings of the ONH evaluation with those of the clinical history, clinical examination (such as refractive error, presence of afferent pupillary defect and intraocular pressure [IOP]) and visual field tests. This review article highlights the most relevant aspects of clinical ONH evaluation: the relevant anatomy, examination

techniques and clinical signs linked to glaucomatous damage and their relevance to patient care.

The Normal Optic Nerve Head

The ONH, or optic disc, is the location where the axons from the retinal ganglion cells converge to exit the eye through the scleral canal. Besides axons, the ONH consists of blood vessels, glia and connective tissue. The size of the scleral canal governs the size of the ONH: eyes with small canals have small optic discs (commonly seen in high hyperopia) and those with large canals have large discs (commonly seen in high myopia). Jonas et al. measured the size of the scleral canal in 107 enucleated human donor eyes.⁶ They found a high inter-individual variability with an average area of 2.59 mm², ranging from 0.68 to 4.42 mm². The edges of the scleral canal define the optic disc margin, which is clinically visible as a whitish circular band at the edge of the optic disc. The ONH is usually vertically oval, with an average dimension of 1.92 ± 0.29 mm (0.96–2.91 mm) vertically, and 1.76 ± 0.31 mm (0.91–2.61 mm) horizontally, and a surface area of 2.69 ± 0.70 mm² (0.80–5.54 mm²).⁶ Jonas and Papastathopoulos proposed that in routine practice, the clinician need not measure the exact numerical value of the disc size, but instead use a quick, crude estimate of whether the size of the disc in question is of average size, smaller than average or larger than average (*Figure 1*).⁷

The optic cup is a central pale depression in the ONH not occupied by neural tissue. The pale colour of the cup is a result of exposure of the lamina cribrosa and loss of glial tissue. There is a physiological relationship between optic disc size and cup size, so that large optic

discs have large cups, and small discs should have small, or absent, cups.⁸ The neuroretinal rim is the tissue in between the outer edge of the cup and the optic disc margin. Normally, circumferential blood vessels rest on the neuroretinal rim tissue. Therefore, in most cases, the boundaries of the cup are best determined by following the trajectory of these vessels inside the ONH. The normal healthy rim should have an orange or pink colour and no localised areas of thinning. In addition, in normal eyes the inferior rim is usually thicker than the superior rim, which is thicker than the nasal rim, and the temporal rim is the thinnest (this is known as the 'ISNT' rule – Figure 2.⁹

The distribution of the axons as they pass across the retina to enter the ONH is the key for the interpretation of visual field loss in relation to the ONH cupping in glaucoma.^{10,11} The retinal nerve fibre layer (RNFL) is composed of axons of retinal ganglion cells, which converge to the ONH with three fundamental features:¹²

- the papillomacular bundle, which has a direct course from the macula to the ONH;
- the fibres arising from the nasal retina, which also follow a relatively straight course entering the nasal aspect of the ONH; and
- the peripheral nerve fibres arising from the retina temporal to the macula, which have an arcuate course around the papillomacular bundle to reach the superior and inferior aspects of the ONH.

Moreover, a horizontal raphe separates the axons in the superior retina from those in the inferior retina.

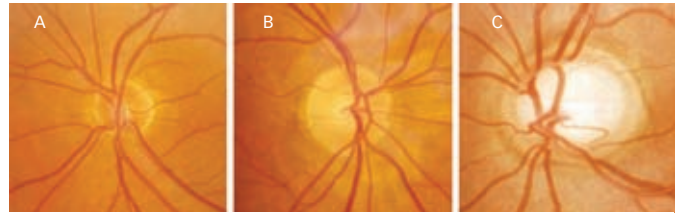
Examination Techniques

There are several techniques to examine the ONH clinically, including direct ophthalmoscopy, indirect ophthalmoscopy and slit-lamp biomicroscopy with a contact lens (such as a Goldman lens), handheld lens (+66, +78 or +90 dioptre [D] aspheric lenses) or a Hruby lens. The use of a slit lamp with a handheld lens is, in the authors' view, the preferred method. It provides a good balance between the quality of stereopsis and magnification, besides being comfortable to patients and easy to incorporate in the routine slit-lamp examination. Slit-lamp biomicroscopy with a contact lens provides a better view and has the advantage of providing a non-inverted image. However, it is less comfortable to patients, requires the use of a coupling gel and takes a longer time to perform. The clinical examination of a glaucoma patient should include pupil dilation as this allows a better stereoscopic view and adequate RNFL examination.¹³

The direct ophthalmoscope is portable, cheap and offers a magnified view, although it only provides a monocular non-stereoscopic view. The indirect ophthalmoscope is also portable and is useful to examine children and unco-operative patients. In some cases it may be the only method to examine adults with severe lens opacity. However, the low magnification of the indirect ophthalmoscope is a serious disadvantage.

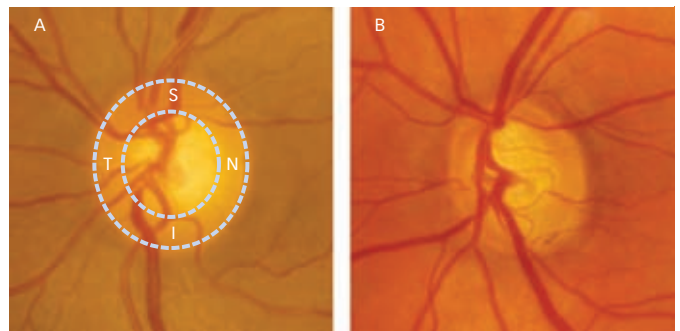
Optic disc photographs provide complementary information to the clinical examination, as well as an objective record for future comparison. Photographic documentation, preferably stereo photography, is highly recommended since features such as the presence of RNFL defects and optic disc haemorrhages (ODHs) can easily be missed during the clinical examination.¹⁴ For instance, data from the Ocular Hypertension Treatment Study (OHTS) showed

Figure 1: Examples of the Normal Sizes of Optic Discs



A: Small (disc area, 1.3 mm²); B: Medium (disc area, 2.4 mm²); C: Large (disc area, 3.8 mm²). The disc areas were measured with confocal scanning laser tomography.

Figure 2: Normal Optic Disc (A) and Glaucomatous Optic Disc (B)



A: The outer dashed line outlines the optic disc margin; the inner dashed line outlines the optic disc cup. The inferior (I) neuroretinal rim is thickest, followed in decreasing order of thickness by the superior (S), nasal (N) and temporal (T) rims, obeying the 'ISNT rule'; B: There is an overall thinning of neuroretinal rim tissue and prominent thinning in the inferotemporal sector (particularly between 5 and 6 o'clock, where the rim is almost absent), so not obeying the 'ISNT rule'.

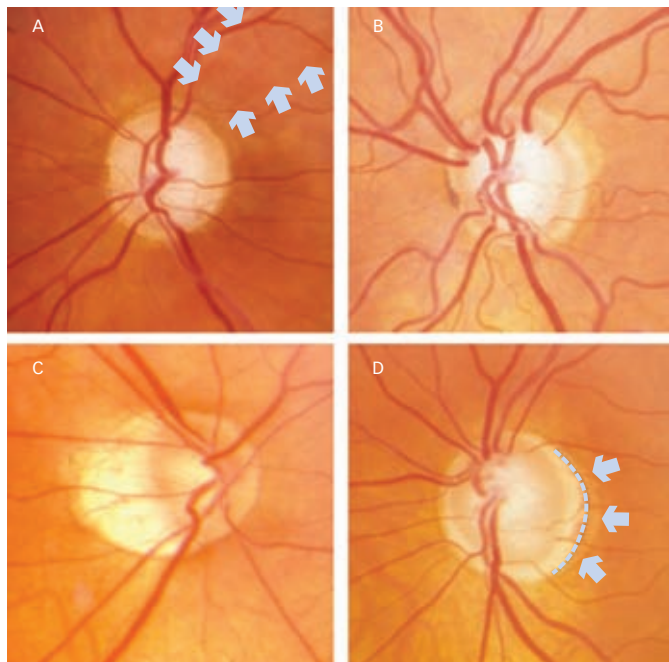
that 84 % of 128 cases of ODHs were detected on disc photographs only and not on the clinical examination.¹⁵

Evaluation of Reproducibility and Accuracy

Several studies evaluated the accuracy of the subjective ONH examination, as well as the intra- and interobserver agreement in optic disc evaluation. As expected, the intraobserver reproducibility is consistently higher than that of the interobserver (kappa [range] 0.69–0.96 versus kappa [range] 0.20–0.84, respectively) in studies to evaluate agreement among observers in the estimation of optic disc parameters.^{16,17} Similarly, substantial variability exists in the interpretation of optic disc change over time, even among expert observers, with kappa values ranging from 0.50 to 0.96 for intraobserver and from 0.55 to 0.81 for interobserver agreement.^{18–24} Observers reading photographs in the context of major clinical trials are generally reported to have low interobserver variability and excellent reproducibility.^{18–20} However, a number of other studies found a poor-to-moderate agreement among glaucoma experts when they independently assessed disc changes over time.^{21–24}

Most of these studies concentrated on the distinction between glaucoma from normal discs^{25–29} and the detection of progression.^{27,30–35} The results depend on the expertise and experience of the examiners,^{29,34,36} the ethnicity and optic disc phenotypes,³⁷ quality of stereo photography³³ and presence of pupillary dilation.¹³ How these factors impact the accuracy of a single clinician's examination in a non-research setting remains unknown, although this is crucial to patient care. In general, the sensitivity of the clinical examination for the detection of early to moderate glaucoma (with early visual field defects) is good, as its sensitivity to detect progression in

Figure 3: Examples of Glaucomatous Optic Disc Features



A: Inferotemporal focal absence of neuroretinal rim tissue (notch) and superotemporal focal thinning of the neuroretinal rim tissue (notching) with the corresponding retinal nerve fibre layer defect (between arrowheads); B: Diffuse rim loss, with concentric cup enlargement and no localised areas of loss or pallor; C: Myopic disc with crescentic temporal and inferior neuroretinal rim tissue; D: Shallow cupping extending to the optic disc margin, marked areas of peripapillary atrophy and choroidal sclerosis. The dotted line indicates the border between the beta zone (internally) and the alpha zone (externally – indicated by arrowheads).

early-to-moderate disease. The majority of these studies emphasise the need for a standardised methodology in assessing optic disc photographs, which can increase the likelihood of detecting change over time.

Imaging instruments for the detection of glaucoma, such as optical coherence tomography, scanning laser polarimetry and confocal scanning laser tomography (CSLT), perform as well as, but not better than, qualitative evaluation of optic disc stereo photographs by experts to detect early perimetric glaucoma.^{25–29} The use of such devices should be considered when expert advice is not available. Some studies that compared CSLT to glaucoma specialists in detecting ONH changes over time suggest that the automated technology at least meets and possibly exceeds the sensitivity of the subjective ONH assessment.^{22,38} Automated imaging devices offer exciting opportunities to identify glaucoma progression more accurately, which might improve even more with greater technological advances on the quality of the images and better tools to analyse the information provided. However, optic disc photography currently remains the gold standard in evaluating glaucoma progression.^{39,40}

A Standardised Approach

It is essential that the examiner have a strategy and a standardised approach in mind when examining the ONH. It is necessary to acquire the most information in the shortest possible time, as the examination can be uncomfortable for the patient. A recent publication by O'Neill et al. showed that glaucoma subspecialists adopt a more systematic behaviour when examining the optic nerve and RNFL compared with that of trainees.⁴¹ At least four main aspects need to be included in a systematic examination:⁴²

- identification of the optic disc margin;
- estimating the size of the neuroretinal rim;
- inspecting the RNFL; and
- noting additional features such as peripapillary atrophy and ODHs.

Optic Disc Margin

Determination of the optic disc margin is one of the most important aspects of the clinical examination, although it can be very difficult in individuals with high myopia (Figure 3C) and eyes with significant peripapillary atrophy (Figure 3D). The optic disc margin is defined as the innermost border of reflective tissue that is internal to any pigmented tissue and within which only neural tissue is present.^{43,44} It should be the first aspect of a systematic optic nerve examination, since variations in disc size alter significantly the estimation of glaucomatous damage. A large optic disc might appear to be glaucomatous because large discs normally have large cups and apparently thin neuroretinal rims (although the total area of the neuroretinal rim is usually larger in large discs). However, a small optic disc might hide neuroretinal rim loss, as sometimes even a small cup in a small disc is abnormal.

With a slit-lamp beam measurement scale, the size of the disc in vertical and horizontal dimensions can be calculated using conversion scales for the corresponding lens ($\times 1.0$ for +60 D, $\times 1.1$ for +78 D and $\times 1.3$ for +90 D lens).⁴⁵ The disc size can also be estimated with the direct ophthalmoscope. The 5° aperture of the Welch–Allyn ophthalmoscope produces a circular spot with a diameter of 1.5 mm and an area of 1.77 mm², which is slightly smaller than an optic disc of average size.⁴⁶

Neuroretinal Rim

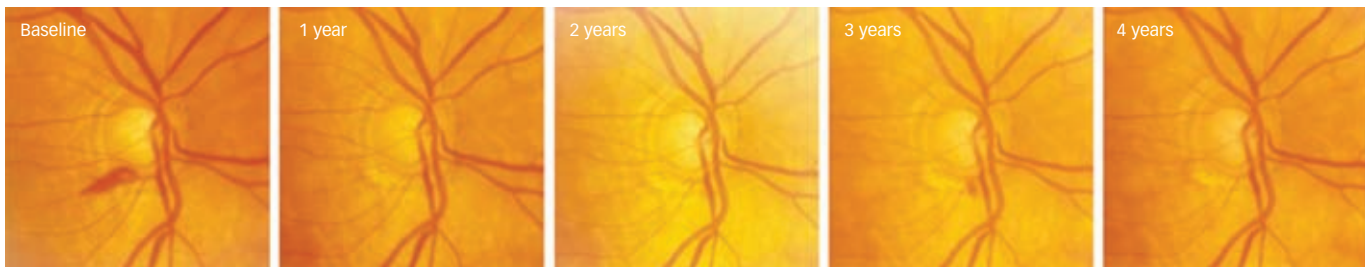
Loss of neuroretinal rim tissue should be examined carefully for both diffuse and focal loss, which may be evident as thinning, notching and nasal cupping. Kinking of the blood vessels within the ONH helps to identify the margin of the rim tissue. In myopic eyes or those with shallow cupping it can be quite difficult (Figures 3C and 3D). The inherent variability in size and shape of the optic disc among normal individuals and patients with glaucoma impairs the clinician's ability to determine rim loss with high accuracy. Detection of rim loss over time has a higher specificity than cross-sectional detection of glaucoma, since detection over time does not depend on the inter-individual variability of optic disc appearance.

Jonas et al originally described the ISNT rule.⁶ This morphometric characteristic is not followed in patients with glaucoma.^{9,47} However, one study found that early glaucomatous eyes retained the same neuroretinal rim area configuration as seen in control eyes with the ISNT rule, which suggests that the loss of neuroretinal rim in most early glaucoma subjects occurs in a diffuse manner so that they retain the same neuroretinal area configuration of normal subjects.⁴⁸

Cup-to-disc Ratio

Estimation of the size of the cup is usually made by comparison with the size of the disc, and given as the ratio of the vertical diameter of the cup to the vertical diameter of the disc (vertical cup to-disc ratio or CDR). This is the most frequently performed assessment by clinicians of the overall glaucomatous optic disc damage. However, the CDR has only limited value in the identification of glaucoma, in part because of the wide variation in the size of the optic disc and

Figure 4: Patient with Recurrent Optic Disc Haemorrhage in the Inferotemporal Sector where there is a Significant Thinning of the Neuroretinal Rim Tissue



consequently of the cup in the normal population. In addition, there is a significant variability among glaucoma specialists in the evaluation of CDR from stereoscopic photographs.^{16,35} Tielsch et al.⁴⁹ demonstrated that 17 to 19 % of CDR estimates made by two different glaucoma specialists differed by 0.2 disk diameters or more. When adjusted for disc size the CDR has been shown to have an improved diagnostic ability in early glaucoma.⁵⁰

A careful observation of rim contour as opposed to cup size or CDR is a better way to detect glaucomatous optic disc damage. Matching of clues inside and outside the optic disc is also useful, such as confirming the presence of a RNFL defect in an area where the neuroretinal rim is suspicious (*Figure 3A*).

Retinal Nerve Fibre Layer

Assessment of the RNFL requires the detection of subtle clues. This is made possible through good technique and practice. Red-free light is best for evaluation of the RNFL as the short wavelength light brings the anterior layer into better focus. There is considerable variation in the RNFL among the general population, but usually there is considerable symmetry between the two eyes of the same patient.^{51,52} The classic localised defect of the RNFL associated with glaucoma is seen as a darkened wedge that extends from a corresponding thinning in the neuroretinal rim tissue (*Figure 3A*). Diffuse RNFL defects can also be seen in glaucoma, although they are difficult to detect with biomicroscopy.¹⁰

Peripapillary Chorioretinal Atrophy

Peripapillary chorioretinal atrophy is significantly larger and occurs more often in glaucomatous eyes than in normal eyes, or in eyes with ocular hypertension.^{53,54} Furthermore, it is more often seen in glaucomatous eyes with shallow cupping than in glaucomatous eyes with deep and steep excavation.⁵⁵ Peripapillary atrophy is divided into the central beta zone and the peripheral alpha zone. The alpha zone is characterised by an irregular hypo- and hyperpigmentation, associated with thinning of the chorioretinal tissue layer. Features of the beta zone are marked atrophy of the retinal pigment epithelium and choriocapillaris and thinning of the chorioretinal tissues with good visibility of the large choroidal vessels and sclera.⁵⁶ If both zones are present, the beta zone is always closer to the optic disc than the alpha zone. The alpha zone and beta zone have to be differentiated from the scleral crescent in eyes with high myopia and from the inferior scleral crescent in eyes with tilted optic discs.

Jonas et al. reported that some alpha zone occurred in almost every normal eye (85 %), in contrast with beta zone, which was present

in only 15 % of the normal eyes.⁵⁶ In that same study, both alpha and beta zones were larger in glaucoma patients, but only the beta zone was more frequent in glaucoma patients than in healthy controls. Tezel et al. suggested that the presence, as well as the area and extension, of peripapillary atrophy along the optic disc border, especially of the beta zone variety, is associated with subsequent progression to glaucomatous damage.^{57,58} However, See et al. showed no difference in the rates of change of peripapillary atrophy area as measured with CSLT between glaucoma patients and healthy controls.⁵⁹

Optic Disc Haemorrhages

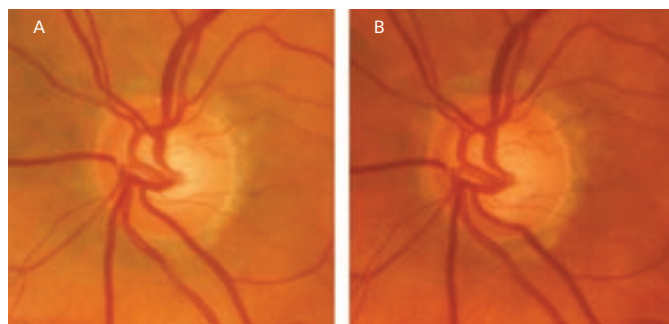
The association between ODHs and glaucoma, particularly in glaucomatous eyes with lower levels of IOP, is well established.⁶⁰⁻⁶² The presence of ODHs is a sign of the development of glaucoma¹⁵ and a strong indicator of functional and structural progression.^{61,63-67} Siegner and Netland reported close to an 80 % rate of optic disc progression following an ODH in patients with glaucoma, with progression occurring on average two years after the haemorrhage.⁶⁸ In patients with ocular hypertension the rate of conversion to glaucoma seems to be lower. Only 14 % of patients from the OHTS with disc haemorrhage developed an open-angle glaucoma endpoint, which occurred after a mean follow-up of approximately one year.¹⁵

Identifying disc haemorrhages requires meticulous inspection by the examiner. Stereo photographs help to identify small haemorrhages near blood vessels. Disc haemorrhages usually occur at the inferotemporal margin (*Figure 4*), and there is considerable spatial correlation between ODHs and neuroretinal rim tissue notches, RNFL defects⁶² and visual field loss.⁶⁹ Often they recur in the same area of the disc until a notch is formed, and then occur at other areas of the disc where the rim is still normal.^{60,62,70,71} They are transient and usually disappear after 1–6 months.⁷² The presence of ODHs is probably an important feature in monitoring treatment response. A recent report from the Early Manifest Glaucoma Trial reported that IOP-reducing treatment was unrelated to the presence or frequency of disc haemorrhages.⁶¹ However, most other studies suggest that IOP-lowering treatment decreases the frequency of ODHs.⁷³⁻⁷⁵

Other Glaucoma Features

Besides the features mentioned above, there are other optic disc features that the clinician should be alert to in both the diagnosis and follow-up of patients with glaucoma. Primary open-angle glaucoma (POAG) is usually bilateral, but frequently asymmetric, and a CDR asymmetry of 0.2 or greater has long been held to be suggestive of glaucoma.⁷⁶ However, data from the Blue Mountains

Figure 5: Glaucomatous Progression over 10 Years



A: Normal appearance of an optic disc with increased peripapillary atrophy;
 B: Generalised thinning of the neuroretinal rim tissue, markedly in the inferior quadrant. There is nasalisation of the blood vessels and an increase in the chorioretinal peripapillary atrophy area.

population study showed that cup-to-disc asymmetry is significantly associated with asymmetry of optic disc size and that asymmetry alone was not useful in identifying patients with glaucoma.⁷⁷ Therefore, when assessing the asymmetry of cup or neuroretinal rim between eyes it is important to examine whether or not the optic disc size and shape are symmetrical. Asymmetry of CDRs should be correlated to asymmetry in other parts of the clinical examination as well (i.e., IOP, visual field sensitivity, quantitative measurements of the optic nerve or RNFL).

Normally, circumlinear blood vessels rest on neuroretinal rim tissue within the optic disc. Blood vessel changes over time usually occur as a result of cupping and excavation, and might be particularly helpful in identifying progressive glaucomatous nerve damage. Common glaucomatous changes in vessels include vessel bayoneting and barring of the circumlinear blood vessels. Bayoneting refers to the sharp 90° turn, or occasionally more than 90°, turn that a blood vessel develops as it dips into an acquired pit of neuroretinal rim tissue loss and then emerges out onto the disc edge. Barring of circumlinear vessels refers to the unsupported appearance that ONH vessels acquire when no neuroretinal rim is directly in contact with them. Nasalisation of the ONH vessels is described as one of the ophthalmoscopic signs of glaucomatous damage.⁷⁸ However, as the blood vessels commonly enter and leave the eye along the nasal border of the cup, they will appear nasalised when the cup is large, either physiologically or as a result of glaucoma.^{79,80}

Visibility of the lamina cribrosa pores (lamina dot sign) is more common in eyes with glaucomatous damage to the optic disc than in normal eyes.⁸¹ This association, however, is almost entirely because of an increased visibility associated with larger vertical CDR and optic disc size.⁸² The size and shape of lamina cribrosa pores has been reported to predict glaucomatous visual field loss,⁸³ although the strength of this sign is variable.⁸⁴

Detection of Progression

The rate of optic nerve change is extremely variable among different patients. It is difficult to define rates of change because of the generally slow nature of the disease. Additionally, there is no universally accepted method to assess change. For instance, in the OHTS, the cumulative probability for conversion from ocular hypertension to glaucoma was 9.5 % over 60 months and 67 % of

these individuals converted to glaucoma on the basis of optic disc change alone.⁸⁵ In the European Glaucoma Prevention Study, the cumulative probability for conversion to glaucoma in the placebo group was 14 % over 60 months, but only 37 % of these converted on the basis of optic disc changes.²³ This difference in optic disc progression rates is probably influenced by the different criteria used to determine optic disc progression.

Optic disc progression is reported as thinning of the neuroretinal rim tissue in either a diffuse or localised pattern (Figure 5). The position and location of the deflection of blood vessels should be compared across all available photographs to uncover changes that may indicate neuroretinal rim loss in a specific sector. Baring of the circumlinear vessel or progressive nasalisation of vessels can also occur with progression (Figure 5).^{86,87} Changes in the optic disc are more easily observed in early cases of glaucoma where the dynamic range for change is greater. In more advanced stages of disease, the optic disc may be too damaged for the examiner to establish further thinning of the neuroretinal rim. When looking for progression, clinicians should be cognisant of the most probable locations to show rim area loss in glaucoma: the inferotemporal is the first to present loss, followed by the superotemporal, temporal, inferonasal, superonasal and finally the nasal sector. However, individual cases can show progression that deviates from this sequence.^{88,89}

Methods to assess changes of the optic disc over time include the use of optic disc drawing comparisons, sequential optic disc photographs (mono or stereo) and quantitative parameters on automated devices, such as the CSLT. Glaucomatous changes in the optic disc occur slowly over several years, and even very well drawn representations or detailed descriptions of the optic disc are insufficient to detect small structural progression. Optic disc photographs remain the gold standard for documentation and monitoring of optic disc appearance, although automated devices such as the CSLT can probably provide equal or superior information on structural changes of the optic disc over time when the results are analysed correctly.^{22,38,90} Objective recording of the appearance of the optic disc is therefore essential to monitor a patient with glaucoma or suspected of having the disease.

Automated imaging devices might have other practical advantages over disc photographs for the assessment of progression: faster and easier image acquisition permits more frequent examinations to allow estimates of the rate of change; and the possibility to utilise objective and statistical ways to evaluate changes in the optic disc and RNFL structure. Further improvements in hardware to capture data with increasingly higher resolution, and in software to analyse the data using increasingly complex methods, may allow the clinician to make quicker and more informed clinical decisions in the near future.²²

Conclusion

Early structural damage in glaucoma remains a hallmark of the diagnosis of glaucoma and detection of progression. The interpretation is subjective and requires complex consideration of numerous factors, emphasising the importance of a high-quality clinical examination. While newer technologies show promise in offering better detection of glaucomatous change over time, the subjective examination remains vital in managing glaucoma in clinical practice. ■

1. Anderson DR, Hendrickson A, Effect of intraocular pressure on rapid axoplasmic transport in monkey optic nerve, *Invest Ophthalmol*, 1974;13(10):771-83.
2. Quigley H, Anderson DR, The dynamics and location of axonal transport blockade by acute intraocular pressure elevation in primate optic nerve, *Invest Ophthalmol*, 1976;15(8):606-16.
3. Quigley HA, Addicks EM, Green WR, Maumenee AE, Optic nerve damage in human glaucoma. II. The site of injury and susceptibility to damage, *Arch Ophthalmol*, 1981;99(4):635-49.
4. Sommer A, Katz J, Quigley HA, et al, Clinically detectable nerve fiber atrophy precedes the onset of glaucomatous field loss, *Arch Ophthalmol*, 1991;109(1):77-83.
5. Harwerth RS, Carter-Dawson L, Shen F, et al., Ganglion cell losses underlying visual field defects from experimental glaucoma, *Invest Ophthalmol Vis Sci*, 1999;40(10):2242-50.
6. Jonas JB, Gusek GC, Naumann GO, Optic disc, cup and neuroretinal rim size, configuration and correlations in normal eyes, *Invest Ophthalmol Vis Sci*, 1988;29(7):1151-8.
7. Jonas JB, Papastathopoulos K, Ophthalmoscopic measurement of the optic disc, *Ophthalmology*, 1995;102(7):1102-6.
8. Garway-Heath DF, Ruben ST, Viswanathan A, Hitchings RA, Vertical cup/disc ratio in relation to optic disc size: its value in the assessment of the glaucoma suspect, *Br J Ophthalmol*, 1998;82(10):1118-24.
9. Harizman N, Oliveira C, Chiang A, et al, The ISNT rule and differentiation of normal from glaucomatous eyes, *Arch Ophthalmol*, 2006;124(11):1579-83.
10. Quigley HA, Miller NR, George T, Clinical evaluation of nerve fiber layer atrophy as an indicator of glaucomatous optic nerve damage, *Arch Ophthalmol*, 1980;98(9):1564-71.
11. Kanski JJ, Bowling B, Clinical ophthalmology: a systematic approach. In: *The Glaucomas*, 5th edn, Edinburgh: Butterworth-Heinemann, 2011:194J1.
12. Hoyt WF, Frisen L, Newman NM, Fundoscopy of nerve fiber layer defects in glaucoma, *Invest Ophthalmol*, 1973;12(11):814-29.
13. Kirwan JF, Gouws P, Linnell AE, et al, Pharmacological mydriasis and optic disc examination, *Br J Ophthalmol*, 2000;84(8):894-8.
14. Stone RA, Ying GS, Pearson DJ, et al., Utility of digital stereo images for optic disc evaluation, *Invest Ophthalmol Vis Sci*, 2010;51(11):5667-74.
15. Budenz DL, Anderson DR, Feuer WJ, et al., Detection and prognostic significance of optic disc hemorrhages during the Ocular Hypertension Treatment Study, *Ophthalmology*, 2006;113(12):2137-43.
16. Lichter PR, Variability of expert observers in evaluating the optic disc, *Trans Am Ophthalmol Soc*, 1976;74:532-72.
17. Harper R, Reeves B, Smith G, Observer variability in optic disc assessment: implications for glaucoma shared care, *Ophthalmic Physiol Opt*, 2000;20(4):265-73.
18. Parrish RK 2nd, Schiffman JC, Feuer WJ, et al., Test-retest reproducibility of optic disc deterioration detected from stereophotographs by masked graders, *Am J Ophthalmol*, 2005;140(4):762-4.
19. Feuer WJ, Parrish RK, 2nd, Schiffman JC, et al., The Ocular Hypertension Treatment Study: reproducibility of cup/disc ratio measurements over time at an optic disc reading center, *Am J Ophthalmol*, 2002;133(1):19-28.
20. Zeyen T, Miglior S, Pfeiffer N, et al., Reproducibility of evaluation of optic disc change for glaucoma with stereo optic disc photographs, *Ophthalmology*, 2003;110(2):340-4.
21. Jampel HD, Friedman D, Quigley H, et al., Agreement among glaucoma specialists in assessing progressive disc changes from photographs in open-angle glaucoma patients, *Am J Ophthalmol*, 2009;147(11):39-44.
22. Chauhan BC, Hutchison DM, Artes PH, et al., Optic disc progression in glaucoma: comparison of confocal scanning laser tomography to optic disc photographs in a prospective study, *Invest Ophthalmol Vis Sci*, 2009;50(4):1682-91.
23. Azuara-Blanco A, Katz LJ, Spaeth GL, et al., Clinical agreement among glaucoma experts in the detection of glaucomatous changes of the optic disk using simultaneous stereoscopic photographs, *Am J Ophthalmol*, 2003;136(5):949-50.
24. Reus NJ, de Graaf M, Lemij HG, Accuracy of GDx VCC, HRT I, and clinical assessment of stereoscopic optic nerve head photographs for diagnosing glaucoma, *Br J Ophthalmol*, 2007;91(3):313-8.
25. Badala F, Nouri-Mahdavi K, Raoof DA, et al., Optic disk and nerve fiber layer imaging to detect glaucoma, *Am J Ophthalmol*, 2007;144(5):724-32.
26. Deleon-Ortega JE, Arthur SN, McGwin G Jr, et al., Discrimination between glaucomatous and nonglaucomatous eyes using quantitative imaging devices and subjective optic nerve head assessment, *Invest Ophthalmol Vis Sci*, 2006;47(8):3374-80.
27. Girkin CA, DeLeon-Ortega JE, Xie A, et al., Comparison of the Moorfields classification using confocal scanning laser ophthalmoscopy and subjective optic disc classification in detecting glaucoma in blacks and whites, *Ophthalmology*, 2006;113(12):2144-9.
28. Greaney MJ, Hoffman DC, Garway-Heath DF, et al., Comparison of optic nerve imaging methods to distinguish normal eyes from those with glaucoma, *Invest Ophthalmol Vis Sci*, 2002;43(1):140-5.
29. Vessani RM, Moritz R, Batis L, et al., Comparison of quantitative imaging devices and subjective optic nerve head assessment by general ophthalmologists to differentiate normal from glaucomatous eyes, *J Glaucoma*, 2009;18(3):253-61.
30. Caprioli J, Prum B, Zeyen T, Comparison of methods to evaluate the optic nerve head and nerve fiber layer for glaucomatous change, *Am J Ophthalmol*, 1996;121(6):659-67.
31. Harper R, Reeves B, The sensitivity and specificity of direct ophthalmoscopic optic disc assessment in screening for glaucoma: a multivariate analysis, *Graefes Arch Clin Exp Ophthalmol*, 2000;238(12):949-55.
32. O'Connor DJ, Zeyen T, Caprioli J, Comparisons of methods to detect glaucomatous optic nerve damage, *Ophthalmology*, 1993;100(10):1498-503.
33. Wollstein G, Garway-Heath DF, Fontana L, Hitchings RA, Identifying early glaucomatous changes. Comparison between expert clinical assessment of optic disc photographs and confocal scanning ophthalmoscopy, *Ophthalmology*, 2000;107(12):2272-7.
34. Abrams LS, Scott IU, Spaeth GL, et al., Agreement among optometrists, ophthalmologists, and residents in evaluating the optic disc for glaucoma, *Ophthalmology*, 1994;101(10):1662-7.
35. Varma R, Steinmann WC, Scott IU, Expert agreement in evaluating the optic disc for glaucoma, *Ophthalmology*, 1992;99(2):215-21.
36. Breusegem C, Fieus S, Stalmans I, Zeyen T, Agreement and accuracy of non-expert ophthalmologists in assessing glaucomatous changes in serial stereo optic disc photographs, *Ophthalmology*, 2011;118(4):742-6.
37. Girkin CA, McGwin G Jr, Long C, et al., Subjective and objective optic nerve assessment in African Americans and whites, *Invest Ophthalmol Vis Sci*, 2004;45(7):2272-8.
38. Ervin JC, Lemij HG, Mills RP, et al., Clinician change detection viewing longitudinal stereophotographs compared to confocal scanning laser tomography in the LSU Experimental Glaucoma (LEG) Study, *Ophthalmology*, 2002;109(3):467-81.
39. Caprioli J, Jonas J, Vasile C, Optic disc photographs. In: Weinreb RN, Greve EL, *Glaucoma Diagnosis: Structure and Function*, The Hague: Kugler Publications, 2004:41-6.
40. Giangiacoia A, Garway-Heath D, Caprioli J, Diagnosing glaucoma progression: current practice and promising technologies, *Curr Opin Ophthalmol*, 2006;17(2):153-62.
41. O'Neill EC, Kong YX, Connell PP, et al., Gaze behavior among experts and trainees during optic disc examination: does how we look affect what we see?, *Invest Ophthalmol Vis Sci*, 2011;52(7):3976-83.
42. Susanna R Jr, Vessani RM, New findings in the evaluation of the optic disc in glaucoma diagnosis, *Curr Opin Ophthalmol*, 2007;18(2):122-8.
43. Strouthidis NG, Yang H, Reynaud JF, et al., Comparison of clinical and spectral domain optical coherence tomography optic disc margin anatomy, *Invest Ophthalmol Vis Sci*, 2009;50(10):4709-18.
44. Strouthidis NG, Yang H, Downs JC, Burgoyne CF, Comparison of clinical and three-dimensional histomorphometric optic disc margin anatomy, *Invest Ophthalmol Vis Sci*, 2009;50(5):2165-74.
45. Ansari-Shahrezaei S, Maar N, Biowski R, Stur M, Biomicroscopic measurement of the optic disc with a high-power positive lens, *Invest Ophthalmol Vis Sci*, 2001;42(1):153-7.
46. Gross PG, Drance SM, Comparison of a simple ophthalmoscopic and planimetric measurement of glaucomatous neuroretinal rim areas, *J Glaucoma*, 1995;4(5):314-6.
47. Jonas JB, Gusek GC, Naumann GO, Optic disc morphometry in chronic primary open-angle glaucoma. I. Morphometric intrapapillary characteristics, *Graefes Arch Clin Exp Ophthalmol*, 1988;226(6):522-30.
48. Shihota R, Srinivasan G, Dada T, et al., Is the ISNT rule violated in early primary open-angle glaucoma - a scanning laser tomography study, *Eye (Lond)*, 2008;22(6):819-24.
49. Tielsch JM, Katz J, Quigley HA, et al., Intraobserver and interobserver agreement in measurement of optic disc characteristics, *Ophthalmology*, 1988;95(3):350-6.
50. Jonas JB, Bergua A, Schmitz-Valckenberg P, et al., Ranking of optic disc variables for detection of glaucomatous optic nerve damage, *Invest Ophthalmol Vis Sci*, 2000;41(7):1764-3.
51. Ghadiali Q, Hood DC, Lee C, et al., An analysis of normal variations in retinal nerve fiber layer thickness profiles measured with optical coherence tomography, *J Glaucoma*, 2008;17(5):333-40.
52. Hong SW, Ahn MD, Kang SH, Im SK, Analysis of peripapillary retinal nerve fiber distribution in normal young adults, *Invest Ophthalmol Vis Sci*, 2010;51(7):3515-23.
53. Jonas JB, Fernandez MC, Naumann GO, Parapapillary atrophy and retinal vessel diameter in nonglaucomatous optic nerve damage, *Invest Ophthalmol Vis Sci*, 1991;32(11):2942-7.
54. Jonas JB, Clinical implications of peripapillary atrophy in glaucoma, *Curr Opin Ophthalmol*, 2005;16(2):84-8.
55. Broadway DC, Nicoleta MT, Drance SM, Optic disc appearances in primary open-angle glaucoma, *Surv Ophthalmol*, 1999;43(Suppl. 1):S223-43.
56. Jonas JB, Nguyen XN, Gusek GC, Naumann GO, Parapapillary chorioretinal atrophy in normal and glaucoma eyes. I. Morphometric data, *Invest Ophthalmol Vis Sci*, 1989;30(5):908-18.
57. Tezel G, Kolker AE, Kass MA, et al., Parapapillary chorioretinal atrophy in patients with ocular hypertension. I. An evaluation as a predictive factor for the development of glaucomatous damage, *Arch Ophthalmol*, 1997;115(12):1503-8.
58. Tezel G, Kolker AE, Wax MB, et al., Parapapillary chorioretinal atrophy in patients with ocular hypertension. II. An evaluation of progressive changes, *Arch Ophthalmol*, 1997;115(12):1509-14.
59. See JL, Nicoleta MT, Chauhan BC, Rates of neuroretinal rim and peripapillary atrophy area change: a comparative study of glaucoma patients and normal controls, *Ophthalmology*, 2009;116(5):840-7.
60. Drance SM, Disc hemorrhages in the glaucomas, *Surv Ophthalmol*, 1989;33(5):331-7.
61. Bengtsson B, Leske MC, Yang Z, Heijl A, Disc hemorrhages and treatment in the early manifest glaucoma trial, *Ophthalmology*, 2008;115(11):2044-8.
62. Airaksinen PJ, Mustonen E, Alanko HI, Optic disc hemorrhages. Analysis of stereophotographs and clinical data of 112 patients, *Arch Ophthalmol*, 1981;99(10):1795-801.
63. Leske MC, Heijl A, Hussein M, et al., Factors for glaucoma progression and the effect of treatment: the early manifest glaucoma trial, *Arch Ophthalmol*, 2003;121(1):48-56.
64. Leske MC, Heijl A, Hyman L, et al., Predictors of long-term progression in the early manifest glaucoma trial, *Ophthalmology*, 2007;114(11):1965-72.
65. Keltner JL, Johnson CA, Anderson DR, et al., The association between glaucomatous visual fields and optic nerve head features in the Ocular Hypertension Treatment Study, *Ophthalmology*, 2006;113(9):1603-12.
66. Kim SH, Park KH, The relationship between recurrent optic disc hemorrhage and glaucoma progression, *Ophthalmology*, 2006;113(4):598-602.
67. Drance S, Anderson DR, Schulzer M, Risk factors for progression of visual field abnormalities in normal-tension glaucoma, *Am J Ophthalmol*, 2001;131(6):699-708.
68. Siegner SW, Netland PA, Optic disc hemorrhages and progression of glaucoma, *Ophthalmology*, 1996;103(7):1014-24.
69. De Moraes CG, Prata TS, Liebmann CA, et al., Spatially consistent, localized visual field loss before and after disc hemorrhage, *Invest Ophthalmol Vis Sci*, 2009;50(10):4727-33.
70. Airaksinen PJ, Mustonen E, Alanko HI, Optic disc haemorrhages precede retinal nerve fiber layer defects in ocular hypertension, *Acta Ophthalmol (Copenh)*, 1981;59(5):627-41.
71. Soares AS, Artes PH, Andreou P, et al., Factors associated with optic disc hemorrhages in glaucoma, *Ophthalmology*, 2004;111(9):1653-7.
72. Kitazawa Y, Shirato S, Yamamoto T, Optic disc hemorrhage in low-tension glaucoma, *Ophthalmology*, 1986;93(6):853-7.
73. Medeiros FA, Alencar LM, Sample PA, et al., The relationship between intraocular pressure reduction and rates of progressive visual field loss in eyes with optic disc hemorrhage, *Ophthalmology*, 2010;117(11):2061-6.
74. Hendrickx KH, van den Enden A, Rasker MT, Hoyng PF, Cumulative incidence of patients with disc hemorrhages in glaucoma and the effect of therapy, *Ophthalmology*, 1994;101(7):1165-72.
75. Miyake T, Sawada A, Yamamoto T, et al., Incidence of disc hemorrhages in open-angle glaucoma before and after trabeculectomy, *J Glaucoma*, 2006;15(2):164-71.
76. Dielemans I, Vingerling JR, Wolfs RC, et al., The prevalence of primary open-angle glaucoma in a population-based study in The Netherlands. The Rotterdam Study, *Ophthalmology*, 1994;101(11):1851-5.
77. Ong LS, Mitchell P, Healey PR, Cumming RG, Asymmetry in optic disc parameters: the Blue Mountains Eye Study, *Invest Ophthalmol Vis Sci*, 1999;40(5):849-57.
78. Susanna R, Medeiros FA, Glaucomatous Optic Disc Cupping, 2nd edn, Rio de Janeiro: Cultura Médica, 2006:22J2.
79. Jonas JB, Mardin CY, Schlötzer-Schrehardt U, Naumann GO, Morphometry of the human lamina cribrosa surface, *Invest Ophthalmol Vis Sci*, 1991;32(2):401-5.
80. Jonas JB, Fernandez MC, Shape of the neuroretinal rim and position of the central retinal vessels in glaucoma, *Br J Ophthalmol*, 1994;78(2):99-102.
81. Susanna R Jr, The lamina cribrosa and visual field defects in open-angle glaucoma, *Can J Ophthalmol*, 1983;18(3):124-6.
82. Healey PR, Mitchell P, Visibility of lamina cribrosa pores and open-angle glaucoma, *Am J Ophthalmol*, 2004;138(5):871-2.
83. Fontana L, Bhandari A, Fitzke FW, Hitchings RA, In vivo morphometry of the lamina cribrosa and its relation to visual field loss in glaucoma, *Curr Eye Res*, 1998;17(4):363-9.
84. Motolko M, Drance SM, Features of the optic disc in preglaucomatous eyes, *Arch Ophthalmol*, 1981;99(11):1992-4.
85. Kass MA, Heuer DK, Higginbotham EJ, et al., The Ocular Hypertension Treatment Study: a randomized trial determines that topical ocular hypotensive medication delays or prevents the onset of primary open-angle glaucoma, *Arch Ophthalmol*, 2002;120(6):701-13.
86. Heuck M, Sonnsjoe B, Krakau CE, Measurement of progressive disc change in glaucoma, *Ophthalmic Surg*, 1992;23(10):672-9.
87. Varma R, Spaeth GL, Hanau C, et al., Positional changes in the vasculature of the optic disc in glaucoma, *Am J Ophthalmol*, 1987;104(5):457-64.
88. Jonas JB, Fernandez MC, Sturmer J, Pattern of glaucomatous neuroretinal rim loss, *Ophthalmology*, 1993;100(1):63-8.
89. Strouthidis NG, Gardiner SK, Sinapis C, et al, The spatial pattern of neuroretinal rim loss in ocular hypertension, *Invest Ophthalmol Vis Sci*, 2009;50(8):3737-42.
90. Chauhan BC, McCormick TA, Nicoleta MT, LeBlanc RP, Optic disc and visual field changes in a prospective longitudinal study of patients with glaucoma: comparison of scanning laser tomography with conventional perimetry and optic disc photography, *Arch Ophthalmol*, 2001;119(10):1492-9.