

## Management of the Ruptured Eye

Ferenc Kuhn<sup>1</sup> and David E Pelayes<sup>2</sup>

1. Associate Professor, Clinical Ophthalmology, University of Alabama at Birmingham, and Director, Clinical Research, Helen Keller Foundation for Research and Education; 2. Associate Professor, Ophthalmology Department, School of Medicine, Buenos Aires University, and Co-ordinator, Laboratory of Ophthalmic Research and Visual Sciences, Department of Pathology, School of Medicine, Buenos Aires University

### Abstract

Rupture is the most severe form of mechanical globe trauma because of the tissue pathologies that occur at the time of injury and because of the post-injury destruction caused by scar formation as part of the body's normal healing process. The diagnosis is usually straightforward because the wound is visible, often even to the naked eye. However, occult scleral ruptures – conjunctival integrity preserved – are not uncommon; any injury resulting from an impact by a large, blunt object therefore requires careful ocular evaluation. Due to the risk of expulsive choroidal haemorrhage wound closure is typically urgent, but all rules of proper wound toilette and suturing must be followed. The surgeon may elect to perform a staged approach, in which the initial wound-closure surgery is followed by intense topical corticosteroid therapy and then a second, comprehensive intraocular reconstruction a few days later, or to perform primary comprehensive surgery. All tissue pathologies must be properly addressed by an expert ocular traumatologist; in eyes with posterior scleral rupture, prophylactic chorioretinectomy should also be considered.

### Keywords

Eye injuries, rupture, occult scleral rupture, vitrectomy, prophylactic chorioretinectomy, timing, treatment plan, primary comprehensive reconstruction

**Disclosure:** The authors have no conflicts of interest to declare.

**Received:** 12 February 2009 **Accepted:** 27 February 2009 **DOI:** 10.17925/EOR.2009.03.01.48

**Correspondence:** Ferenc Kuhn, 1201 11th Av S, Suite 300, Birmingham, AL 35205, US. E: fkuhn@mindspring.com

Rupture is the most severe form of mechanical globe trauma and represents 32% of all open-globe injuries, according to the US Eye Injury Registry (USEIR) and the surveillance arm of the American Society of Ocular Trauma (ASOT).<sup>1</sup> In the USEIR, 25% of ruptured eyes presented with no light perception vision and only 10% had greater than 20/40 final vision, while 80% had worse than 20/200. Ruptures are caused by a (relatively) large, blunt object that initially compresses the eye; once the resistance of the eyewall (i.e. cornea and sclera)<sup>2</sup> is overcome, the eyewall opens at its weakest point.

Such a mechanism has three consequences: first, the wound is rarely located at the point of impact, but rather at predilective areas, such as the limbus, the insertion of the extraocular muscles, the insertion of the optic nerve or any area weakened by surgery or inflammation. Second, the injury is caused by an 'inside-out' mechanism, as the intraocular pressure (IOP) dramatically rises due to the impact of the object. The IOP elevation with subsequent opening of the eyewall brings the third consequence: tissue extrusion, be it uvea, vitreous or retina. The loss of intraocular contents continues until a new equilibrium with atmospheric pressure is reached. This equilibrium is reached when the IOP drops to zero or a tissue tamponades the wound, preventing further tissue prolapse. All of these outcomes have implications for management.

### Evaluation

Most patients with a ruptured eye rapidly seek medical help, mainly because of the severe, sudden loss of vision, usually due to vitreous

haemorrhage. In 74% of eyes (USEIR data), the wound is scleral or corneoscleral. Typically, there is also a conjunctival wound. If the conjunctiva is intact (occult rupture), the condition may initially remain undetected. The following signs may help to establish the diagnosis:

- presence of a thick subconjunctival haemorrhage;
- scleral step sign – with careful palpation, one of the scleral wound edges protrudes more prominently than the eye's normal contour would suggest;
- presence of a circumscribed mass under the conjunctiva – the expelled crystalline lens (see *Figure 1*);
- abnormal anterior chamber depth (if the almost always present hyphema does not block viewing the iris);
- peaked pupil (the 'angle' typically points towards the site of the scleral wound); and
- loss of the iris, crystalline lens or red reflex (vitreous haemorrhage).

The IOP is usually low, although a high IOP does not exclude the possibility of an occult rupture: if the prolapsed tissue tamponades the wound but the intraocular haemorrhage continues, the IOP may rise substantially before the extravasated blood tamponades the bleeding.

Of the signs listed above, loss of the iris has the highest specificity for making the diagnosis. If the presence of a wound is confirmed, evaluation should be stopped; fine details of the injury are best determined during surgery to avoid causing additional tissue extrusion and/or bleeding.

**Treatment**

On the operating table, the surgeon must follow certain guidelines to achieve the best possible outcome. Once the diagnosis is made or the possibility of an occult rupture cannot be excluded, the ophthalmologist must arrange for immediate surgery. Any delay risks an expulsive choroidal haemorrhage, the most devastating complication of an open-globe injury. The other very serious complication, endophthalmitis, is less of a threat as the object has not penetrated into the eye; even if the wound is open, the direction of movement is for materials away from, not into, the eye. In the case of an occult rupture, the conjunctiva provides adequate protection. General anaesthesia is preferred; however, if this is not available, some type of local anaesthesia has to be considered, as opposed to automatically deferring surgery until general anaesthesia becomes available.

**Timing**

As a general rule, the sooner the wound is closed the better. However, this must be balanced by the availability of the facility and its infrastructure (materials, equipment, personnel), as well as by the surgeon's experience. This concerns not only the wound closure itself but also the potential need for additional surgical manipulations (see below). An individual decision must be made taking into account every factor, including the severity of the injury and the wishes/circumstances of the patient.

**Wound Toilette**

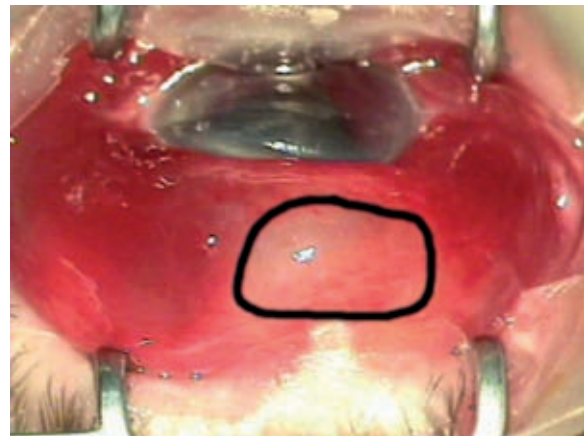
Only when an expulsive choroidal haemorrhage (ECH) occurs is it permissible to incarcerate tissues in the wound. In the vast majority of cases, the wound edges must first be cleaned of all materials, be they external (foreign bodies, debris) or internal (intraocular tissue). Following proper cleansing, repositioning is the goal, except for vitreous prolapse, which is preferably cut with the vitrectomy probe rather than using sponge and scissors. Even if the injury is over 24 hours old, every attempt should be made to preserve the iris.

**Closure of a Scleral Wound**

If the scleral wound is anterior, it is best to carefully open the conjunctiva so that the entire length of the scleral wound becomes visible. After proper wound toilette, permanent (e.g. 6-10 or 8-10 nylon) or absorbable (e.g. 6-10 or 8-10 vicryl) sutures are introduced according to the '50% rule' (see Figure 2).

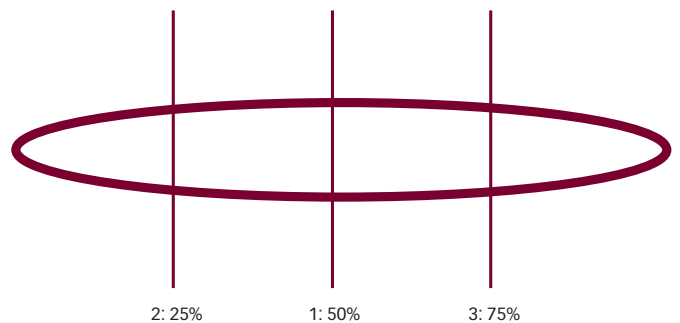
If the scleral wound is posterior enough to interfere with easy access (typically, extending past the equator), the 'close-as-you-go' technique is recommended (see Figure 3). The conjunctiva is opened anteriorly only, and the sclera is closed using the above-mentioned sutures starting from the wound's proximal end. As the conjunctival edge is approached, it is opened further posteriorly, exposing another portion of the scleral wound. This approach minimises the risk of further tissue extrusion during manipulations aimed at securing space for closing the posterior aspect of the scleral wound. Once it becomes obvious that the wound is so posterior that the introduction of a suture unavoidably threatens to cause more tissue prolapse or risks an ECH, the scleral wound is best left open. The conjunctiva is carefully closed and a shield is placed over the eye to prevent external pressure. The body's scar-formation process typically firmly closes the wound within days. Incarceration of tissues is the rule, not the exception, in these cases; this must subsequently be addressed from the inside.

**Figure 1: Evidence of an Occult Rupture**



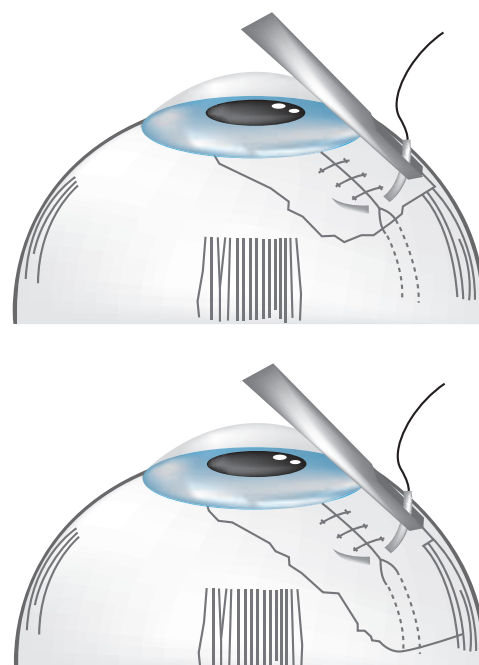
The well-circumscribed lesion (dark circle) is the extruded lens.

**Figure 2: Suture Introduction in Eyes with an Anterior Scleral Wound**



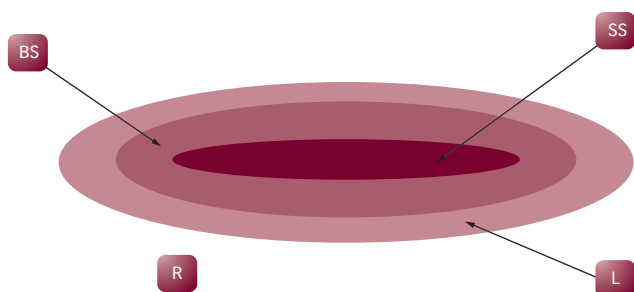
The first suture divides the wound into two roughly identically sized wounds, which are divided in the middle again, continuing until the seal is watertight.

**Figure 3: Suture Introduction in Eyes with an Anterior Scleral Wound**



The 'close-as-you-go' technique for posterior scleral wounds.

**Figure 4: Prophylactic Chorioretinectomy**



The original scleral scar (SS) remains intact. All vitreous is removed, then heavy diathermy is applied around the scar leaving a surrounding area of bare sclera (BS) approximately 1mm. Laser (L) may be applied on the remaining, free retinal (R) edge.

## Closure of a Corneal Wound

Only a few of the rules are mentioned here; the reader is referred to textbooks for more details.<sup>3,4</sup> Suture introduction must be carefully planned as not only must the wound be watertight but it also has to restore as close to normal corneal anatomy as possible. Scars interfere with the patient's visual rehabilitation (in the long term) and oedema interferes with vitreoretinal surgery (in the short term). In the USEIR, 53% of eyes with corneal trauma required vitrectomy. Unless the wound is in the limbus, interrupted – not running – sutures should be used to avoid flattening the corneal dome shape; 10-0 nylon is the preferred suture material. The suture should be 100% deep, i.e. the thread lies inside the anterior chamber. This is crucial to rapidly reduce corneal oedema but also to minimise tissue shift or override. On removal of a full-thickness suture, the eye must be sterilised as if it were going to be operated on. The surgeon should not grasp the cornea with forceps; if counterforce against the needle is needed, the conjunctiva should be grabbed. If the wound is angled, the first suture is placed at the angle; if the wound crosses the entire cornea, the Rowsey-Hays technique<sup>5</sup> is recommended (sutures with large bites are first placed at the two ends, followed by gradually smaller bites as the sutures approach the centre in a centripetal fashion). Otherwise, the 50% rule can be applied.

## Closure of a Corneoscleral Wound

The initial suture is at the limbus (this should not be full thickness to avoid introducing stem cells into the anterior chamber). This is followed by closure of the corneal wound; suturing the scleral wound completes the procedure.

## Additional Procedures During the Primary Repair

These may include removal of a hyphema, injured lens, suprachoroidal haemorrhage, etc. (see textbooks<sup>6,7</sup> for more details).

## Vitreoretinal Surgery

The main goals of vitreoretinal surgery are to clear the media opacity so that the surgeon can have a direct view of the retina and optic nerve head, treat retinal injuries already present or prevent them from

occurring and assess/treat the condition of the ciliary body. Again, the reader is referred to textbooks for details;<sup>6-8</sup> only a few important factors are mentioned here. The earlier the vitrectomy is performed, the more likely it is that retinal detachment and proliferative vitreoretinopathy (PVR) can be prevented (in the USEIR, 19% of eyes had retinal detachment at presentation). If conditions are optimal (see above), the surgeon may elect to perform comprehensive primary reconstruction: vitrectomy is carried out in the same setting with wound closure. The major risk is intraoperative ECH; therefore, it is recommended that only experienced vitreoretinal/trauma surgeons choose this option, and they must be ready and able to stop the haemorrhage and use primary silicone oil tamponade if need be.<sup>9</sup>

A reasonable alternative to such comprehensive primary reconstruction is to topically administer heavy corticosteroid therapy after the primary surgery and perform vitrectomy within the first four days post-injury.<sup>10</sup> The ciliary body must not only be re-attached

*Once the diagnosis is made or the possibility of an occult rupture cannot be excluded, the ophthalmologist must arrange for immediate surgery.*

should it be found detached during surgery, but it also must be free of blood or any material (e.g. fibrin) that may induce anterior PVR and tissue destruction with resulting phthisis. If the lens is removed and the risk of PVR is considerable, it is best to remove the lens capsules rather than considering 'in-the-bag intraocular lens implantation' as the primary goal.

If the scleral wound is posterior and/or involves the retina, prophylactic chorioretinectomy<sup>11</sup> (see Figure 4) should be considered. Early data from the international trial organised by the International Society of Ocular Trauma (ISOT) indicated that this can dramatically decrease the risk of PVR. It is not clear whether a (prophylactic) encircling band has any beneficial effect; it is up to the surgeon to make that decision. However, if a band is placed it is best to do so during the primary surgery to avoid performing the technique after the subconjunctival scarring process has started. Cryopexy should be avoided, especially if performed blindly, because it increases the risk of PVR by breaking down the blood–retina barrier.

## Summary

While ruptures remain the most severe form of open-globe injury with much damage sustained at the time of impact, meticulous management is able to reduce the effect of secondary complications. ■

1. Kuhn F, Maisiak R, Mann L, et al., The Ocular Trauma Score (OTS): Prognosticating the final vision of the seriously injured eye. In: Kuhn F, Pieramici D (eds), *Ocular Trauma: Principles and Practice*, New York: Thieme, 2002; 14–22.  
2. Kuhn F, Morris R, Witherspoon CD, et al., A standardized classification of ocular trauma terminology, *Graefes Arch Clin Exp Ophthalmol*, 1996;234:399–403.  
3. Hamill B, Basic surgical techniques in the anterior segment. In: Kuhn F, Pieramici D (eds), *Ocular Trauma:*

*Principles and Practice*, New York: Thieme, 2002:419–25.  
4. Kuhn F, Cornea. In: Kuhn F (ed.), *Ocular traumatology*, Berlin: Springer, 2008:151–84.  
5. Rowsey J, Hays J, Refractive reconstruction for acute eye injuries, *Ophthalmic Surg*, 1984;15:569–74.  
6. Kuhn F, *Ocular traumatology*, Berlin: Springer, 2008; 151–84.  
7. Kuhn F, Pieramici D, *Ocular Trauma: Principles and practice*, New York: Thieme, 2002:419–25.  
8. Alfaro V, Liggett P, *Vitrectomy in the management of the injured*

*globe*, Philadelphia: Lippincott Raven, 1998.  
9. Lemmen K, Heimann K, Fruh-Vitrektomie mit primärer Silikoninjektion bei schwerstverletzten Augen, *Klin Monatsbl Augenheilk*, 1988;193:594–601.  
10. Coleman D, Early vitrectomy in the management of the severely traumatized eye, *Am J Ophthalmol*, 1982;93: 543–51.  
11. Kuhn F, Mester V, Morris R, A proactive treatment approach for eyes with perforating injury, *Klin Monatsbl Augenheilk*, 2004;221:622–8.