

Pathogenesis of Pseudophakic Cystoid Macular Oedema

Conceição Lobo

Ophthalmologist, Department of Ophthalmology, University Hospital of Coimbra; Principal Investigator, Association for Innovation and Biomedical Research on Light and Image (AIBILI) and Institute of Biomedical Research on Light and Image (IBILI); and Invited Professor of Ophthalmology, Faculty of Medicine, University of Coimbra, Coimbra, Portugal

Abstract

Cystoid macular oedema (CMO) is a primary cause of reduced vision after cataract surgery even after uneventful surgery. The incidence of clinical CMO following modern cataract surgery is 1.0–2.0 % but the high number of surgeries performed worldwide makes this entity an important problem. Pre-existing conditions such as diabetes and intra-operative complications increase the risk of developing CMO post-operatively. CMO is caused by an accumulation of intra-retinal fluid in the outer plexiform and inner nuclear layers of the retina, as a result of the breakdown of the blood–retinal barrier. The mechanisms that lead to this condition are not completely understood. However, the principal hypothesis is that the surgical procedure is responsible for the release of inflammatory mediators, such as prostaglandins. Optical coherence tomography is at present an extremely useful non-invasive diagnostic tool. Guidelines for the management CMO should be focused essentially on prevention and are based on the principal pathogenetic mechanisms, including the use of anti-inflammatory drugs.

Keywords

Cataract surgery, cystoid macular oedema, pathogenesis, inflammatory mediators, anti-inflammatory drugs, management

Disclosure: The author has no conflict of interest to declare.

Received: 7 October 2011 **Accepted:** 18 November 2011 **Citation:** *European Ophthalmic Review*, 2012;6(3):178–84 DOI: 10.17925/EOR.2012.06.03.178

Correspondence: Conceição Lobo, Association for Innovation and Biomedical Research on Light and Image, Azinhaga de Santa Comba, Celas, 3000-548 Coimbra, Portugal. E: clobofonseca@gmail.com

Modern cataract extraction using phacoemulsification and posterior intraocular lens (IOL) implantation is one surgical procedure considered extremely safe and successful.^{1,2} The constant innovations in instrumentation, lens design and surgical technique lead to improved outcomes following this surgery.^{3,4} Although the procedure is efficient, and uneventful surgery is generally associated with good visual results,^{1,2,5} complications, as cystoid macular oedema (CMO) may develop, and this can result in sub-optimal post-operative vision.^{6–8} It can occur after uncomplicated surgery in patients with otherwise healthy eyes, after complicated surgery, or after surgery in patients with ocular diseases such as uveitis or diabetic retinopathy.⁹

CMO following cataract surgery was an entity reported first time by Irvine in 1953. Thirteen years later, Gass and Norton demonstrated its typical presentation using fluorescein angiography (FA); therefore, it is known as Irvine–Gass syndrome.^{10–12}

The pathogenesis of CMO following cataract surgery remains uncertain, but clinical observations and experimental studies indicate that the pathophysiology of this post-operative problem may be multifactorial.^{13,14} Prostaglandin-mediated inflammation^{7,14–20} and the subsequent breakdown of the blood–aqueous barrier (BAB) and blood–retinal barrier (BRB) are probably the more important facts involved.^{21–26}

Clinical CMO is diagnosed in those patients who have detectable visual impairment as well as angiographic and/or biomicroscopic findings. Some patients who are asymptomatic with respect to visual acuity, but

have detectable leakage from the perifoveal capillaries on FA, are diagnosed as angiographic CMO. Optical coherence tomography (OCT) confirms the clinical diagnosis. So, the incidence of pseudophakic CMO depends not only on the surgical technique or pre-existing conditions, but also on the methodology used in its detection.

The actual guidelines recommend the use of non-steroidal anti-inflammatory drugs (NSAIDs) pre-operatively, and the combination of steroids and NSAIDs in the post-operative period, to reduce the incidence of pseudophakic CMO.

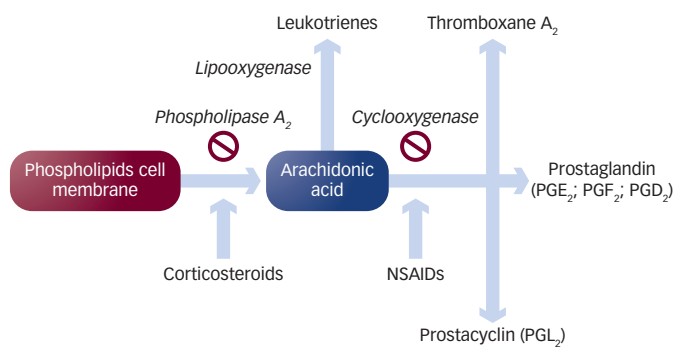
Risk Factors

The principal risk factors associated to pseudophakic macular oedema are the type of cataract surgery; complications during the surgery, such as vitreous loss, rupture of the posterior capsule, iris incarceration or retained lens fragments; and some pre-existing conditions, such as uveitis or diabetes.^{7,24}

Type of Cataract Surgery

The choice of cataract surgery procedure is associated with different outcomes and complications, such as CMO. The change in procedure from large-incision intracapsular cataract extraction and extracapsular to small-incision phacoemulsification was associated with a clear decrease in the incidence of this complication.^{7,24,27–33} This has been explained by less BAB barrier damage after phacoemulsification with an intact continuous curvilinear capsulorhexis than after extracapsular cataract extraction (ECCE).^{20,21}

Figure 1: Arachidonic Acid Cascade and Mechanism of Action of Anti-inflammatory Drugs



NSAIDs = non-steroidal anti-inflammatory drugs.

Specific IOLs implanted are associated with increased occurrence of CMO: anterior chamber IOLs, specifically iris-fixed, raise the risk more than posterior chamber IOLs.^{13,34}

Surgical Complications

Although CMO can occur after uneventful cataract surgery, certain surgical complications raise the risk of CMO. Rupture of the posterior capsule and vitreous loss are associated with a higher rate of CMO.^{7,13,34,35} Different studies have confirmed that the rate of clinical CMO associated with vitreous loss is higher compared with cases without this complication.^{35,36–38} The lower rate of CMO occurring when there is vitreous loss during phacoemulsification compared with extracapsular extraction has also been explained by the small wound construction and greater stability in this type of surgery compared with large-incision cataract surgery.^{30,39–41} Vitreous to the wound prolongs CMO, and can be associated with a worse prognosis.¹³ Iris incarceration, considered an additional risk factor for CMO, may have a more important association with poor vision in patients with chronic post-surgical CMO than with other intra-operative complications.^{34,42} Retained lens fragments, even when they are removed by pars plana vitrectomy, is another complication associated with an increased rate of CMO and more severe visual loss, in eyes with a sulcus fixated posterior chamber IOL, anterior chamber IOL or aphakic eyes.^{43–46} Retained lens fragments cause inflammation that is often severe, and these eyes additionally have longer cataract surgery times than eyes with uneventful cataract extraction.

Pre-existing Conditions

In diabetic patients, especially those with pre-existing diabetic retinopathy, there is an increased risk of CMO.⁴⁷ The incidence of CMO in diabetic patients, even in the absence of diabetic retinopathy, is higher than in patients without this pathology.⁴⁸ Although the frequency of this problem has decreased with the widespread use of smaller incisions and phacoemulsification, it remains an important issue to consider.⁴⁹ The poor visual acuity after cataract surgery in these patients due to macular oedema is common, and the two clinical forms (diabetic macular oedema and oedema caused by Irvine–Gass syndrome) probably co-exist and may facilitate the occurrence.^{47,50,51} These are difficult to differentiate, although some authors have suggested that if there is post-operative hyperfluorescence of the optic disc in the angiograms, it probably corresponds to a CMO that would be likely to resolve spontaneously.⁵² It is very important to take into consideration that if the patient has already some degree of macular oedema when the cataract surgery is considered, it should be treated

before the surgery. In cases when this is not possible it is proposed to use intravitreal anti-inflammatory medication at the time of surgery.

Patients with uveitis frequently develop CMO, and it is the most common reason for poor outcomes of cataract surgery in these patients.⁵³ It is important to note that there is a wide variation in severity of uveitis, and surgeons should consider these patients at risk of post-operative CMO.^{54,55} Taking this into account, it is imperative to control pre-operative inflammation and introduce post-operative medication according to the expected risk.

In conclusion, the most frequent risk factors associated with pseudophakic CMO are iris trauma, rupture of the posterior capsule, vitreous loss or incarceration, dislocated IOL, use of iris-fixed lenses, active uveitis and diabetes.

Pathogenesis

Clinical observations and experimental studies indicate that the pathophysiology of CMO following cataract surgery is multifactorial.^{13,14}

Many pathophysiological mechanisms for CMO after cataract surgery have been proposed, but the most compelling at the present time is that surgery causes anterior segment inflammation, which results in the release of endogenous inflammatory mediators, including prostaglandins.^{7,14–20,56}

Inflammation

The term inflammation is used in this context as the inflammatory repair response to the surgical procedure with production of a variety of eicosanoids. Eicosanoids are defined as prostaglandins, leukotrienes and other compounds that are products of the action of phospholipase A₂ on the cellular phospholipid membrane and are, in general, derived from the production of arachidonic acid (see Figure 1).^{57,58} The cyclooxygenase enzymes (COX) play a role in the arachidonic acid cascade to produce the different eicosanoids. These enzymes are important in maintaining cellular integrity and preventing apoptosis in eukaryotes,⁵⁹ with the eicosanoid products of COX playing important roles in cellular homeostasis, such as modulation of platelet function.⁶⁰ Nevertheless, as a response to injury there is an upregulation of the COX enzyme system, resulting in overproduction of eicosanoids required for cellular homeostasis.

Iris Trauma

During the cataract surgery, associated with surgical manipulation a variable degree of trauma to the iris may occur. It is known that the iris is a metabolically active tissue that releases inflammatory mediators when traumatised. After surgery, the physiological healing process is sufficient to slowly, but progressively, suppress the inflammation.⁶¹ In about 90 % of patients with macular oedema following cataract surgery, a spontaneous resolution of the oedema and a recovery of visual acuity can be observed. In specific situations, excessive leakage occurs, which can lead to severe and irreversible impairment of visual acuity. The different degrees of leakage explain the higher incidence of angiographically detectable CMO compared with clinically identified CMO.⁶²

Lens Epithelial Cells

Additionally, there are different studies that have shown that lens epithelial cells when traumatised by surgery also synthesise inflammatory mediators, including prostaglandins.^{15,16,63–65} The receptors

for prostaglandins are located widely in the eye, but especially in the ciliary body and iris sphincter.⁶⁶ Increased levels of prostaglandins in the eye have been demonstrated after cataract surgery⁶³ and they are considered one of the major mediators of inflammation and vascular permeability. The common feature of many of the risk factors that are thought to contribute to development of CMO is therefore chronic ocular inflammation with associated BAB breakdown.

Mediators of Inflammation

It has been postulated that, after cataract surgery, inflammation mediators (prostaglandins, cytokines and other vascular permeability factors) are released from the anterior segment of the eye and diffuse to the vitreous cavity and retina, stimulating the breakdown of the BRB^{21-24,56} and subsequent leakage of fluids across the retinal vessel wall and through the retinal pigment epithelium (RPE) into perifoveal retinal tissues, resulting in macular oedema.^{24,56,67}

Different studies support the idea that the arachidonic acid cascade is not the only chemical mediator related to post-operative inflammation. It is believed that other substances are also involved, such as complement,⁶⁸ platelet-activating factor (PAF),⁶⁹ lysozyme,⁷⁰ cytokines,^{71,72} nitric monoxide⁷³ and endothelin.⁷⁴ One cytokine well studied is interleukin-6 (IL-6).^{71,72} An increased level of this mediator was found in the aqueous humour of patients undergoing cataract surgery.^{71,75} The cytokines produce COX-2, and PAF interacting with interleukins and prostaglandins is believed to be responsible for inflammatory reactions.^{69,74} Additionally, other studies reported that endothelin was an inducer of the arachidonic cascade but that inhibitors of COX prevent the inflammation of the anterior chamber induced by endothelin.^{76,77}

Cyclooxygenases

Developing knowledge concerning COX is leading to a better understanding of the different pathways involved. Some studies confirmed that there are two types of COX.^{78,79} COX-1, a constitutive isoform, is responsible for the biosynthesis of prostaglandins associated with the homeostasis of normal tissue and is present in all tissue.⁸⁰ COX-2, the induced isoform, biosynthesises prostaglandins associated with inflammation and appears in response to stimulation from proliferative factors, such as IL-1 β or endotoxin. Based on these different mediators the management of CMO post cataract surgery is centred on the development of drugs to block these mediators and if possible with minor only side effects. NSAIDs are non-selective, as they inhibit both COX-1 and COX-2,⁸¹⁻⁸³ whereas steroid drugs interfere with the activity of phospholipase A2, selectively inhibiting COX-2 (see *Figure 1*).^{84,85}

Vitreous Traction

Although the most widely accepted explanation for the aetiology of CMO after cataract surgery is inflammation in the anterior segment associated with disruption of the BAB, releasing mediators, particularly prostaglandins, that diffuse posteriorly leading to breakdown in BRB and consequent macular oedema, other theories have been proposed. One of potential clinical importance is that tractional forces on the foveal area exerted by the vitreous lead to CMO.^{10,86,87} Since the vitreous inserts into the internal limiting membrane, which is attached to the Müller fibres, these cells could be particularly affected by vitreous tractions, leading to macular oedema.⁸⁸ The minimal traction on the vitreomacular interface in the phacoemulsification procedure compared with ECCE is also the explanation for the reduced risk of CMO in these patients.^{32,33}

Summarising, inflammatory mediators probably play the essential initiating role in the development of inflammatory CMO, but other factors and events responsible for further CMO development and its chronicity have not yet been clearly identified.

Incidence

The improvement in the procedures associated with cataract surgery, such as decreasing surgical incision, progressively smaller microsurgical instrumentation and minimal turbulence during the surgery, are responsible for the progressive decline in the rate of occurrence of CMO. Despite of this, the high volume of cataract surgeries performed each year still makes CMO a common cause of poor vision in pseudophakic patients.⁴¹

There are multiple reports comparing the incidence of clinical and angiographic CMO under specific anti-inflammatory drugs.^{25,89,90} These multiple reports and reviews on this subject show different numbers and the explanations are, in certain cases, unclear.^{13,91} The use of different prophylactic medications before and after cataract surgery and variations in the patient populations evaluated, with varying risk factors, contribute to the difficulty in determining the overall real incidence of CMO. Another factor that contributes to this variability is the use of different methods to evaluate macular thickness. However, it is important to recognise the many variables involved and the difficulty in identifying their potential impact on the interpretation of results from therapeutic trials that evaluated potential treatments for CMO.

The true current incidence of clinical CMO using modern surgical techniques, such as small-incision phacoemulsification with implantation of a foldable IOL, especially if it occurs without complications, appears to be very low. It is likely to be in the range of 0.2-2%, although the rate of angiographic CMO is at least 10-fold higher.^{13,24,41,88,92} These numbers increase if another surgical technique is required, such as large incision and different IOL implantation or, if we have a complicated surgery with iris trauma, capsule rupture with vitreous loss, or in patients at high risk, such as those with uveitis or diabetes.

Diagnosis

Signs and symptoms of clinically significant CMO typically develop four to 12 weeks after surgery and reach a peak at four to six weeks post-operatively. The patient may complain of impaired vision after an initial period of improved vision due to the cataract removal.³⁴

The diagnosis of CMO can generally be made on clinical examination with evidence of perifoveal cystic spaces, and has traditionally been confirmed with use of FA to document the classic petaloid pattern of leakage induced by inflammatory mediators that leads to breakdown of the BRB. Today, the most objective evidence is obtained from non-invasive OCT examination.

Usually, CMO has a good response with only topical anti-inflammatory medications. However, some cases respond poorly to this conservative treatment and can persist for more than six months, developing permanent visual loss. Although the incidence of chronic CMO is much less frequent, being reported at 1-2% of uncomplicated cases and about 8% after complicated cataract surgery, the associated vision loss makes it an important complication.

The diagnosis of clinical CMO is considered in those patients who have detectable visual impairment as well as angiographic and/or

biomicroscopic findings.^{41,93} In patients with detectable leakage from perifoveal capillaries on FA but otherwise asymptomatic with respect to visual acuity, the diagnosis of angiographic CMO can be considered. An even higher incidence of alterations in the period immediately after cataract surgery can be shown with vitreous fluorometry, a more sensitive technique for measuring alterations in the BRB using fluorescein.²² The retinal leakage analyser is another methodology that can be used to objectively measure the disruption of the BRB, leading to a quantitative evaluation of the macular oedema.⁹⁴

With OCT, it is possible to observe the cystic spaces in the outer nuclear layer of the central macula and measure the oedema, which should correspond to the value of the observed retinal thickening.⁹⁵⁻⁹⁷ Foveal thickness can increase significantly and, although the correlation with the decrease in visual acuity is only moderate, it is clearly better than the correlation between FA and visual acuity.

Although FA has been considered indispensable for the diagnosis of pseudophakic CMO, OCT is now the method of choice due to the fact that it is a non-invasive technique that leads to a precise evaluation of CMO in order to follow each case after cataract surgery.⁹⁸ An additional advantage of the use of OCT is that the thickening of the macular area effectively measures the oedema, and therefore correlates better with vision than the possible grade performed with FA.¹³

Management

Angiographic CMO is not necessarily associated with poor visual outcome. Most cases of post-operative CMO resolve spontaneously, with only about 1–3 % of cases persisting, and this corresponds to clinical CMO with persistent symptoms.^{41,99} Nevertheless, it is now widely accepted that in cataract surgery it is important to perform therapeutic intervention using anti-inflammatory drugs in cases diagnosed as clinical CMO to treat, but also and specifically in all cases, to prevent the development of CMO after cataract surgery.

The available therapeutic approaches for the prophylaxis and treatment of CMO, such as topical steroids and NSAIDs, are based on theories regarding the pathogenesis of the condition;^{58,100} therefore, it is directed towards blocking the inflammatory mediators, mainly the prostaglandins in the anterior segment of the eye. Clinical evidence suggests that the combined use of steroids and NSAIDs is synergistic.^{6,101-104} This synergistic effect is based on the different mechanism of action of the two drugs.¹⁰⁵⁻¹⁰⁹

Corticosteroids and NSAIDs

Corticosteroids are effective, and are considered the gold standard for the treatment of ocular inflammation, but they are associated with an increased incidence of adverse events, including a rise in intraocular pressure (IOP) in a small percentage of patients.¹¹⁰ Due to this limitation the cataract surgeons are interested in alternative treatments with similar effectiveness but with fewer complications. These are the NSAIDs and they vary in their relative potency against COX-1 and COX-2 in the post-cataract surgery setting. COX-2-specific activity is important because it is the form of the enzyme that is believed to be the primary mediator of ocular inflammation.

Multiple studies have been performed to test the efficacy of the different available NSAIDs in the prevention and treatment of pseudophakic CMO.^{99-101,103,105,111} However, these studies usually have been poorly designed and, although in general they have proven the

effectiveness of use of this type of medication in preventing both angiographic and clinical CMO,²⁵ the absence of clear statistical differences between the different NSAIDs is the reason controversy persists over which to use.

Topical NSAIDs are classified into different groups based on their chemical composition. There is some difficulty in obtaining an ideal formulation of NSAIDs to be applied topically to the eye.¹¹² Some are considered too toxic to be used in the eye; others are weakly acid thus they have a limited permeability through the cornea and, on the other hand, the acid drugs are a potential irritant. There are, however, at the moment, several NSAIDs approved in EU for treatment of post-operative inflammation after cataract surgery: ketorolac, diclofenac, flurbiprofen, indometacin, nepafenac and bromfenac.¹¹²

The two more recently introduced drugs in the European market – nepafenac and bromfenac – have some potential advantages, due to rapid penetration in ocular tissues related to high corneal permeability.^{100,112-117} They have been developed to exploit the anti-inflammatory potency of amfenac within the eye. Amfenac is a highly potent inhibitor of both COX-1 and COX-2, but it is unable to penetrate the corneal epithelium.¹¹⁸ Nepafenac is an inactive precursor of amfenac that can penetrate the corneal epithelium and within the eye must then be converted to the active amfenac. Bromfenac is structurally identical to amfenac but with some specific differences that make it a highly lipophilic molecule, which facilitates its rapid penetration through the cell membrane of various tissues, including ocular, to obtain sustained drug levels, increasing the duration of analgesic and anti-inflammatory activity.^{112,117}

Another point of discussion is related to the timing of the use of steroids and NSAIDs before surgery.⁹³ It is now considered essential to use NSAIDs and/or steroids, in risk cases, before surgery during a variable period according to each specific situation. In other cases the use of NSAIDs should be considered at least two days before surgery.^{98,111}

Current Guidelines

The current guidelines for managing post-cataract surgery inflammation are based on the premise that the prevention of inflammation should be the main goal. So, it is mandatory to perform good patient selection and correct eye/patient preparation according the possible risk factors. During surgery it is very important to take special care not to cause iris trauma. Additionally, if there are any intra-operative complications the appropriate resolution is recommended and any case of post-operative inflammation should be timely treated.¹¹⁹

In the presence of a normal patient, it is recommended as prophylaxis to administer topical NSAIDs during the first month in combination with topical steroids during the first two weeks in decreasing doses. In patients with evidence of anterior segment inflammation or if there is recognised CMO, the topical NSAIDs and steroids should be reintroduced for another month. After this, visual acuity should be evaluated and an OCT should be performed to estimate any possible improvement in the CMO. If the CMO has not improved, the introduction of acetazolamide (for one month or more) should be considered or, as an alternative, a local sub-conjunctival injection of corticosteroid. High-dose intravitreal administration of corticosteroid, such as triamcinolone, should be reserved for severe refractory cases. This can reduce macular oedema and improve vision in eyes with CMO that persists or recurs despite previous medical treatment.¹²⁰⁻¹²²

However, CMO may recur in some cases, even after more than one intravitreal injection of triamcinolone acetonide.

Carbonic Anhydrase Inhibitors

The rationale for the use of carbonic anhydrase inhibitor – acetazolamide – is based on its effect in helping to reduce the oedematous component by stimulating the RPE to pump excess fluid out of the macula. Carbonic anhydrase inhibitors induce acidification of the sub-retinal space, and thereby increase fluid resorption from the retina through the RPE into the choroid.^{34,123} There are some reports documenting the efficacy of acetazolamide on post-surgical CMO.^{124,125}

Anti-angiogenic Agents

The use of anti-angiogenic agents has also been proposed as an alternative therapeutic approach in some cases of refractory CMO. Vascular endothelial growth factor (VEGF) is a potent inducer of alterations in the BRB and, being a crucial mediator in post-operative CMO, may be increased in post-operative CMO. The anti-VEGF agents reduce vascular permeability by a mechanism of action distinct from prostaglandin inhibition.^{123,126,127} However, bevacizumab, a monoclonal antibody against all isoforms of VEGF that has been used to treat some neovascular eye diseases, was used in patients with post-operative CMO without improvement concerning visual acuity.¹²⁸

Laser and Surgical Treatment

Vitreous incarceration in the cataract incision wound is associated with increased incidence of CMO after cataract surgery. Vitreolysis using the Nd:YAG laser has shown promising results for such cases.¹²⁹

In some specific conditions, such as vitreous incarceration with persistent inflammatory reaction or in chronic CMO, surgical treatment, namely vitrectomy, is indicated and it is associated with visual acuity improvement.^{130,131} The rationale for performing vitrectomy in CMO following surgery includes the removal of vitreous adhesions and inflammatory mediators and improved access of topical medication to the posterior pole.³⁴

Diabetic Patients

Diabetic patients, specifically if they have pre-surgical macular oedema, are considered a higher risk group and the possibility of

worsening their macular oedema after cataract surgery is considered. Based on this possibility it is recommended to first treat the macular oedema and perform the surgery only when the situation is assumed stable. In these cases, the use of intravitreal triamcinolone acetonide (4 mg) injected at the end of cataract surgery should be recommended.

Conclusion

Phacoemulsification using small incision and implantation of a foldable intraocular lens (IOL) is one of the most commonly performed surgeries. The procedure is efficient, and uneventful surgery is generally associated with good visual results. Nevertheless, CMO may develop and can result in sub-optimal post-operative vision. The incidence of clinical CMO following modern cataract surgery is 1.0–2.0 % but the high number of surgeries performed worldwide makes this entity an important problem.

The most widely accepted explanation for the pathophysiology of CMO after cataract surgery is inflammation in the anterior segment associated with disruption of the BAB, releasing mediators, particularly prostaglandins, that diffuse posteriorly leading to breakdown of the BRB and consequent macular oedema.

Although FA has been considered indispensable for the diagnosis of pseudophakic CMO, OCT is now the method of choice due to the fact that it is a non-invasive technique. Another advantage of OCT is that it measures the thickening of macular area, and this is a parameter that correlates better with vision than the possible grade performed with FA.

The current guidelines for managing post-cataract surgery inflammation are based on the premise that the prevention of inflammation should be the main goal. It is mandatory to perform good patient selection and correct eye/patient preparation according to the possible risk factors. Although the treatment options depend on the underlying cause of CMO, the usual therapeutic approach for prophylaxis and treatment of CMO is directed towards blocking the inflammatory mediators, mainly the prostaglandins in the anterior segment of the eye, using topical steroids and NSAIDs. ■

- Linebarger EJ, Hardten DR, Shah GK, et al., Phacoemulsification and modern cataract surgery, *Surv Ophthalmol*, 1999;44:123–47.
- Gogate PM, Kulkarni SR, Krishnaiah S, et al., Safety and efficacy of phacoemulsification compared with manual small-incision cataract surgery by a randomized controlled clinical trial: six-week results, *Ophthalmology*, 2005;112:869–74.
- DeCross FC, Afshari NA, Perioperative antibiotics and anti-inflammatory agents in cataract surgery, *Curr Opin Ophthalmol*, 2008;19:22–6.
- Panchapakesan J, Rochtchina E, Mitchell P, Five-year change in visual acuity following cataract surgery in an older community: the Blue Mountains Eye Study, *Eye*, 2004;18:278–82.
- Riaz Y, Mehta JS, Wormald R, et al., Surgical interventions for age related cataract, *Cochrane Database Syst Rev*, 2006;4:CD001323.
- O'Brien TP, Emerging guidelines for use of NSAID therapy to optimize cataract surgery patient care, *Curr Med Res Opin*, 2005;21:1131–7, correction 2005;21:1431–2.
- Rossetti L, Autelitano A, Cystoid macular edema following cataract surgery, *Curr Opin Ophthalmol*, 2000;11:65–72.
- Mohammadpour M, Jafarinasab MR, Javadi MA, Outcomes of acute postoperative inflammation after cataract surgery, *Eur J Ophthalmol*, 2007;17:20–8.
- Nelson ML, Martidis A, Managing cystoid macular edema after cataract surgery, *Curr Opin Ophthalmol*, 2003;14:39–43.
- Irvine AR, A newly defined vitreous syndrome following cataract surgery, interpreted according to recent concepts of the structure of the vitreous, *Am J Ophthalmol*, 1953;36:599–619.
- Gass JD, Norton EW, Cystoid macular edema and papilledema following cataract extraction: a fluorescein fundoscopic and angiographic study, *Arch Ophthalmol*, 1966;76:646–61.
- Irvine AR, Cystoid maculopathy, *Surv Ophthalmol*, 1976;21:1–17.
- Flach AJ, The incidence, pathogenesis and treatment of cystoid macular edema following cataract surgery, *Trans Am Ophthalmol Soc*, 1998;96:557–634.
- Jampol LM, Aphakic cystoid macular edema: a hypothesis, *Arch Ophthalmol*, 1985;103:1134–5.
- Miyake K, Prevention of cystoid macular edema after lens extraction by topical indomethacin. I. A preliminary report, *Albrecht von Graefes Arch Klin Exp Ophthalmol*, 1977;203:81–8.
- Miyake K, Prevention of cystoid macular edema after lens extraction by topical indomethacin. II. A control study in bilateral extractions, *Jpn J Ophthalmol*, 1978;22:80–94.
- Miyake K, Sakamura S, Miura H, Long-term follow-up study on prevention of aphakic cystoid macular edema by topical indomethacin, *Br J Ophthalmol*, 1980;64:324–8.
- Jampol LM, Cystoid macular edema following cataract surgery, *Arch Ophthalmol*, 1988;106:894–5.
- Stark WJ, Maumenee AE, Fagadau W, et al., Cystoid macular edema in pseudophakia, *Surv Ophthalmol*, 1984;28:442–5.
- Bito LZ, Prostaglandins: old concepts and new perspectives, *Arch Ophthalmol*, 1987;105:1036–9.
- Smith RT, Campbell CJ, Koester CJ, et al., The barrier function in extracapsular cataract surgery, *Ophthalmology*, 1990;97:90–5.
- Cunha-Vaz JG, Travassos A, Breakdown of the blood-retinal barriers and cystoid macular edema, *Survey Ophthalmol*, 1984;28:485–92.
- Miyake K, Vitreous fluorophotometry in aphakic or pseudophakic eyes with persistent cystoid macular edema, *Jpn J Ophthalmol*, 1985;29:146–52.
- Ursell PG, Spalton DJ, Whitcup SM, Nussenblatt RB, Cystoid macular edema after phacoemulsification: relationship to blood-aqueous barrier damage and visual acuity, *J Cataract Refract Surg*, 1999;25:1492–7.
- Rossetti L, Chaudhwi H, Dickerson K, Medical prophylaxis and treatment of cystoid macular edema after cataract surgery: the results of a meta-analysis, *Ophthalmology*, 1998;105:397–405.
- Gulkilik G, Kocabora S, Taskapilli M, Engin G, Cystoid macular edema after phacoemulsification: risk factors and effect on visual acuity, *Can J Ophthalmol*, 2006;41:699–703.
- Hitchings RA, Chisholm IH, Bird AC, Aphakic macular edema: incidence and pathogenesis, *Invest Ophthalmol Soc*, 1975;14:68–72.
- Jaffe NS, Clayman HM, Jaffe MS, Cystoid macular edema after intracapsular and extracapsular extraction with and without an intraocular lens, *Ophthalmology*, 1982;89:25–9.
- Kraff MC, Sanders DR, Jampol LM, Lieberman HL, Effect of primary capsulotomy with extracapsular surgery on the incidence of pseudophakic cystoid macular edema, *Am J Ophthalmol*, 1984;98:166–70.
- Koch PS, Anterior vitrectomy, in: Nordan LT, Maxwell WA, Davidson JA, eds, *Surgical Rehabilitation of Vision: An Integrated Approach to Anterior Segment Surgery*, London: Gower, 1992.
- Powe NR, Schein OD, Gieser SC, et al., Synthesis of the literature on visual acuity and complications following cataract extraction with intraocular lens implantation. Cataract Patient Outcome Research Team, *Arch Ophthalmol*, 1994;112:239–52.
- Oshika T, Yoshimura K, Miyata N, Postsurgical inflammation after phacoemulsification and extracapsular extraction with

- soft or conventional intraocular lens implantation, *J Cataract Refract Surg*, 1992;18:356–61.
33. Pande MV, Spalton DJ, Kerr-Muir MG, Marshall J, Postoperative inflammatory response to phacoemulsification and extracapsular cataract surgery: aqueous flare and cells, *J Cataract Refract Surg*, 1996;22:770–4.
 34. Loewenstein A, Zur D, Postsurgical cystoid macular edema, in Coscas G, ed., *Macular Edema Devel Ophthalmol*, Basel: Karger, 2010;47:148–59.
 35. Frost NA, Sparrow JM, Strong NP, Rosenthal AR, Vitreous loss in planned extracapsular cataract extraction does lead to a poorer visual outcome, *Eye*, 1995;9:446–51.
 36. Balent A, Civerchia LL, Mohamadi P, Visual outcomes of cataract extraction and lens implantation complicated by vitreous loss, *J Cataract Refract Surg*, 1988;14:158–60.
 37. Bergman M, Laatikainen L, Cystoid macular oedema after complicated cataract surgery and implantation of an anterior chamber lens, *Acta Ophthalmol (Copenh)*, 1994;72:178–80.
 38. Blomquist PH, Rugwani RM, Visual outcomes after vitreous loss during cataract surgery performed by residents, *J Cataract Refract Surg*, 2002;28:847–52.
 39. Ah-Fat FG, Sharma MK, Majid MA, Yang YC, Vitreous loss during conversion from conventional extracapsular cataract extraction to phacoemulsification, *J Cataract Refract Surg*, 1998;24:801–5.
 40. Morel C, Roman S, Metge F, et al., Surgery of intravitreal nuclear luxations post-phacoemulsification (in French), *J Fr Ophthalmol*, 1998;21:170–5.
 41. Ray S, Amico DJ, Pseudophakic cystoid macular edema, *Semin Ophthalmol*, 2002;17:167–80.
 42. Spaide RF, Yannuzzi LA, Sisco LJ, Chronic cystoid macular edema and predictors of visual acuity, *Ophthalmic Surg*, 1993;24:262–7.
 43. Borne MJ, Tasman W, Regillo C, et al., Outcomes of vitrectomy for retained lens fragments, *Ophthalmology*, 1996;103:971–6.
 44. Kapusta MA, Chen JC, Lam WC, Outcomes of dropped nucleus during phacoemulsification, *Ophthalmology*, 1996;103:1184–7.
 45. Rossetti A, Doro D, Retained intravitreal lens fragments after phacoemulsification: complications and visual outcome in vitrectomized and nonvitrectomized eyes, *J Cataract Refract Surg*, 2002;28:310–5.
 46. Cohen SM, Davis A, Cukrowski C, Cystoid macular edema and pars plana vitrectomy for retained lens fragments, *J Cataract Refract Surg*, 2006;32:1521–6.
 47. Pollack A, Leiba H, Bukelman A, Oliver M, Cystoid macular edema following cataract extraction in patients with diabetes, *Br J Ophthalmol*, 1992;76:221–4.
 48. Schmier JK, Halpern MT, Covert DW, et al., Evaluation of cost for cystoid macular edema among patients after cataract surgery, *Retina*, 2007;27:621–8.
 49. Henricsson M, Heijl A, Janzon L, Diabetic retinopathy before and after cataract surgery, *Br J Ophthalmol*, 1996;80:789–93.
 50. Dowler JGF, Hykin PG, Lightman SL, et al., Visual acuity following extracapsular cataract extraction in diabetes: a meta-analysis, *Eye*, 1995;9:313–7.
 51. Schatz H, Atienza D, McDonald HR, et al., Severe diabetic retinopathy after cataract surgery, *Am J Ophthalmol*, 1994;117:314–21.
 52. Dowler JGF, Sehmi KS, Hykin PG, et al., The natural history of macular edema after cataract surgery in diabetes, *Ophthalmology*, 1999;106:663–8.
 53. Okhravi N, Lightman SL, Towler HM, Assessment of visual outcome after cataract surgery in patients with uveitis, *Ophthalmology*, 1999;106:710–22.
 54. Hooper PL, Rao NA, Smith RE, Cataract extraction in uveitis patients, *Surv Ophthalmol*, 1990;35:120–44.
 55. Foster RE, Lowder CY, Meisler OM, Zakov ZN, Extracapsular cataract extraction and posterior chamber intraocular lens implantation in uveitis patients, *Ophthalmology*, 1992;99:1234–41.
 56. Miyake K, Ibaraki N, Prostaglandins and cystoid macular edema, *Surv Ophthalmol*, 2002;47(Suppl. 1):S203–18.
 57. Gaynes B, Onyekwulije A, Topical ophthalmic NSAIDs: a discussion with focus on nepafenac ophthalmic suspension, *Clin Ophthalmol*, 2008;2(2):355–68.
 58. Cervantes-Costes G, Sánchez-Castro Y, Mendoza-Schuster E, et al., Inhibition of surgically induced miosis and prevention of postoperative macular edema with nepafenac, *Clin Ophthalmol*, 2009;3:219–26.
 59. Xiaojun L, Weilin X, Reed D, et al., Nonsteroidal anti-inflammatory drugs cause apoptosis and induce cyclooxygenases in chicken embryo fibroblasts, *Proc Natl Acad Sci USA*, 1995;92:7961–5.
 60. Morrow JD, Roberts LJ, Lipid-derived autoids, in: Hardman JG, Limbird LE, eds., *Goodman and Gilman's the Pharmacologic Basis of Therapeutics*, 10th edn, New York: McGraw-Hill, 2010, pp.679–80.
 61. Augustin A, Loewenstein A, Kuppermann BD, General pathophysiology, in: Coscas G, ed., *Macular Edema Devel Ophthalmol*, Basel: Karger, 2010;47:10–26.
 62. Mentes J, Erakgun T, Afrashi F, et al., Incidence of cystoid macular edema after uncomplicated phacoemulsification, *Ophthalmologica*, 2003;217:408–12.
 63. Miyake K, Sugiyama S, Norimatsu I, et al., Prevention of cystoid macular edema after lens extraction by topical indomethacin: III. Radioimmunoassay measurements of prostaglandins in the aqueous during and after lens extraction procedures, *Albrecht von Graefes Arch Klin Exp Ophthalmol*, 1978;209:83–8.
 64. Miyake K, Mibu H, Horiguchi M, et al., Inflammatory mediators in post-operative aphakic and pseudophakic baboon eyes, *Arch Ophthalmol*, 1990;108:1764–7.
 65. Nishi O, Nishi K, Imanishi M, Synthesis of interleukin-1 and prostaglandin E2 by lens epithelial cells of human cataracts, *Br J Ophthalmol*, 1992;76:338–41.
 66. Woodward DF, Regan JW, Lake S, et al., The molecular biology and ocular distribution of prostanoid receptors, *Surv Ophthalmol*, 1997;41:15–21.
 67. Tso MOM, Pathophysiology of cystoid macular edema, *Ophthalmology*, 1982;89:902–15.
 68. Mondino BJ, Nagata S, Glovsky MM, Activation of the alternative complement pathway by intraocular lenses, *Invest Ophthalmol Vis Sci*, 1985;26:905–8.
 69. Yousufzai SYK, Abdel-Latif AA, Effect of platelet-activating factor on the release of arachidonic acid and prostaglandins by rabbit iris smooth muscle. Inhibition by calcium channel antagonists, *Biochem J*, 1985;228:697–706.
 70. Hayasaka M, Masuda K, Ocular irritation and lysosomal enzymes in aqueous humor. Part II. Lysosomal enzymes after paracentesis, intracameral injection of PGE2, neutral formaldehyde instillation, or fifth nerve stimulation, *Nihon Ganka Kyō (Folia Ophthalmol Jpn)*, 1980;31:1269–72.
 71. Malecaze F, Chollet P, Cavrois E, et al., Role of interleukin 6 in the inflammatory response after cataract surgery, *Arch Ophthalmol*, 1991;109:1681–3.
 72. Yokoyama T, Interleukin-1β in the aqueous humor in aphakic and pseudophakic eyes of rabbits, *Nippon Ganka Gakkai Zasshi (Acta Soc Ophthalmol Jpn)*, 1992;9:67–73.
 73. Nussler AK, Billiar TR, Inflammation, immunoregulation, and inducible nitric oxide synthase, *J Leukoc Biol*, 1993;54:171–8.
 74. Bazan NG, Allan G, Signal transduction and gene expression in the eye: a contemporary view of the pro-inflammatory, anti-inflammatory and modulatory roles of prostaglandins and other bioactive lipids, *Surv Ophthalmol*, 1997;41(Suppl. 1):S23–34.
 75. Miyake K, Masuda K, Shirato S, et al., Comparison of diclofenac and fluorometholone in preventing cystoid macular edema after small incision cataract surgery: a multicentered prospective trial, *Jpn J Ophthalmol*, 2000;44:58–67.
 76. Abdel-Latif AA, Zhang Y, Yousufzai SYK, Endothelin-1 stimulates the release of arachidonic acid and prostaglandins in rabbit iris sphincter smooth muscle: activation of phospholipase A2, *Curr Eye Res*, 1991;10:259–65.
 77. Shoji N, Oshika T, Masuda K, Anterior chamber inflammation after the injection of endothelin-1 into the vitreous and the effect of an anti-prostaglandin agent, *Nippon Ganka Gakkai Zasshi (Jpn Ophthalmol Soc)*, 1997;101:209–14.
 78. Raz A, Wyche A, Needleman P, Temporal and pharmacological division of fibroblast cyclooxygenase expression into transcriptional and translational phases, *Proc Natl Acad Sci USA*, 1989;86:1657–61.
 79. Fu J, Masferrer JL, Seibert K, Raz A, Needleman P, The induction and suppression of prostaglandin H2 synthetase (cyclooxygenase) in human monocytes, *J Biol Chem*, 1990;265:16737–40.
 80. Needleman P, Isakson P, The discovery and function of COX-2, *J Rheumatol*, 1997;24(Suppl. 49):9–14.
 81. Battistini B, Botting R, Bakkle YS, COX-1 and COX-2, Towards the development of more selective NSAIDs, *Drug News Perspect*, 1994;7:501–12.
 82. Masferrer JL, Reddy ST, Zweifel BS, et al., In vivo glucocorticoids regulate cyclooxygenase-2 but not cyclooxygenase-1 in peritoneal macrophages, *J Pharmacol Exp Ther*, 1994;270:1340–4.
 83. Masferrer JL, Kulkarni PS, Cyclooxygenase-2 inhibitors: a new approach to the therapy of ocular inflammation, *Surv Ophthalmol*, 1997;41(Suppl. 2):S35–40.
 84. Kujubu DA, Fletcher BS, Varnum BC, Lim RW, Herschman HR, TS 10, a phorbol ester tumor promoter-inducible mRNA from Swiss 3T3 cells, encodes a novel prostaglandin synthetase/cyclooxygenase homologue, *J Biol Chem*, 1991;266:12866–72.
 85. O'Banion MK, Sadowski HB, Winn V, Young DA, A serum- and glucocorticoid-regulated 4 kilobase mRNA encodes a cyclooxygenase-related protein, *J Biol Chem*, 1991;266:23261–7.
 86. Tolentino FI, Schepens CL, Edema of posterior pole after cataract extraction: a biomicroscopic study, *Arch Ophthalmol*, 1965;74:781–6.
 87. Schepens CL, Avila MP, Jalkh AE, et al., The role of vitreous in cystoid macular edema, *Surv Ophthalmol*, 1984;28:499–504.
 88. Mentes 2J, Erakgun T, Afrashi F, Kerci G, Incidence of cystoid macular edema after uncomplicated phacoemulsification, *Ophthalmologica*, 2003;217:408–12.
 89. Asano S, Kensaku M, Ota I, et al., Reducing angiographic cystoid macular edema and blood-aqueous barrier disruption after small-incision phacoemulsification and foldable intraocular lens implantation. Multicenter prospective randomized comparison of topical diclofenac 0.1% and betamethasone 0.1%, *J Cataract Refract Surg*, 2008;34:57–63.
 90. Sivaprasad S, Bunce C, Wormald R, Nonsteroidal anti-inflammatory agents for cystoid macular oedema following cataract surgery: a systematic review, *Br J Ophthalmol*, 2005;89:1420–2.
 91. Kraff MC, Sanders DR, Jampol LM, et al., Factors affecting pseudophakic cystoid macular edema: five randomized trials, *J Am Intraocul Implant Soc*, 1985;11:380–5.
 92. Henderson BA, Kim JY, Ament CS, et al., Clinical pseudophakic cystoid macular edema: risk factors for development and duration after treatment, *J Cataract Refract Surg*, 2007;33:1550–8.
 93. Kim A, Stark WJ, Are topical NSAIDs needed for routine cataract surgery? *Am J Ophthalmol*, 2008;146:554–60.
 94. Lobo CL, Faria PM, Soares MA, et al., Macular alterations after small incision cataract surgery, *J Cataract Refract Surg*, 2004;30:752–60.
 95. Hee MR, Izatt JA, Swanson EA, et al., Optical coherence tomography of the human retina, *Arch Ophthalmol*, 1995;113:325–32.
 96. Perente I, Utine CA, Ozturker C, et al., Evaluation of macular changes after uncomplicated phacoemulsification surgery by optical coherence tomography, *Curr Eye Res*, 2007;32:241–7.
 97. Biro Z, Balla Z, Kovacs B, Change of foveal and perifoveal thickness measured by OCT after phacoemulsification and IOL implantation, *Eye*, 2008;22:8–12.
 98. Almeida DR, Johnson D, Hollands H, et al., Effect of prophylactic nonsteroidal anti-inflammatory drugs on cystoid macular edema assessed using optical coherence tomography quantification of total macular volume after cataract surgery, *J Cataract Refract Surg*, 2008;34:64–9.
 99. Salomon LD, Efficacy of topical flurbiprofen and indomethacin in preventing pseudophakic cystoid macular edema. Flurbiprofen – CME study group I, *J Cataract Refract Surg*, 1995;21:73–81.
 100. Wolf EJ, Braunstein A, Shih C, et al., Incidence of visually significant pseudophakic macular edema after uneventful phacoemulsification in patients treated with nepafenac, *J Cataract Refract Surg*, 2007;33:1546–9.
 101. Heier JS, Topping TM, Baumann W, et al., Ketorolac versus prednisolone versus combination therapy in treatment of acute pseudophakic cystoid macular edema, *Am Acad Ophthalmology*, 2000;107:2034–8.
 102. Flach AJ, Nonsteroidal anti-inflammatory drugs, in: Tasman W, ed., *Duane's Foundations of Clinical Ophthalmology*, Philadelphia: Lippincott, 1994, pp. 1–32.
 103. Warren K, Bahrani H, Fox J, NSAIDs in combination therapy for treatment of chronic pseudophakic cystoid macular edema, *Retina*, 2010;30:260–6.
 104. Edelman JL, Lutz D, Castro MR, Corticosteroids inhibit VEGF-induced vascular leakage in a rabbit model of blood-retinal and blood-aqueous barrier breakdown, *Exp Eye Res*, 2005;80:249–58.
 105. Simone JN, Whitacre MM, Effects of anti-inflammatory drugs following cataract extraction, *Curr Opin Ophthalmol*, 2001;12:63–7.
 106. Flach AJ, Cyclo-oxygenase inhibitors in ophthalmology, *Surv Ophthalmol*, 1992;36:259–84.
 107. Miyake K, Nonsteroidal anti-inflammatory agents in cataract intraocular lens surgery (editorial review), *Curr Opin Ophthalmol*, 1995;6(1):62–5.
 108. Flach AJ, Topical nonsteroidal anti-inflammatory drugs in ophthalmology, *Int Ophthalmol Clin*, 2002;42(1):1–11.
 109. McColgin AZ, Heier JS, Control of intraocular inflammation associated with cataract surgery, *Curr Opin Ophthalmol*, 2000;11:3–6.
 110. McGhee CN, Dean S, Danesh-Meyer H, Locally administered ocular corticosteroids: benefits and risks, *Drug Saf*, 2002;25:33–55.
 111. Yavas GF, Öztürk F, Küsbeci T, Preoperative topical indomethacin to prevent pseudophakic cystoid macular edema, *J Cataract Refract Surg*, 2007;33:804–7.
 112. Cho H, Mozayan A, New look at ocular inflammation control – Powerful and fast-acting twice-daily Bromfenac for novel standard in treatment of inflammation, *Eur Ophthalmol Rev*, 2011;5:20–6.
 113. Walters T, Raizman M, Ernest P, et al., In vivo pharmacokinetics and in vitro pharmacodynamics of nepafenac, amfenac, ketorolac, and bromfenac, *J Cataract Refract Surg*, 2007;33:1539–45.
 114. Maxwell WA, Reiser HJ, Stewart RH, et al., and the Nepafenac Study Group, Nepafenac dosing frequency for ocular pain and inflammation associated with cataract surgery, *J Ocul Pharmacol Ther*, 2008;24:593–9.
 115. Nardi M, Lobo C, Bereczki A, et al., for the International C-04-65 Study Group, Analgesic and anti-inflammatory effectiveness of nepafenac 0.1% for cataract surgery, *Clin Ophthalmol*, 2007;1:527–33.
 116. Donnerfeld ED, Holland EJ, Stewart RH, et al., Bromfenac ophthalmic solution 0.09% (Xibrom) for post-operative ocular pain and inflammation, *Ophthalmology*, 2007;114:1653–62.
 117. Cho H, Wolf KJ, Wolf EJ, Management of ocular inflammation and pain following cataract surgery: focus on bromfenac ophthalmic solution, *Clin Ophthalmol*, 2009;3:199–210.
 118. Ahuja M, Dhake AS, Sharma SK, et al., Topical ocular delivery of NSAIDs, *AAPS J*, 2008;10:229–41.
 119. Alió J, Bodaghi B, Tassinon MJ, Guidelines for managing post-ataract surgery inflammation. Can we reach a consensus? *Ophthalmol Times Europe*, 2008;Suppl. Nov:1–11.
 120. Jonas JB, Kreissling I, Segenring RF, Intravitreal triancinolone acetonide for pseudophakic cystoid macular edema, *Am J Ophthalmol*, 2003;136:384–6.
 121. Boscia F, Furino C, Dammaco R, et al., Intravitreal triancinolone acetonide in refractory pseudophakic cystoid macular edema: functional and anatomic results, *Eur J Ophthalmol*, 2005;15:89–95.
 122. Conway MD, Canakis C, Livir-Rallatos C, et al., Intravitreal triancinolone acetonide for refractory chronic pseudophakic cystoid macular edema, *J Cataract Refract Surg*, 2003;29:27–33.
 123. Tranos PG, Wickremasinghe SS, Stangos NT, et al., Macular edema, *Surv Ophthalmol*, 2004;5:470–90.
 124. Catiar A, Tadayoni R, Massin P, et al., Advantages of acetazolamide associated with anti-inflammatory medications in postoperative treatment of macular edema (in

- French), *J Fr Ophthalmol*, 2005;28:1027–31.
125. Ćurković T, Vukojević N, Bužan K, Treatment of pseudophakic cystoid macular edema, *Coll Antropol*, 2005;29:103–5.
126. Rothova A, Inflammatory cystoid macular edema, *Curr Opin Ophthalmol*, 2007;18:487–92.
127. Flower RJ, Studies on the mechanism of action of anti-inflammatory drugs. A paper in honour of John Vane, *Thromb Res*, 2003;110:259–63.
128. Spitzer MS, Ziemssen F, Yoeruek E, et al., Efficacy of intravitreal bevacizumab in treating postoperative pseudophakic cystoid macular edema, *J Cataract Refract Surg*, 2008;34:70–5.
129. Steinert RF, Wasson PI, Neodymium: YAG laser anterior vitreolysis for Irvine-Gass cystoid macular edema, *J Cataract Refract Surg*, 1989;15:304–7.
130. Fung WE, Vitrectomy for chronic aphakic cystoid macular edema. Results of a national, collaborative, prospective, randomized investigation, *Ophthalmology*, 1985;92:1102–11.
131. Harbour JW, Smiddy WE, Rubsamen PE, et al., Pars plana vitrectomy for chronic pseudophakic cystoid macular edema, *Am J Ophthalmol*, 1995;120:302–7.