

Flap Technology Review—The Case for Femtosecond Laser Flaps in Laser *In Situ* Keratomileusis

Ronald R Krueger, MD¹ and Richard Potvin, MASc ,OD²

1. Medical Director, Cole Eye Institute, Cleveland Clinic Foundation; 2. Consultant, Science in Vision

Abstract

Purpose: To review the literature concerning the relative advantages and disadvantages of laser *in situ* keratomileusis (LASIK) flaps created with mechanical microkeratomes versus femtosecond laser systems. **Setting:** Cole Eye Institute, Cleveland Clinic Foundation, Cleveland, OH 44195. **Methods:** A review of the literature available related to mechanical microkeratomes and femtosecond laser systems was conducted. Operational limitations, complications, complication rates, and clinical outcomes were compared. **Results:** Data from the peer-reviewed literature showed that intra-operative complication rates were slightly higher with mechanical microkeratomes, and a training effect was evident. Complication rates with femtosecond laser systems have dropped as the laser spot size and/or energy has decreased and shot frequency has increased. Laser-created flaps showed lower variability in flap thickness and greater variety in programmable flap geometry. Spherocylindrical refractive outcomes were generally similar but higher order aberrations were reported as lower with femtosecond laser flap creation. **Conclusion:** There is now extensive evidence in the literature comparing these technologies. The results support current femtosecond laser technology as superior to mechanical microkeratomes for the creation of LASIK flaps in refractive surgery.

Keywords

Femtosecond laser, laser *in situ* keratomileusis (LASIK), surgery, mechanical microkeratomes

Disclosure: Ronald R Krueger, MD, is Medical Director of the Department of Refractive Surgery at the Cole Eye Institute of the Cleveland Clinic Foundation in Cleveland. He is a consultant for Alcon Laboratories, Inc. Richard Potvin, MASc, OD, is a private consultant providing data analysis and research services to ophthalmologists and the ophthalmology industry. His clients include Alcon Laboratories, Inc.

Received: February 27, 2012 **Accepted:** March 2, 2012 **Citation:** *US Ophthalmic Review*, 2012;5(1):18–21 DOI: 10.17925/USOR.2012.05.01.18

Correspondence: Ronald R Krueger, MD, Cole Eye Institute, Cleveland Clinic, 9500 Euclid Ave/i32 Cleveland, OH 44195. E: Krueger@ccf.org

Support: The publication of this article was funded by Alcon Laboratories, Inc.

It has been more than a decade since the femtosecond laser entered the ophthalmic market as an alternative to the mechanical microkeratome for the creation of flaps in laser *in situ* keratomileusis (LASIK).¹ The first device approved in the US was the IntraLase® Femtosecond Laser (Abbott Medical Optics) in 2001. The early successes of this device generated considerable interest in the technology, such that there are now five femtosecond laser systems available to surgeons, each with slightly different characteristics. *Table 1* summarizes the key features of each system.² The first widely available IntraLase system operated at 15 kHz, a significantly lower pulse rate (with significantly higher pulse energy) than used in more recently available systems. The fundamental theory behind the use of the femtosecond laser for flap creation is that the laser can perform cutting procedures, much like a blade. A focused pulse of the laser causes photodisruption of the target tissue, effectively creating a microseparation that is then followed by an expanding cavitation bubble, which then collapses to a smaller size. When these pulses are contiguously arranged along a common focal plane, they produce a dissection plane. Larger pulses create larger expanding bubbles, which reduce the number of pulses required to cleave the tissue. However,

collateral damage from the shock wave in the tissue is higher with these larger, higher energy pulses, and there is a correspondingly higher inflammatory response.³ A greater number of smaller pulses can achieve the same result. The advantage of a smaller spot size is that the energy per pulse can be significantly lower. To maintain a constant ablation time, the frequency of the laser system must rise as the spot size decreases. The cleavage that occurs with the femtosecond laser is functionally equivalent to that which can be achieved with the cutting of a blade. However, there are histologic differences in the two procedures in both the inflammatory⁴ and healing⁵ responses.

By the end of 2008, it was estimated that 35–40 % of LASIK surgeries in the US were being performed using a femtosecond laser for flap creation.⁶ It is estimated that this number has since increased to up to 70 %. There are now more than 50 publications in the peer-reviewed literature comparing the use of mechanical microkeratomes and femtosecond lasers for LASIK flap creation. The evidence in the literature indicates that there is a good case for adopting femtosecond laser technology for all LASIK flaps. Some of the key arguments are outlined here.

Flap Geometry and Orientation

The general principle of mechanical microkeratome flap creation is as follows. The first step is application of a suction ring to fix the eye into a firm position. Next, an oscillating blade set at an acute angle within a microkeratome head piece is advanced across the cornea to cut the flap. This second step involves a localized flattening (applanation) of the cornea over the area of contact as it advances, but this is not the same as the global corneal applanation of femtosecond lasers. The localized applanation of the cornea over the advancing blade can locally imbricate or compress the tissue to lead to variability of flap thickness.⁷ The blade stops before the final diameter is reached to provide a flap hinge opposite to the point of entry of the blade. The surgeon finally lifts the cut flap with a spatula to expose the stroma for the excimer laser ablation.

The placement of the microkeratome head defines the position of the flap, and the flap diameter. Flap thickness (in the applanated state) is determined by the chosen microkeratome head. Mechanical microkeratomes tend to produce a meniscus (tapering) flap (see *Figure 1*),⁸ and of course there is no opportunity to create a side wall, since one cannot make an angle at any point in the cut.

The femtosecond laser systems generally involve the same first step of a suction ring to fix the eye in a firm position. The laser is next coupled with the eye in a uniform manner by docking with either flat applanation or a fixed, curved surface of greater radius of curvature than the cornea (see *Table 1*). The laser is then used to create a specific flap geometry on the eye. The position of the flap can generally be adjusted within the region of docking contact to refine the flap placement despite the initial suction ring position. Flap diameter, thickness, and hinge geometry are programmed and the laser performs the necessary cuts. Vertical side walls are typical, and several systems include a stromal ‘pocket’ unrelated to the flap to allow for the incarceration of the gases generated during the photodisruptive process. Alternatively, an external canal can be designed to expel the gases, as seen with the Wavelight FS200® system (Alcon Laboratories, Inc). The final step of lifting the flap to expose the stroma for excimer laser ablation involves a fine dissection of the precut flap using a blunted spatula.

Overall, the variability of central flap thickness is greater with mechanical microkeratomes in comparison to femtosecond laser systems. The standard deviation of central flap thickness measured with ultrasound subtraction pachymetry is in the order of 20 µm with mechanical systems and typically around 10 µm with femtosecond laser systems.⁹ Equally important is the flap geometry and its individual predictability. The variability in flap geometry has been measured with anterior segment optical coherence tomography (AS-OCT) post-operatively. Flaps made with femtosecond lasers appear closer to the planned geometry and significantly more planar than flaps made with mechanical microkeratomes.¹⁰⁻¹² This is also consistent with reports using confocal microscopy to evaluate flap dimensions post-operatively.¹³

Flap Complications

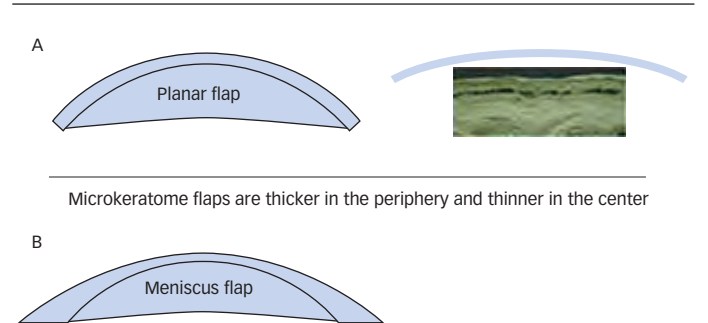
The types of complications encountered with mechanical microkeratomes versus femtosecond laser technology are significantly different. While overall complication rates appear similar, it seems, at first glance, that intra-operative complications are more frequent with

Table 1: Technical Features of Femtosecond Laser Devices for Flap Creation

Feature	Abbott IntraLase iFS	Carl Zeiss VisuMax	Technolas	Alcon FS200	Ziemer LDV
Pulse rate (kHz)	150 kHz	500 kHz	80 kHz	200 kHz	>1 MHz
Pulse duration (fs)	>500	400	>500	350	200–300
Spot size (µm)	1–5	1	>1	5	<2
Pulse energy (nJ)	500–1,300	<300	>500	300–1500	<100
Interface suction	Manual	Computer controlled low pressure	Manual	Manual	Computer controlled within hand piece
Laser-cornea coupling	Flat	Curved	Curved	Flat	Flat
Customizable features	High	Very high	High	High	Very limited

Source: Reggiani-Mello and Krueger, 2011.²

Figure 1: Meniscus versus Planar Flaps



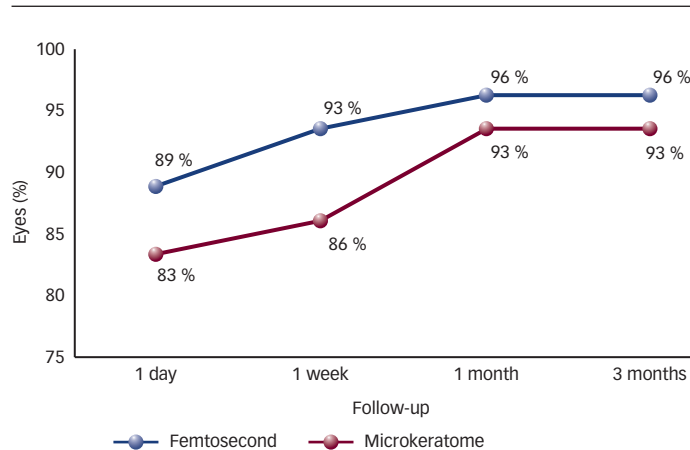
Sub-Bowman's keratomileusis (A) creates a uniform flap profile, whereas microkeratome-made flaps (B) are thicker in the periphery and thinner in the center.²

mechanical microkeratomes, while post-operative complications seem to favor the femtosecond laser systems. Specific complication rates vary widely because the criteria for identifying what constitutes a complication are not standardized. The majority of complications resolve without any impact on best corrected vision.¹⁴

One complication encountered with mechanical microkeratomes is epithelial sloughing, thought to be related to the shearing forces of the microkeratome blade transmitted to the basement membrane, disrupting its attachment to the epithelium. Other complications are typically related to the interface between the eye and the microkeratome docking head, and the keratome's effect on cut geometry. These intra-operative complication rates are generally low, but include button-hole flaps (where the central cornea is not removed with the rest of the flap), partial flaps, and free flaps.¹⁴ Diffuse lamellar keratitis is also a reported complication post-surgery, but the incidence appears much lower than with the early femtosecond laser systems.¹⁵ Epithelial ingrowth is also a complication primarily favoring mechanical microkeratomes, presumably because the steeper side walls of a femtosecond laser flap fit more tightly together and reduce the potential space for ingrowth.¹⁶

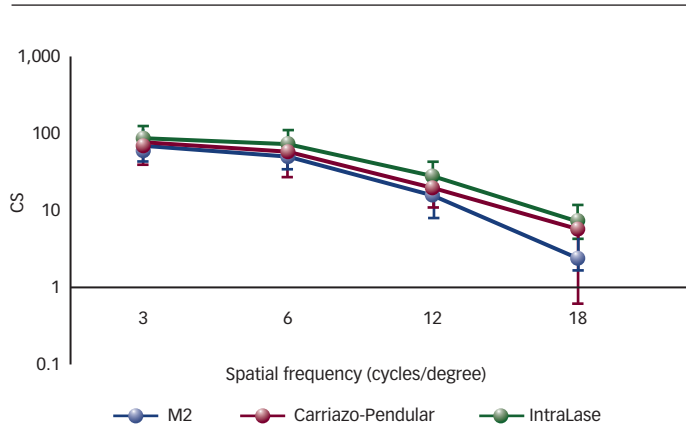
Intra-operative complications with femtosecond laser systems have been rare. However, mechanical complications have been observed,

Figure 2: Percentage of Eyes 20/20 or Better by Flap Creation Method



The percentage of eyes that achieved uncorrected visual acuity of 20/20 or better was higher in the femtosecond laser group at all time-points. Source: Tanna et al., 2009.²⁷

Figure 3: Mechanical Microkeratome versus Femtosecond Laser Contrast Sensitivity Results



Changes in contrast sensitivity (CS) function under scotopic conditions (3 cd/m²) for the three groups. Four spatial frequencies (3, 6, 12, and 18 cpd/m²) were analyzed using the Functional Acuity Contrast Tester (FACT) chart. Source: Alió and Piñero, 2008.³²

specifically the possibility of a bubble breakthrough in the area of a focal scar, where the stromal strength is insufficient to resist the passage of expanding bubbles anteriorly beneath the applanation plate, and flap tears, where resistance in separation of the flap during dissection can lead to unwanted externalization of the spatula through the flap.

The most common early finding was the presence of an opaque bubble layer (OBL) that obscured the features of the anterior segment and rendered iris tracking or pupil tracking unreliable. This OBL resolved over the course of minutes to hours and without any apparent long-term effects.¹⁷ Modern-day femtosecond laser systems, with smaller spot sizes and lower energies, appear to have largely eliminated this problem. The higher incidence of diffuse lamellar keratitis noted with early femtosecond laser systems appeared related to the inflammatory response of photodisruption.¹⁵ As with the incidence of OBL, lower energy, smaller spot systems appear to have the potential to reduce the inflammatory response, as seen in studies comparing progressive upgrades of the IntraLase laser system.^{5,18,19}

Transient light-sensitivity syndrome is characterized by photophobia and mild pain that can appear days or weeks after surgery and then persist for multiple weeks. Rainbow glare is an optical side effect due to light scattering from the perfect array of laser spots remaining on the back surface of the flap. It can create a spectral pattern whose visual impact is clinically inconsequential in the majority of patients. Both of these situations are predominately related to earlier, femtosecond laser devices using higher raster energies and lower numerical aperture optics.^{21,22}

Surgical Considerations

There are several important differences in the procedural steps used in making a flap with a mechanical microkeratome versus the femtosecond laser. The essential step in using a femtosecond laser system is to effectively dock the interface that connects the cornea to the laser. There is no blade to handle, and no mechanical parts to align, such as are present when a mechanical microkeratome is used. Studies suggest that 25–100 eyes are required to become comfortably familiar with the operation of a new microkeratome.^{9,23} Flap creation with the mechanical microkeratome can be performed on the same patient bed as is used for the subsequent excimer laser refractive shaping. A separate station, or a translating bed, is required when using a femtosecond laser system. As noted earlier, there are more limitations restricting the use of a mechanical microkeratome versus a femtosecond laser system. Extremely flat or steep eyes are unsuitable for mechanical flap creation because of the potential for buttonhole, free cap or other flap complications.

Clinical Outcomes

There is ample evidence that laser refractive surgery is a safe and effective treatment for the correction of refractive error in the vast majority of appropriately selected patients. There appear to be no major differences in the basic surgical outcomes between mechanical microkeratomes and femtosecond laser systems,^{24,25} but minor differences have been reported. One study of hyperopic patients shows significantly better refractive results with flaps created with a femtosecond laser versus a microkeratome.²⁶ It is possible that the generally flatter geometry of the hyperopic eye is a factor. In a study of over 2,000 eyes, Tanna et al. reported similar refractive accuracy between the two flap creation methods. However, they noted a higher percentage of eyes with 20/20 visual acuity when using the femtosecond laser at all time-points (one week to three months post-operatively), and a higher percentage of eyes with 20/16 acuity at three months (see *Figure 2*).²⁷

More detailed analyses of optical quality have also been performed, suggesting that femtosecond laser flaps improve the overall optical quality. Higher order aberrations have been reported to be significantly lower with femtosecond laser flaps than with mechanical microkeratome flaps.^{28,29} Although in one study the results were equivalent,³⁰ there are no studies that suggest better wavefront results with a mechanical microkeratome. When spherical aberration is combined with decentration, the resulting aberration is coma, so the laser's ability to better center the flap may explain lower levels of observed coma with femtosecond laser LASIK.³¹

Alió and Piñero noted differences in the flap geometry for microkeratomes and femtosecond laser flaps, and reported relatively

better contrast sensitivity at higher spatial frequencies with the femtosecond flaps, despite equivalent correction of sphere and cylinder. The improvement was ascribed to differences in the post-operative higher order aberrations (see *Figure 3*).³²

Upside Potential

While the potential for future improvements in a current technology may not affect the patient undergoing LASIK surgery today, the surgeon's adoption of any given technology is often made with a longer-term view.

With regard to mechanical microkeratomers, there appears to be little that can be done to address the current limitations they face. Improved blades and designs will not affect the uniformity of the flap created—the flap thickness variability and meniscus shaped profile cannot be overcome. Mechanical microkeratomers are affected by the physiological variability (e.g., extent of compression of the corneal tissue on appplanation, which affects achieved flap thickness and diameter) and anatomical variability (e.g., very steep or very flat) of the human cornea. This places a lower limit on the overall variability that can be achieved. Flap complications, while rare, tend to be mechanical in nature (partial flaps, buttonholes, flap tears) and these can have a permanent effect on the optical quality of the eye. These factors are difficult to 'design out' of mechanical microkeratomers, suggesting that any technological improvements are unlikely to affect the principal limitations of the procedure.

Further improvement in femtosecond laser technology, on the other hand, would appear less constrained. Continued refinement of laser pulse energy, frequency and spot size has occurred over the past decade and there is no evidence that a limit to this has yet been reached. The electronic systems that measure the eye and control the procedure may benefit from new imaging and biometric technologies that have become available in the past few years (e.g., spectral domain OCT). Because flaps can be programmed in a wide variety of

configurations there is the potential to discover an optimal edge profile, or an optimal overall shape. Specific flap configuration based on pre-operative keratometry or refractive error is theoretically possible with a femtosecond laser, but not with a mechanical microkeratome; the clinical advantage of this has not yet been determined. An important step in this ability to customize the flap is connectivity. As an example of preparing for this capability, the Wavelight FS200 system can connect to the Wavelight Allegretto® excimer laser, allowing the surgeon to view the planned ablation profile on the femtosecond laser screen. Given the above, it may be stated that the potential for technological improvement would appear higher for femtosecond laser systems than for mechanical microkeratomers.

Conclusion

The ability to control flap size, location and overall thickness is significantly higher with femtosecond laser systems. Variability in flap geometry is significantly higher with mechanical microkeratomers. The vertical side walls that most femtosecond laser systems create improves flap adhesion post-operatively and reduces the likelihood of epithelial ingrowth. The ability to precisely program the flap pattern minimizes the likelihood of a buttonhole or free flap. The limitations on how steep or flat an eye may be with a mechanical microkeratome do not apply with the femtosecond laser systems. Measurement of higher-order aberrations and quality of vision (e.g., low contrast acuity) suggest that flap creation with a femtosecond laser improves post-operative optical quality. Early generation laser systems introduced post-operative inflammatory complications in a percentage of patients that have largely been addressed through subsequent system modifications (lower energy, smaller spot sizes). Operative complications are significantly lower than with blades and patient appreciation of bladeless surgery appears high. It can be stated, then, that the body of evidence in the literature now supports femtosecond laser technology as superior to mechanical microkeratomers for the creation of LASIK flaps in refractive surgery. ■

- Ratkay-Traub I, Juhasz T, Horvath C, et al., Ultra-short pulse (femtosecond) laser surgery: initial use in LASIK flap creation, *Ophthalmol Clin North Am*, 2001;14(2):347–55, viii–ix.
- Reggjani-Mello G, Krueger RR, Comparison of commercially available femtosecond lasers in refractive surgery, *Expert Rev Ophthalmol*, 2011;6(1):55–65.
- Salomão MQ, Wilson SE, Femtosecond laser in laser *in situ* keratomileusis, *J Cataract Refract Surg* 2010;36(6):1024–32.
- Sonigo B, Iordanidou V, Chong-Sit D, et al., In vivo corneal confocal microscopy comparison of intralase femtosecond laser and mechanical microkeratome for laser *in situ* keratomileusis, *Invest Ophthalmol Vis Sci*, 2006;47(7):2803–11.
- Santhiago MR, Wilson SE, Cellular Effects After Laser *In Situ* Keratomileusis Flap Formation With Femtosecond Lasers: A Review, *Cornea*, 2012;31(2):198–205.
- Bechtel B, Cimberle M, Femtosecond laser use in US increasing, but some still prefer microkeratomers, *Ocular Surgery News*, June 10, 2009. Available at: www.osnsupersite.com/view.aspx?rid=40118 (accessed March 02, 2012).
- Gimbel HV, Penno EE, van Westenbrugge JA, et al., Incidence and management of intraoperative and early postoperative complications in 1000 consecutive laser *in situ* keratomileusis cases, *Ophthalmology*, 1998;105:1839–48.
- Doane JF, Stechshulte SU, Moles S, Mechanical Microkeratomers: Creation of a Meniscus, not a Planar Flap, Presented at: ASCRS/AOSA Annual Meeting, April 30, 2001, San Diego, CA.
- Paschalis EI, Labiris G, Aristeidou AP, et al., Laser *in situ* keratomileusis flap-thickness predictability with a pendular microkeratome, *J Cataract Refract Surg*, 2011;37(12):2160–6.
- Von Jagow B, Kohnen T, Corneal architecture of femtosecond laser and microkeratome flaps imaged by anterior segment optical coherence tomography, *J Cataract Refract Surg*, 2009;35(1):35–41.
- Murakami Y, Manche EE, Comparison of intraoperative subtraction pachymetry and postoperative anterior segment optical coherence tomography of laser *in situ* keratomileusis flaps, *J Cataract Refract Surg*, 2011;37(10):1879–83.
- Ahn H, Kim JK, Kim CK, et al., Comparison of laser *in situ* keratomileusis flaps created by 3 femtosecond lasers and a microkeratome, *J Cataract Refract Surg*, 2011;37(2):349–57.
- Javaloy J, Vidal MT, Abdelrahman AM, et al., Confocal microscopy comparison of intralase femtosecond laser and Moria M2 microkeratome in LASIK, *J Refract Surg*, 2007;23(2):178–87.
- Moshirfar M, Gardiner JP, Schliesser JA, et al., Laser *in situ* keratomileusis flap complications using mechanical microkeratome versus femtosecond laser: retrospective comparison, *J Cataract Refract Surg*, 2010;36(11):1925–33.
- Gil-Cazorla R, Teus MA, de Benito-Llopis L, Fuentes J, Incidence of diffuse lamellar keratitis after laser *in situ* keratomileusis associated with the Intralase 15 kHz femtosecond laser and Moria M2 microkeratome, *J Cataract Refract Surg*, 2008;34(1):28–31.
- Kamburoglu G, Ertan A, Epithelial ingrowth after femtosecond laser-assisted *in situ* keratomileusis, *Cornea*, 2008;27(10):1122–5.
- Kaiserman I, Maresky HS, Bahar I, Rootman DS, Incidence, possible risk factors, and potential effects of an opaque bubble layer created by a femtosecond laser, *J Cataract Refract Surg*, 2008;34(3):417–23.
- Haft P, Yoo SH, Kymionis GD, et al., Complications of LASIK flaps made by the Intralase 15- and 30-kHz femtosecond lasers, *J Refract Surg*, 2009;25(11):979–84.
- Choe CH, Guss C, Musch DC, et al., Incidence of diffuse lamellar keratitis after LASIK with 15 KHz, 30 KHz, and 60 KHz femtosecond laser flap creation, *J Cataract Refract Surg*, 2010;36(11):1912–8.
- Stonecipher KG, Dishler JG, Ignacio TS, Binder PS, Transient light sensitivity after femtosecond laser flap creation: clinical findings and management, *J Cataract Refract Surg*, 2006;32(1):91–94.
- Krueger RR, Thornton IL, Xu M, et al., Rainbow glare as an optical side effect of IntraLASIK, *Ophthalmology*, 2008;115(7):1187–95.
- Bamba S, Rocha KM, Ramos-Esteban JC, Krueger RR, Incidence of rainbow glare after laser *in situ* keratomileusis flap creation with a 60 kHz femtosecond laser, *J Cataract Refract Surg*, 2009;35(6):1082–6.
- Al-Swailem SA, Wagoner MD, Complications and visual outcome of LASIK performed by anterior segment fellows vs experienced faculty supervisors, *Am J Ophthalmol*, 2006;141(1):13–23.
- Li H, Sun T, Wang M, Zhao J, Safety and effectiveness of thin-flap LASIK using a femtosecond laser and microkeratome in the correction of high myopia in Chinese patients, *J Refract Surg*, 2010;26(2):99–106.
- Zhang ZH, Jin HY, Suo Y, et al., Femtosecond laser versus mechanical microkeratome laser *in situ* keratomileusis for myopia: Meta-analysis of randomized controlled trials, *J Cataract Refract Surg*, 2011;37(12):2151–9.
- Gil-Cazorla R, Teus MA, de Benito-Llopis L, Mikropoulos DG, Femtosecond laser vs mechanical microkeratome for hyperopic laser *in situ* keratomileusis, *Am J Ophthalmol*, 2011;152(1):16–21.
- Tanna M, Schallhorn SC, Hettinger KA, Femtosecond laser versus mechanical microkeratome: a retrospective comparison of visual outcomes at 3 months, *J Refract Surg*, 2009;25(7 Suppl):S668–71.
- Medeiros FW, Stapleton WM, Hammel J, et al., Wavefront analysis comparison of LASIK outcomes with the femtosecond laser and mechanical microkeratomers, *J Refract Surg*, 2007;23(9):880–7.
- Krueger RR, Dupps WJ Jr, Biomechanical effects of femtosecond and microkeratome-based flap creation: prospective contralateral examination of two patients, *J Refract Surg*, 2007;23(8):800–7.
- Calvo R, McLaren JW, Hodge DO, et al., Corneal aberrations and visual acuity after laser *in situ* keratomileusis: femtosecond laser versus mechanical microkeratome, *Am J Ophthalmol*, 2010;149(5):785–93.
- Buzzonetti L, Petrocelli G, Valente P, et al., Comparison of corneal aberration changes after laser *in situ* keratomileusis performed with mechanical microkeratome and IntraLase femtosecond laser: 1-year follow-up, *Cornea*, 2008;27(2):174–9.
- Alió JL, Piñero DP, Very high-frequency digital ultrasound measurement of the LASIK flap thickness profile using the Intralase femtosecond laser and M2 and Carriazo-Pendular microkeratomers, *J Refract Surg*, 2008;24(1):12–23.