

Viral Aetiology in Anterior Uveitis – The Tip of an Iceberg?

Dicle Hazirolan¹ and Uwe Pleyer²

1. Senior Resident, Ankara Training and Research Hospital, Ministry of Health, Department of Ophthalmology, Ankara, Turkey;

2. Professor, Department of Ophthalmology, Charité Hospital, Charité Campus Virchow-Klinikum, Humboldt University, Berlin, Germany

Abstract

Identification of an infectious cause in intraocular inflammation is of crucial importance since their treatment and prognosis differ from non-infectious aetiologies. Herpes simplex and varicella-zoster viruses are well known causes of anterior uveitis. Furthermore, cytomegalovirus (CMV) and rubella virus (RV) are also detected in a significant number of patients. Despite their different aetiology, viral anterior uveitis may have similar features and often presents with unilateral diffuse, fine, stellate keratic precipitates, iris atrophy or ocular hypertension. Viruses are increasingly recognised as aetiology of anterior uveitis that has previously been referred as idiopathic. RV, for example, causes a distinct clinical spectrum of ocular signs and symptoms presenting as Fuch's uveitis syndrome (FUS) in Europe, strongly suggesting a role in its pathogenesis. Interestingly, CMV may also be involved in the pathogenesis of both FUS and Posner–Schlossman syndrome in particular in the Asian population.

Keywords

Anterior uveitis, cytomegalovirus, Fuch's uveitis syndrome, herpes simplex virus, Posner–Schlossman syndrome, rubella virus, varicella-zoster virus

Disclosure: The authors have no conflicts of interest to declare.

Received: 16 December 2011 **Accepted:** 1 February 2012 **Citation:** *European Ophthalmic Review*, 2012;6(2):119–24 DOI: 10.17925/EOR.2012.06.02.119

Correspondence: Dicle Hazirolan, Eryaman 2, Etap, Demire A1-1 Blok, No:54, Ankara, Turkey. E: dicleoncel@hotmail.com

Intraocular viral infections have various presentations. They may be detected as anterior uveitis, intermediate uveitis, acute retinal necrosis (ARN), progressive outer retinal necrosis (PORN) and neuroretinitis (see *Figure 1*).^{1,2}

Anterior uveitis (AU) in most patients is either idiopathic or associated with HLA-B27 positivity. However, a viral cause of AU is often underestimated. The most common viruses in the aetiology of viral AU (VAU) are herpes simplex virus (HSV), varicella-zoster virus (VZV), cytomegalovirus (CMV) and rubella virus (RV).^{1–3}

Recently, the aetiology of some 'idiopathic' AU syndromes are proved to be viral. RV and CMV, for example, cause a distinct clinical spectrum of ocular symptoms presenting as Fuch's Uveitis syndrome (FUS) which strongly suggest that they might be involved in the pathogenesis of FUS.^{4,5} Interestingly, CMV may also be involved in the pathogenesis of Posner-Schlossman syndrome (PSS).^{4,6}

Diagnosis of VAU depends mostly on clinical findings. The clinical features commonly described in association with VAU include diffuse, fine, stellate or dendritiform keratic precipitates, ocular hypertension and iris atrophy.^{4,5,7–14} Although clinical features of different VAUs overlap, there are some characteristic findings depending on the causative viral agent.

In this review, the clinical features of the most common VAUs (HSV, VZV, CMV and RV) are presented.

Herpes Viridae Family (Herpes Simplex Virus, Varicella-zoster Virus, Cytomegalovirus)

These DNA viruses are ubiquitous and following primary infection, lifelong latency is a characteristic feature. The three main viruses responsible for ocular inflammation are HSV-1, VZV and CMV. Epstein-Barr virus (EBV) and HSV-2 have also infrequently been detected in ocular disease.¹⁵

The worldwide seroconversion to herpes viruses ranges from 60 to 90%.^{16–21} VAU, due to either HSV or VZV is reported to be 5 to 10% of all uveitis cases.^{22,23} However, other viruses such as CMV and RV are also increasingly being implicated as causative factors, particularly in patients presenting with hypertensive AU.^{4,5,7–11}

Interestingly, the clinical features of herpetic ocular infection depend to a certain extent on the immune status of the patient. CMV infection, for example, predominantly manifests as retinitis in immunocompromised patients.^{24,25} In contrast, it almost always occurs as AU in otherwise healthy immunocompetent patients.^{24,25} Similarly, in VZV infection, posterior segment involvement is more likely to occur in immunocompromised patients and they are also more likely to develop chronic disease.²⁶

Herpes Simplex Virus and Varicella Zoster Virus

These two herpes viruses share certain common features in their manifestations and treatment. Frequently, uveal inflammation associated with herpes viruses evolves as keratoiritis associated to corneal disease (see *Figure 2*). However, HSV associated AU may also

Table 1: Systemic Antiviral Therapy in Herpetic Anterior Uveitis

	Aciclovir	Valaciclovir	Famciclovir	Brivudin
Daily dose	5 x 400 mg (5 x 800 mg)* p.o.	3 x 500 mg (3 x 1,000 mg)* p.o.	3 x 250 mg (3 x 500)* mg p.o	1 x 125 mg p.o.
Treatment period	3–6 weeks or more	3–6 weeks or more	3–6 weeks or more	1–2 weeks
Side effects	Increase in blood creatinine levels	Increase in blood creatinine levels, thrombocytopenic purpura	Headache, diarrhoea	Nausea

*In varicella-zoster uveitis. p.o. = per oral.

Table 2: Comparison of Clinical Findings in Viral Anterior Uveitis

	HSV	VZV	CMV	Rubella
Age of patients at presentation	Older (but younger than VZV)	Older	Younger in PSS like uveitis, older in FUS	Younger
Course of disease	Acute recurrent and less commonly chronic	acute recurrent and less commonly chronic	Acute recurrent and less commonly chronic	Chronic, rarely acute
Intraocular pressure	↑	↑↑↑	↑↑↑	↑
Corneal involvement KP	20–60 % keratitis, fine granulosomatous KP	20–60 % keratitis, mostly granulosomatous KP	Rare corneal involvement, predominantly isolated endothelitis, stellate granulosomatous KP	Rare corneal involvement, fine, stellate KP
Anterior chamber reaction	+++	++	+	+
Iris stromal atrophy	+	++	Heterochromia*	Heterochromia
Posterior synechia	++	+++	-	-
Vitreous involvement	+	++	++	+++
Therapy/prognosis	Acyclovir/valacyclovir Favourable, long-term prophylaxis is required	Moderate-favourable	Variable, depends on secondary ocular hypertension	Moderate-favourable

*Heterochromia in dark irides may be overlooked. ↑ = mild increase; ↑↑↑ = high increase; + = mild; ++ = moderate; +++ = severe; KP = keratic precipitates; FUS = Fuchs' uveitis syndrome; VZV = varicella-zoster virus.

occur without noticeable keratitis and may therefore be more difficult to diagnose.¹²

The prevalence of HSV-1 is generally higher than that of HSV-2 and increases in a linear fashion with age. Seroconversion in adults is about 60 to 90 % worldwide¹⁶ Although the prevalence of HSV is high, ocular involvement in HSV-infected patients is relatively uncommon and has been estimated to be about 1 %.²⁷ The prevalence of VZV AU is often relatively low and was reported to account for 10–13 % of all herpetic AU patients.^{12,14} This assumption might be incorrect since, even in the absence of skin lesions, VZV AU is not uncommon and known as 'varicella zoster sine herpete'.²⁸ VZV is known to be the aetiological agent of two clinically distinct diseases: varicella (chickenpox) and herpes zoster (shingles).²⁹ While varicella is the primary infection of VZV, zoster is its secondary infection caused by re-activation of VZV from latency.²⁹ Approximately 90 % of children worldwide are VZV seropositive. Thirty per cent of the elderly experience a reactivation of the latent VZV resulting in a herpes zoster infection, of whom about 10 to 25 % develop herpes zoster ophthalmicus (HZO).^{30,31} The risk of VZV infection in AIDS patients is significantly higher³² and it may be an early sign of HIV infection.³³

Herpetic AU may be accompanied by dermatitis, conjunctivitis, keratitis, scleritis, or retinitis.^{34–38} It is almost always unilateral and patients most frequently complain of blurred vision, eye pain, redness and photophobia.^{39,40} Herpetic AU usually follows an acute recurrent course.⁴¹ Anterior chamber inflammation may be mild or severe and may even produce a hypopyon or hyphaema.⁴⁰ Keratic precipitates may appear small, large, or stellate and collect frequently at areas of active keratitis.^{22,40} Posterior synechiae are common.^{22,40} Many patients also have decreased corneal sensation,¹² an acute rise in the

intraocular pressure (IOP),^{12,13,23,34,41,42} and patchy, sectoral (see *Figure 3*), or even diffuse iris atrophy.^{23,36,37,43–45} Sectoral iris atrophy, which results from ischaemic necrosis of the stroma, is a frequent diagnostic sign in patients suffering from herpetic AU.^{45,46}

The acute increase in IOP has been attributed to inflammation of the trabecular meshwork.³⁴ This notion is supported by the observation that intraocular pressure typically normalises in response to topical corticosteroid therapy.^{34,42} Active keratitis or findings of a previous corneal scar are frequently associated with herpetic AU. Dendritic or geographic ulcers, stromal keratitis and endotheliitis are signs of active herpetic keratitis. Dermatome vesicular rash involving the ophthalmic division of the trigeminal nerve in patients with VZV, and the peri-ocular area in patients with HSV may also help to distinguish herpetic AU.³ However, in patients with isolated anterior chamber involvement, it is often difficult to determine the causative agent without aqueous humor analysis.

VZV ocular involvement after primary varicella infection is uncommon and may present as uveitis, interstitial keratitis, corneal ring infiltrate, or internal ophthalmoplegia.^{13,47,48} Ophthalmic involvement typically occurs as part of HZO.

As both HSV and VZV can present similar findings, distinguishing between the two viruses may be quite challenging.²² History and clinical examination may help to determine which virus is more likely the causative agent in some patients.^{22,23} HSV usually affects children and young adults, whereas VZV is more commonly seen in elderly and immunocompromised patients. Skin lesions in HSV patients usually consist of grouped vesicles, whereas in VZV patients they involve a dermatome among the distribution of ophthalmic nerve. The pattern of dendritic keratitis, when present, may also help to differentiate HSV

from VZV uveitis. HSV dendrites are usually branching, with well-developed terminal end bulbs that tend to show fluorescein staining in the ulcer base and rose bengal staining at the border. VZV pseudodendrites, in contrast, are usually slightly elevated, broader and polymorphous, with less regular branching, few terminal end bulbs and central rose bengal staining with fluorescein pooling along the edge.⁴⁹

Treatment for herpetic AU should be primarily directed against the infectious agent. In addition, anti-inflammatory medications such as topical or even systemic corticosteroids are needed. Cycloplegic agents are often indicated to prevent formation of synechiae during the acute stage of intraocular inflammation.⁵⁰ Topical antiviral agents are usually ineffective in the treatment of AU but may be indicated in patients with herpes simplex keratouveitis to prevent dendritic keratitis during topical corticosteroid treatment.⁵¹ Systemic antivirals such as (val)acyclovir, famciclovir, or brimidine are the mainstay of therapy and prevention of recurrences in patients with severe uveitis.⁵² Table 1 summarises the systemic antiviral therapy in herpetic AU. Initiation of oral antiviral therapy within the first few days after the onset of varicella-zoster is recommended.³⁷ Patients with herpetic uveitis may require prolonged corticosteroid therapy with very gradual tapering.^{51,52} Systemic corticosteroids may be necessary at times. The oral dosages are acyclovir 400 mg five times daily or valacyclovir 500 mg two times daily for patients with HSV and acyclovir 800 mg five times daily or valacyclovir 1,000 mg three times daily for VZV disease.⁵² Oral acyclovir, 600 to 800 mg/day, has been shown to diminish the number of recurrences in patients with herpetic AU when given on a long-term basis.⁵³ Oral acyclovir/valacyclovir has been shown to reduce the incidence and severity of ocular complications, including AU, when given for 10 days starting within 72 hours of onset of skin lesions in patients with herpes zoster ophthalmicus.^{37,54} Topical and oral ocular antihypertensive agents are often necessary to control the ocular hypertension, especially during the first days of treatment.

Cytomegalovirus

CMV is the most common congenital viral infection, with clinical disease occurring among neonates and immunocompromised patients. CMV infection is ubiquitous worldwide. The seroprevalence of CMV was reported to be between 60 to 90 %.^{17,55-60}

CMV retinitis is the most common ophthalmic manifestation of both congenital CMV infection and that occurring in the immunocompromised patient.^{24,61} Anterior segment involvement in immunocompromised patients is less frequent and usually is mild.⁶¹ However, in immunocompetent patients, CMV has been found in association with corneal endotheliitis as well as AU associated with elevated intraocular pressure (IOP).^{7,8,62-65}

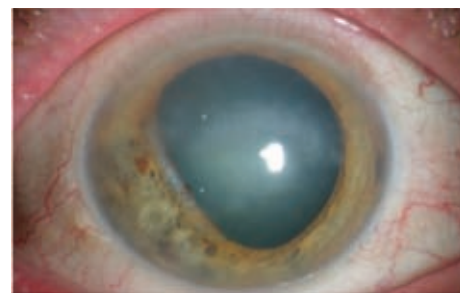CMV AU may present as ‘acute recurrent AU’ associated with ocular hypertension (resembling PSS) or ‘chronic AU’, which may be complicated by glaucoma (resembling FUS).^{4,24,25,66} In CMV AU, the anterior chamber inflammation is mild and posterior synechiae do not develop.^{4,24,25} Typically, the posterior segment is uninvolved.^{4,24,25} The frequency of acute CMV AU is reported to be approximately two times higher than the chronic CMV AU.^{4,66}

Acute recurrent AU (CMV associated PSS) typically presents in middle-aged patients, with unilateral involvement. It is characterised

Table 3: Comparison of Polymerase Chain Reaction versus Antibody Detection in Aqueous Humor in Anterior Viral Uveitis

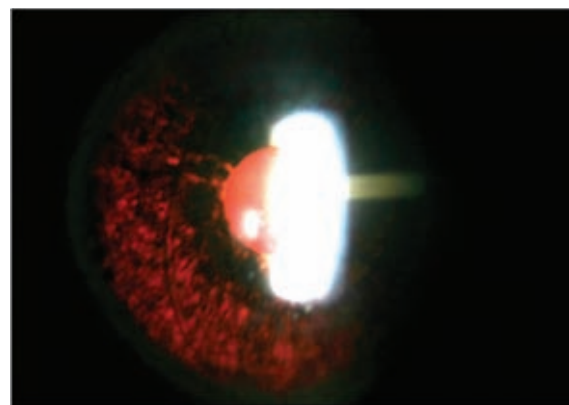
	Polymerase Chain Reaction	Antibody Testing
Detection of micro-organism	Directly (DNA/RNA)	Indirectly
Sensitivity	Low (due to small amount of sample size)	Higher
Higher values of positive test results	In the early stage of the disease	In the late stage of the disease
Sensitivity of detecting Herpesviridea	Higher	Lower
Sensitivity of detecting rubella virus	Lower	Higher

Figure 1: Clinical Presentation of Acute Anterior caused by Herpes Simplex Virus



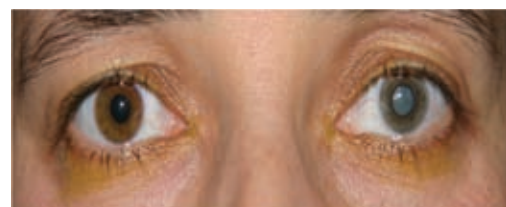Note residual cornea opacity, fine precipitates and irregular pupil. The aetiology was confirmed by presence of intraocular antibody synthesis.

Figure 2: Varizella zoster anterior Uveitis with Sectoral Iris Atrophy



The presence of chronic anterior uveitis (AU), fine precipitates, heterochromia, early cataract formation and vitreous cells are classical findings. Antibody synthesis directed against rubella virus could be detected.

Figure 3: Characteristic Clinical Presentation in a Patient with Fuchs Uveitis Syndrome



The presence of chronic anterior uveitis (AU), fine precipitates, heterochromia, early cataract formation and vitreous cells are classical findings. Antibody synthesis directed against rubella virus could be detected.

by recurrent episodes of mild iritis, associated with elevated IOP and diffuse epithelial oedema of the cornea and few fine keratic precipitates. The IOP is normal between attacks, and anterior chamber angle is open.⁶⁶ Iris atrophy may occur and it is either patchy or diffuse, and is present in 15 % of eyes.⁶⁶ IOP may exceed 50 mmHg during the attacks and 8–23 % of eyes develop glaucomatous optic neuropathy.⁶⁶

Chronic AU (CMV associated FUS), contrary to rubella-associated FUS, is seen at older ages (mean age of 65)^{4,66} and occurs mostly in males.^{4,5,41,66} Interestingly, most reports of CMV FUS refer to Asian patients, whereas FUS in Europe is more closely related to RV. The eye is minimally inflamed and presents with diffuse, fine and stellate keratic precipitates fairly evenly distributed over the endothelium.^{4,66} Typical signs are corneal endothelial lesions appearing as white, medium-sized, nodular lesions surrounded by a translucent halo, which are significantly associated with chronic CMV uveitis.^{4,66} The anterior chamber activity in these eyes is mild and in 60 % of eyes, diffuse iris atrophy is present.^{4,66} Glaucomatous optic neuropathy develops in 36 % and posterior subcapsular cataract in 75 % of eyes.⁴ Patches of focal endotheliitis may be also observed.⁴ Vitritis may also be detected.⁶⁶

Ganciclovir (and its prodrug valganciclovir) is the only currently used therapy in the management of CMV infections.^{4,25} Various options of ganciclovir application exist including topical and systemic administration. Even intraocular treatment using intravitreal implants or intravitreal injections have been suggested.²⁵ A positive response to ganciclovir therapy was reported in up to 75 % of affected patients, however, recurrences were reported after cessation of treatment in three out of four patients raising the question of preventive measures.²⁵ Chee et al.²⁵ reported that long-term topical ganciclovir application resulted in a lower recurrence rate and less severe adverse effects as compared to systemic ganciclovir or device implantation. Therefore, they suggested topical ganciclovir therapy in CMV AU. In addition to antiviral therapy, topical corticosteroids and/or non-steroidal anti-inflammatory drugs (NSAIDs) may be useful in reducing ocular inflammation. In selected patients with uncontrolled intraocular pressure, glaucoma medications and/or surgery might be still necessary in the management of CMV AU.^{4,25}

Rubella Virus

The RV is the prototypical teratogenic viral agent. It is transmitted via airborne droplets and epidemics were common worldwide before the rubella vaccine became available. Ocular findings of congenital rubella syndrome include chorioretinitis, cataract, corneal clouding, microphthalmia, strabismus and glaucoma.⁶⁷ Acquired ocular rubella infections usually result in mild self-limiting conjunctivitis (70 %) or keratitis.¹ Posterior segment involvement after RV infection is rare, but includes active chorioretinitis with mild AU, pigment epithelial detachment and overlying bullous retinal detachment. It also may present as bilateral severe panuveitis with deep corneal stromal involvement.⁶⁸

A number of studies have now shown that a high proportion of patients with features characteristic of FUS have antibodies directed against RV. To a lower extent, RV ribonucleic acid (RNA) can be detected in the aqueous humor of the affected eye.^{9–11,41,69} The association of RV with FUS might be indirectly supported by the observation that the prevalence of FUS in the US has decreased

dramatically since the introduction of a universal, population-based rubella vaccination programme.⁶⁹ The existence of RV-associated AU is further supported by the identification of RV RNA from eyes of patients who developed transient conjunctivitis and uveitis following vaccination with live vaccines.^{70,71} The occurrence of iris atrophy, iridocyclitis and cataract as late ocular complication of congenital RV infection also supports the RV-associated AU.^{72–74}

Fuch's uveitis syndrome is an intraocular inflammatory disease that accounts for up to 6.2 % of all uveitis patients.^{75,76} Its aetiology remained unknown until a few years ago. More recently, evidence has accumulated that infectious agents are related to FUS. Interestingly, in Europe, RV has been identified in almost all patients, whereas in Asia, CMV has been strongly suggested to be involved in the pathogenesis of FUS.^{4,11,41} FUS occurs in more than 90 % unilaterally. Common clinical manifestations are the presence of a chronic persistent AU, presenting with diffuse, fine, stellate keratic precipitates, diffuse iris atrophy and/or heterochromia (see *Figure 4*). The absence of synechiae, posterior subcapsular cataract formation, vitritis and sectoral peripheral retinal vascular leakage with disc hyperfluorescence are further characteristics. Despite persistent vitritis as one of the most frequent clinical findings in FUS, a cystoid macular oedema is almost never seen.⁷⁷ Secondary complications such as glaucoma have been reported in up to 59 % and vitritis in up to 90 % of all patients with FUS.^{78,79} Patients may remain asymptomatic for years and the diagnosis is often delayed until the visual acuity is affected e.g. due to early cataract progression. The prognosis is favourable in most patients even though the persistent inflammation. Corticosteroids may modulate intraocular inflammation at the anterior segment, but typically fail to resolve it and do not affect vitreous infiltration. Many experts advice to avoid steroids since the risk of cataract progression and secondary glaucoma increases, whereas the benefit of steroid treatment is rather limited.⁸⁰ Cycloplegia is almost never necessary. Since no specific antiviral treatment is available to modulate the clinical course of RV AU, treatment is reserved to sight threatening complications such as cataract, glaucoma and vitreous opacification.⁸¹

Conclusions

The diagnosis of VAU mainly depends on clinical findings. The summary of the demographics, clinical course, ocular findings and laboratory testing that helps to differentiate the causative viral agent is as follows.

Demographics

Patients with rubella-associated AU (mean age 35 ± 12 years) are younger than patients with HSV-associated AU (mean age 43 ± 15 years), who in turn tended to be younger than patients with VZV-associated AU (mean age 53 ± 23 years).⁴¹ On the other hand, acute recurrent CMV AU patients (mean age 37 ± 12 years) are younger than the chronic CMV AU patients (mean age 65 years).⁴

Clinical Course

The disease course is much more frequently chronic in RV-associated AU (96 %) as compared with HSV (39 %), VZV (40 %) and CMV-associated AU (37 %).⁶⁶

Anterior Chamber Activity

Inflammatory activity in RV and CMV AU typically is mild.^{4,41} HSV AU is characterised by a more severe anterior segment inflammation.⁴¹

The involvement of the vitreous, however, is more prominent in RV, VZV and CMV AUs patients as compared to HSV AU patients.

Iris Changes

Iris heterochromia is considered an important diagnostic feature for RV AU but may also be present in any other VAU.⁴¹ Diffuse iris atrophy without heterochromia is also frequently seen in chronic CMV AU.⁶⁶ As CMV infection is mostly detected in dark-coloured Asian eyes, heterochromia may be overlooked.⁶⁶ Focal, specifically sectorial, iris atrophy is, however, more characteristic of HSV and VZV AU.^{12,14,22,60} Posterior synechia is more commonly present in HSV and VZV AU. It is rare in RV and CMV AU.^{4,41,66}

Cataract

Cataract at presentation and iris heterochromia are more common in RV AU and chronic CMV AU.^{4,41,66}

Intraocular Pressure

High intraocular pressure during active inflammation and development of secondary glaucoma is a known complication of VAU. The prevalence of IOP more than 30 mmHg and glaucoma is similar in HSV, VZV, CMV and RV AU.⁴¹ However, higher levels of IOP were detected in CMV AU, especially in the acute recurrent (PSS) type.⁴

Fundus Findings

Focal chorioretinal scars have been occasionally described in RV and VZV AUs.^{41,82}

Laboratory Testing

Since clinical differentiation of the infectious from non-infectious uveitis, and identification of certain causative viral agent may be quite challenging, laboratory testing may be needed. Serological testing for virus antibodies is rarely useful in a patient with VAU. This is because a majority of adults are seropositive for herpesviridae and RV even without a clear clinical history of disease.⁸³ Analysis of aqueous humor is much more valuable than serological testing. Laboratory testing can be performed either by detection of viral DNA/RNA (PCR) or analysis of anti-viral antibodies (Goldmann-Witmer coefficient) in aqueous humor samples. Polymerase chain reaction (PCR) and antibody detection are different testing methods and have different results for different micro-organisms.⁸⁴ Comparison of PCR versus antibody detection in aqueous humor in anterior viral uveitis is shown in *Table 3*. PCR in Herpesviridae uveitis and antibody detection in rubella uveitis are probably the most commonly performed laboratory testing methods.^{6,85} ■

- Jap A, Chee SP, Emerging forms of viral uveitis in the developing world, *Int Ophthalmol Clin*, 2010; 50:155–71.
- Pleyer U, Winterhalter S, Diagnostic and therapeutic aspects of herpes virus associated uveitis, *Klin Monbl Augenheilkd*, 2010;227:407–12.
- Jap A, Chee SP, Viral anterior uveitis, *Curr Opin Ophthalmol*, 2011;22:483–8.
- Chee SP, Bacsal K, Jap A, et al., Clinical features of cytomegalovirus anterior uveitis in immunocompetent patients, *Am J Ophthalmol*, 2008;145:834–40.
- Ruokonen PC, Metzner S, Ucer A, et al., Intraocular antibody synthesis against rubella virus and other microorganisms in Fuchs' heterochromic cyclitis, *Graefes Arch Clin Exp Ophthalmol*, 2010;248:565–71.
- Takusagawa HL, Liu Y, Wiggs JL, Infectious theories of Posner-Schlossman syndrome, *Int Ophthalmol Clin*, 2011;51:105–15.
- Van Bortel LA, van der Lelij A, van der Meer J, et al., Cytomegalovirus as a cause of anterior uveitis in immunocompetent patients, *Ophthalmology*, 2007;114:1358–62.
- De Schryver I, Rozenberg F, Cassoux N, et al., Diagnosis and treatment of cytomegalovirus iridocyclitis without retinal necrosis, *Br J Ophthalmol*, 2006;90:852–5.
- De Visser L, Braakenburg A, Rothova A, et al., Rubella virus-associated uveitis: clinical manifestations and visual prognosis, *Am J Ophthalmol*, 2008;146:292–97.
- Quentin CD, Reiber H, Fuchs heterochromic cyclitis: rubella virus antibodies and genome in aqueous humor, *Am J Ophthalmol*, 2004;138:46–54.
- Suzuki J, Goto H, Komase K, et al., Rubella virus as a possible etiological agent of Fuchs heterochromic iridocyclitis, *Graefes Arch Clin Exp Ophthalmol*, 2010;248:1487–91.
- Van der Lelij A, Ooijman FM, Kijlstra A, et al., Anterior uveitis with sectorial iris atrophy in the absence of keratitis: a distinct clinical entity among herpetic eye diseases, *Ophthalmology*, 2000;107:1164–70.
- Sungur GK, Hazirolan D, Yalvac IS, et al., Incidence and prognosis of ocular hypertension secondary to viral uveitis, *Int Ophthalmol*, 2010;30:191–4.
- Tugal-Tutkun I, Otük-Yasar B, Altinkurt E, Clinical features and prognosis of herpetic anterior uveitis: a retrospective study of 111 cases, *Int Ophthalmol*, 2010;30:559–65.
- Van Gelder RN, Ocular pathogens for the twenty-first century, *Am J Ophthalmol*, 2010;150:595–7.
- Smith JS, Robinson NJ, Age-specific prevalence of infection with herpes simplex virus types 2 and 1: a global review, *J Infect Dis*, 2002;186:S3–S28.
- Wong A, Tan KH, Tee CS, et al., Seroprevalence of cytomegalovirus, toxoplasma and parvovirus in pregnancy, *Singapore Med J*, 2000;41:151–5.
- Taechowisan T, Suttthent R, Louisirirothanakul S, et al., Immune status in congenital infections by TORCH agents in pregnant Thais, *Asian Pac J Allergy Immunol*, 1997;15:93–7.
- Tooke PA, Ades AE, Peckham CS, Cytomegalovirus prevalence in pregnant women: the influence of parity, *Arch Dis Child*, 1992;67:779–83.
- Gratacap-Cavallier B, Bosson JL, Morand P, et al., Cytomegalovirus seroprevalence in French pregnant women: parity and place of birth as major predictive factors, *Eur J Epidemiol*, 1998;14:147–52.
- Sengupta N, Breuer J, A global perspective of the epidemiology and burden of varicella-zoster virus, *Curr Pediatr Rev*, 2009;5:207–28.
- Cunningham ET Jr, Diagnosing and treating herpetic anterior uveitis, *Ophthalmology*, 2000;107:2129–30.
- Tabbara KF, Chavis PS, Herpes simplex anterior uveitis, *Int Ophthalmol Clin*, 1998;38:137–47.
- Sanghera NK, Newman TL, Cytomegalovirus retinitis from chronic immunosuppression following solid organ transplant surgery, *Clin Exp Optom*, 2010;93:261–3.
- Chee SP, Jap A, Cytomegalovirus anterior uveitis: outcome of treatment, *Br J Ophthalmol*, 2010;94:1648–52.
- Westeneng AC, Rothova A, de Boer JH, et al., Infectious uveitis in immunocompromised patients and the diagnostic value of polymerase chain reaction and Goldmann-Witmer coefficient in aqueous analysis, *Am J Ophthalmol*, 2007;144:781–5.
- Matoba A, Ocular viral infections, *Pediatr Infect Dis*, 1984;3:358–68.
- Kido S, Sugita S, Horie S, et al., Association of varicella zoster virus load in the aqueous humor with clinical manifestations of anterior uveitis in herpes zoster ophthalmicus and zoster sine herpette, *Br J Ophthalmol*, 2008;92:505–8.
- Gershon AA, Varicella-zoster virus infections, *Pediatr Rev*, 2008; 29:5–11.
- Scott FT, Leedham-Green ME, Barrett-Muir WY, et al., A study of zoster and the development of postherpetic neuralgia in East London, *J Med Virol*, 2003;75(suppl 1):S24–S30.
- Ragozzino MW, Melton LJ III, Kurland LT, et al., Population-based study of herpes zoster and its sequelae, *Medicine*, 1982;61:310–6.
- Goldman GS, Universal varicella vaccination: efficacy trends and effect on herpes zoster, *Int J Toxicol*, 2005;24:205–13.
- Tyndall MW, Nasio J, Agoki E, et al., Herpes zoster as the initial presentation of human immunodeficiency virus type 1 infection in Kenya, *Clin Infect Dis*, 1995;21:1035–7.
- Falcon MG, Williams HP, Herpes simplex kerato-uveitis and glaucoma, *Trans Ophthalmol Soc UK*, 1978;98:101–4.
- Harding SP, Lipton JR, Wells JC, Natural history of herpes zoster ophthalmicus: predictors of postherpetic neuralgia and ocular involvement, *Br J Ophthalmol*, 1987;71:353–8.
- Womak LW, Liesegang TJ, Complications of herpes zoster ophthalmicus, *Arch Ophthalmol*, 1983;101:42–5.
- Cobo ML, Foulks GN, Liesegang T, et al., Oral acyclovir in the treatment of acute herpes zoster ophthalmicus, *Ophthalmology*, 1986;93:763–70.
- Liesegang TJ, Varicella-zoster virus eye disease, *Cornea*, 1999;18:311–31.
- Thygeson P, Fogli M, Kimura SJ, Observations on uveitis associated with viral disease, *Trans Am Ophthalmol Soc*, 1957–1958;55:333–49.
- Kimura SJ, Herpes simplex uveitis: a clinical and experimental study, *Trans Am Ophthalmol Soc*, 1962;60:441–70.
- Wensing B, Relvas LM, Caspers LE, et al., Comparison of rubella virus- and herpes virus-associated anterior uveitis: clinical manifestations and visual prognosis, *Ophthalmology*, 2011;118:1905–10.
- Wilhelmus KR, Falcon MG, Jones BR, Herpetic iridocyclitis, *Int Ophthalmol*, 1981;4:143–50.
- Goldstein DA, Mis AA, Deschenes JG, Iris atrophy in herpes simplex uveitis, *Invest Ophthalmol Vis Sci*, 1995;36:S150.
- Yamamoto S, Pavan-Langston D, Kinoshita S, Detecting herpesvirus DNA in uveitis using the polymerase chain reaction, *Br J Ophthalmol*, 1996;80:465–8.
- Marsh RJ, Easty DL, Jones BR, Iritis and iris atrophy in herpes zoster ophthalmicus, *Am J Ophthalmol*, 1974;78:255–61.
- Naumann G, Gass JD, Font RL, Histopathology of herpes zoster ophthalmicus, *Am J Ophthalmol*, 1968;65:533–41.
- Khan AO, Al-Asfiri A, Wagoner MD, Ring corneal infiltrate and progressive ring thinning following primary varicella infection, *J Pediatr Ophthalmol Strabismus*, 2008;45:116–7.
- Fernández de Castro LE, Sarraf OA, Hawthorne KM, et al., Ocular manifestations after primary varicella infection, *Cornea*, 2006;25:866–7.
- Piebanga LW, Laibson PR, Dendritic lesions in herpes zoster ophthalmicus, *Arch Ophthalmol*, 1973;90:268.
- Wilhelmus KR, Gee L, Hauck WW, et al., Herpetic Eye Disease Study. A controlled trial of topical corticosteroids for herpes simplex stromal keratitis, *Ophthalmology*, 1994;101:1883–95; discussion 1895–6.
- Parrish CM, Herpes simplex virus eye disease. Focal points: Clinical modules for ophthalmologists, San Francisco: American Academy of Ophthalmology, 1997;101:1871–82.
- Siverio Júnior CD, Imai Y, Cunningham ET Jr, Diagnosis and management of herpetic anterior uveitis, *Int Ophthalmol Clin*, 2002;42:43–8.
- Rodríguez A, Power WJ, Neves RA, et al., Recurrence rate of herpetic uveitis in patients on long-term oral acyclovir, *Doc Ophthalmol*, 1995;90:331–40.
- Colin J, Prisant O, Cochenor B, et al., Comparison of the efficacy and safety of valacyclovir and acyclovir for the treatment of herpes zoster ophthalmicus, *Ophthalmology*, 2000;107:1507–11.
- Seale H, MacIntyre CR, Gidding HF, et al., National Survey of cytomegalovirus in Australia *Clin Vaccine Immunol*, 2006;13:1181–4.
- Staras SA, Dollard SC, Radford KW, et al., Seroprevalence of cytomegalovirus infection in the United States, 1988–1994, *Clin Infect Dis*, 2006;43:1143–51.
- Kothari A, Ramachandran VG, Gupta P, et al., Seroprevalence of cytomegalovirus among voluntary blood donors in Delhi, India, *J Health Popul Nutr*, 2002;20:348–51.
- Kositantont U, Wasi K, Chandanayingyong D, et al., Prevalence of cytomegalovirus antibodies in Thai blood donors, *Asian Pac J Allergy Immunol*, 1985;3:179–82.
- Stroffolini T, Ngatchu T, Chiaramonte M, et al., Prevalence of cytomegalovirus seropositivity in an urban childhood population in Cameroon, *New Microbiol*, 1993;16:83–5.
- Ahmed SA, Al-Joudi FS, Zaidah AW, et al., The prevalence of human cytomegalovirus seropositivity among blood donors at the Unit of Blood Transfusion Medicine, Hospital Universiti Sains Malaysia, *Southeast Asian J Trop Med Public Health*, 2006;37:294–6.
- Daicker B, Cytomegalovirus panuveitis with infection of corneo-trabecular endothelium in AIDS, *Ophthalmologica*, 1988;197:169–75.
- Teoh SB, Thean L, Koay E, Cytomegalovirus in aetiology of Posner-Schlossman syndrome: evidence from quantitative

- polymerase chain reaction, *Eye*, 2005;19:1338–40.
63. Bloch-Michel E, Dussaix E, Cerqueti P, et al., Possible role of cytomegalovirus infection in the etiology of the Posner-Schlossmann syndrome, *Int Ophthalmol*, 1987;11:95–6.
 64. Markomichelakis NN, Canakis C, Zafirakis P, et al., Cytomegalovirus as a cause of anterior uveitis with sectoral iris atrophy, *Ophthalmology*, 2002;109:879–82.
 65. Chee SP, Bascal K, Jap A, et al., Corneal endotheliitis associated with evidence of cytomegalovirus infection, *Ophthalmology*, 2007;114:798–803.
 66. Chee SP, Jap A, Presumed Fuchs heterochromic iridocyclitis and Posner–Schlossman syndrome: comparison of cytomegalovirus-positive and negative eyes, *Am J Ophthalmol*, 2008;146:883–9.
 67. Givens KT, Lee DA, Jones T, et al., Congenital rubella syndrome: ophthalmic manifestations and associated systemic disorders, *Br J Ophthalmol*, 1993;77:358–63.
 68. Biswas J, Narayana KM, Gupta S, et al., Panuveitis due to acquired rubella and isolation of rubella virus from the aqueous humour, *J Pediatr Ophthalmol Strabismus*, 2003;40:240–2.
 69. Birnbaum AD, Tessler HH, Schultz KL, et al., Epidemiologic relationship between fuchs heterochromic iridocyclitis and the United States rubella vaccination program, *Am J Ophthalmol*, 2007;144:424–8.
 70. Kitaichi N, Ariga T, Ohno S, et al., Acute unilateral conjunctivitis after rubella vaccination: the detection of the rubella genome in the inflamed conjunctiva by reverse transcriptase-polymerase chain reaction, *Br J Ophthalmol*, 2006;90:1436–7.
 71. Islam SM, El-Sheikh HF, Tabbara KF, Anterior uveitis following combined vaccination for measles, mumps, and rubella (MMR): a report of two cases, *Acta Ophthalmol Scand*, 2000;78:590–2.
 72. Sever JL, South MA, Shaver KA, Delayed manifestations of congenital rubella, *Rev Infect Dis*, 1985;1:S164–S9.
 73. Boger WP, Late ocular complications in congenital rubella syndrome, *Ophthalmology*, 1980;87:1244–52.
 74. Rothova A, The riddle of Fuchs heterochromic uveitis, *Am J Ophthalmol*, 2007;144:447–8.
 75. Goto H, Mochizuki M, Yamaki K, et al., Epidemiological survey of intraocular inflammation in Japan, *Jpn J Ophthalmol*, 2007;51:41–4.
 76. Tran VT, Auer C, Guex-Crosier Y, et al., Epidemiological characteristics of uveitis in Switzerland, *Int Ophthalmol*, 1994;18:293–8.
 77. Bouchenaki N, Herbot CP, Fluorescein angiographic findings and clinical features in Fuchs' uveitis, *Int Ophthalmol*, 2010;30:511–9.
 78. Mohamed Q, Zamir E, Update on Fuchs' uveitis syndrome, *Curr Opin Ophthalmol*, 2005;16:356–63.
 79. Velilla S, Dios E, Herreras JM, et al., Fuchs' heterochromic iridocyclitis: a review of 26 cases, *Ocul Immunol Inflamm*, 2001;9:169–75.
 80. Bonfioli AA, Curi AL, Orefice F, Fuchs' heterochromic cyclitis, *Semin Ophthalmol*, 2005;20:143–6.
 81. Al-Mansour YS, Al-Rajhi AA, Al-Dhibi H, et al., Clinical features and prognostic factors in Fuchs' uveitis, *Int Ophthalmol*, 2010;30:501–9.
 82. De Groot-Mijnes JD, Rothova A, Van Loon AM, et al., Polymerase chain reaction and Goldmann-Witmer coefficient analysis are complementary for the diagnosis of infectious uveitis, *Am J Ophthalmol*, 2006;141(2):313–8.
 83. Gaynor BD, Margolis TP, Cunningham ET Jr, Advances in diagnosis and management of herpetic uveitis, *Int Ophthalmol Clin*, 2000;40:85–109.
 84. Bodaghi B, LeHoang P, Testing ocular fluids in uveitis, *Ophthalmol Clin North Am*, 2002;15:271–9.
 85. Errera MH, Goldschmidt P, Batellier L, et al., Real-time polymerase chain reaction and intraocular antibody production for the diagnosis of viral versus toxoplasmic infectious posterior uveitis, *Graefes Arch Clin Exp Ophthalmol*, 2011;249(12):1837–46.