

Endoscopic Goniotomy

Marc Töteberg-Harms, MD,^{1,2} Peter P Ciechanowski, MD,² and Jens Funk MD, PhD³

1. Research Fellow, Massachusetts Eye and Ear Infirmary, Harvard Medical School; 2. Resident, Department of Ophthalmology, UniversityHospital Zurich; 3. Professor, Department of Ophthalmology, UniversityHospital Zurich

Abstract

Usually an elevated drainage resistance is responsible for elevated intraocular pressure (IOP) in glaucoma, while aqueous humor production is still normal. Therefore, currently there are great efforts to develop surgical techniques that enhance the conventional outflow through the trabecular meshwork and Schlemm's canal and into the episcleral veins. One of these techniques is excimer laser trabeculotomy (ELT). ELT is easy to perform at the end of cataract surgery. The duration of cataract surgery is only prolonged by 2–3 minutes. IOP can be reduced by up to 34.7 %. It is known that the effect of IOP reduction is constant over time, unlike argon or selective laser trabeculoplasty. The procedure is also very safe. If required later, filtering surgery is not compromised because there is no conjunctival touch during ELT and therefore no scarring of the conjunctiva is induced. For a selected cohort of glaucoma patients, this procedure may avoid the need for trabeculectomy.

Keywords

Glaucoma, glaucoma surgery, trabecular meshwork, phacoemulsification, excimer laser trabeculotomy, excimer laser trabeculectomy, phaco-excimer laser trabeculotomy, trabecular outflow, goniopuncture, goniotomy

Disclosure: The authors have no conflicts of interest to declare.

Received: October 15, 2011 **Accepted:** January 15, 2012 **Citation:** *US Ophthalmic Review*, 2012;5(1):33–6 DOI: 10.17925/USOR.2012.05.01.33

Correspondence: Jens Funk, MD, PhD, Department of Ophthalmology, UniversityHospital Zurich, Frauenklinikstrasse 24, 8091 Zurich, Switzerland. E: jens.funk@usz.ch

Glaucoma is a leading cause of preventable and irreversible blindness.^{1–5} Glaucoma is a chronic and progressive neurodegenerative disorder causing loss of retinal ganglion cells and their axons.⁶ Characteristic 'cupping' of the optic disc is seen with corresponding loss of visual field. Elevated intraocular pressure (IOP) is a causative risk factor for the development and progression of glaucoma, and lowering IOP is the mainstay of treatment. Besides IOP, other risk factors are well-known, e.g. age, family history, and race (e.g. African descent).⁷

The balance of aqueous humor production (inflow) and drainage (outflow) determines the IOP. The pathophysiology of elevated IOP in primary open-angle glaucoma (POAG) is dysfunctional drainage, specifically through the trabecular meshwork (TM).^{8,9} The exact mechanisms that control drainage through the TM are not fully understood, but changes in the extracellular matrix (ECM) are one of the reasons. Furthermore, pathological accumulations of certain ECM structures within the TM have been described as causative in eyes with POAG.

In managing glaucoma patients, lowering the IOP is the only available treatment with a significant body of supporting evidence.^{10–20} Medical reduction of IOP is the first line of therapy in most cases.^{12,21,20} If medical treatment fails, there are several well-established surgical procedures to reduce IOP.

Trabeculectomy (TE) as it is performed today was introduced in 1968 by Cairns²³ and at the same time by Linner.²⁴ It is still the gold standard in

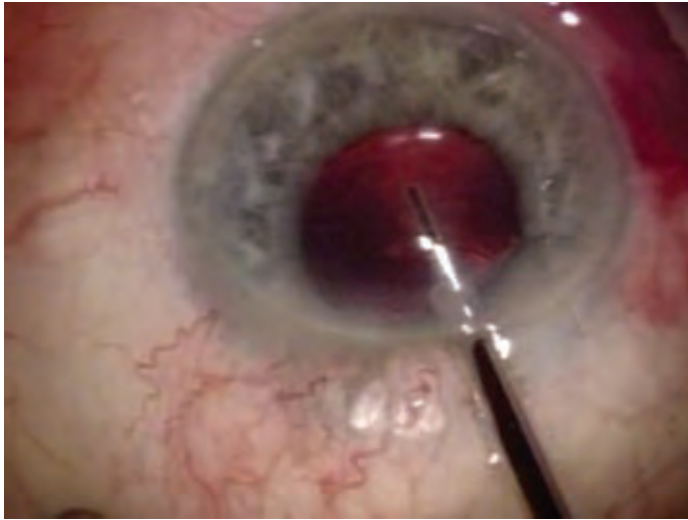
glaucoma surgery. The aqueous flows via a scleral flap from the anterior chamber into the subconjunctival space.²⁵ TE is very effective in long-term IOP reduction.^{26,27} The use of antimetabolites during surgery provides an even better long-term success.^{28–34}

The greatest outflow resistance is at the location of the juxtacanalicular TM (JCT) and inner wall of Schlemm's canal. Schlemm's canal communicates with the episcleral veins. The drainage of aqueous outflow through the TM into Schlemm's canal and later on into the episcleral veins is called the trabecular outflow (83–96 %, 'conventional' pathway), the remaining 5–15 % of the aqueous humor is drained via the uveoscleral pathway ('alternative' pathway).^{35,36} The JCT region, which includes the inner wall of Schlemm's canal and the underlying TM, is thought to be the region where regulation of aqueous humor outflow takes place.^{37–39} The JCT region has the highest resistance to outflow, especially under conditions of elevated IOP.^{39–42}

Although TE remains the mainstay of surgical glaucoma treatment, it remains feasible to enhance aqueous outflow through the conventional pathway. Several surgical approaches have been tried, e.g. *ab interno* TE with the Trabectome™,^{43,44} goniotomy, and goniopuncture, which can be performed with or without endoscopy.

This paper focuses on another technique, excimer laser trabeculotomy (ELT, also known as excimer laser trabeculectomy). First, goniotomy and goniopuncture are discussed briefly.

Figure 1: Surgical Microscope Image of the Laser Fiber and Endoscopic Optics used in Excimer Laser Trabeculotomy



The laser fiber tip overlaps the optics by approximately 3 mm.

Table 1: Technical Data for the AIDA Excimer Laser

Laser type	XeCl excimer laser, laser class 4
Wavelength	308 nm
Cooling	Air
Pulse energy	1.2 mJ at fiber tip
Pulse duration	60 ns
Repetition rate	20 Hz
Laser spot size	200 µm
Cannula diameter	500 µm
Cannula material	Stainless steel
Length of fiber	2,000 mm

Goniotomy

Goniotomy is used to enhance the route for aqueous humor outflow into Schlemm's canal. For this purpose, the tissue of the chamber angle is incised under direct visualization with an operating microscope and a surgical gonioscopy lens or with a fiber optic probe.⁴⁵ Instead of a surgical knife, a photoablative laser device can be used.^{46,47} In 1997, Medow and Sauer reported the first use of endoscopic goniotomy in human subjects.⁴⁸

Goniotomy is known as the gold standard for the treatment of primary congenital (infantile) glaucoma. A successful goniotomy improves the aqueous outflow and IOP control can be maintained for extended periods of time.⁴⁹ For the procedure, an incision just below the Schwalbe line is made to open Schlemm's canal.

Early treatment is important, as the success rate of goniotomy is dependent on the patient's age. From those patients who had glaucomatous anomalies at birth or older than two years and who underwent one or two goniotomies, about 26 % were controlled.^{50,51} However, in patients between one and 24 months of age the success rate is 90–94 %.^{50,51}

Goniotomy

Nowadays goniotomy describes an intervention with laser following deep sclerectomy. The laser is used to create a pore in the trabecular Descemet membrane, which enables an aqueous outflow from the anterior chamber to the intrascleral reservoir. Laser goniotomy can be performed using a neodymium(Nd):yttrium–aluminum–garnet (YAG) laser. Puncturing the trabecular Descemet membrane leads to success rates similar to those of TE.^{52–54}

Previously, Feltgen et al. used an erbium(Er):YAG laser. They reported that goniotomy in combination with cataract surgery produced an IOP reduction comparable to that of combined TE and cataract surgery.^{55,56} In addition, the rate of post-operative complications is low.⁵⁶

Excimer Laser Trabeculotomy

ELT *ab interno* is a minimally invasive surgical technique to reduce IOP in patients with glaucoma or ocular hypertension by creating pores from the anterior chamber into Schlemm's canal.^{57–72} There are almost no thermal side effects or damage to the outer wall of Schlemm's canal.

The punctual ablation of TM by an excimer laser was first described in 1996 by Vogel et al.⁶⁸ They used a prototype laser and the application was monitored using a contact lens. The ELT technique differs from that of other minimally invasive glaucoma laser techniques like argon laser trabeculotomy (ALT) or selected laser trabeculotomy (SLT). The latter ones induce tissue alterations by heat or tissue remodeling, respectively. Therefore, the effects of ALT and SLT reduce over time. After ELT, the edges of the openings are found to be very smooth.^{68,71} This should minimize wound healing, and thus contribute to a long-lasting IOP reduction.

If filtering surgery is required following ELT, the outcome is not compromised by ELT. As there is no conjunctival touch during ELT, no conjunctival scarring that would influence the outcome of TE is expected. It is known that phacoemulsification in isolation results in reduced IOP.^{73–77} The IOP reduction of combined phaco and ELT (phaco-ELT) is greater than that of either cataract surgery or ELT alone.^{65,72} One likely explanation is the deepening of the anterior chamber angle by extraction of the thickened cataractous lens.

ELT could easily be performed at the end of a clear cornea phacoemulsification or as a stand-alone procedure. It can reduce IOP for an extended period of time and is associated with a low rate of complications.^{65,72,78} The duration of cataract surgery is only prolonged by 2–3 minutes for the ELT. The same corneal incision as for phacoemulsification is used.

In our procedure, at the end of the cataract surgery or at the beginning of a stand-alone procedure, a medical miosis is performed with acetylcholine chloride and the anterior chamber deepened with viscoelastics. An endoscopically guided photoablative laser (see *Figure 1*) operating at a wavelength of 308 nm (excimer laser, AIDA, TUI-Laser, Munich, Germany) is used to create ten microperforations into the TM spread over an area of 90°. Each microperforation is about 0.5 mm in diameter (diameter of the laser fiber). Further details of the device are given in *Table 1*. To transmit the complete energy of the laser to the TM,

Table 2: Change of Pre- to Post-operative values of Intraocular Pressure and Antiglaucoma Medication

	Δ IOP (mmHg)	Percentage	p Value	Δ AGM	Percentage	p Value
All	-4.41 ± 6.18	-21.99 %	$p < 0.05$	-1.02 ± 1.47	-73.91 %	$p < 0.05$
SG 1	-1.40 ± 4.58	-8.75 %	$p < 0.05$	-1.20 ± 1.47	-48.58 %	$p < 0.05$
SG 2	-8.79 ± 5.27	-34.70 %	$p < 0.05$	-0.79 ± 1.50	-54.11 %	$p < 0.05$

For all study eyes and subgroup (SG) 1 with a pre-operative intraocular pressure (IOP) < 22 mmHg and SG 2 with a pre-operative IOP > 21 mmHg. AGM = antiglaucoma medication.

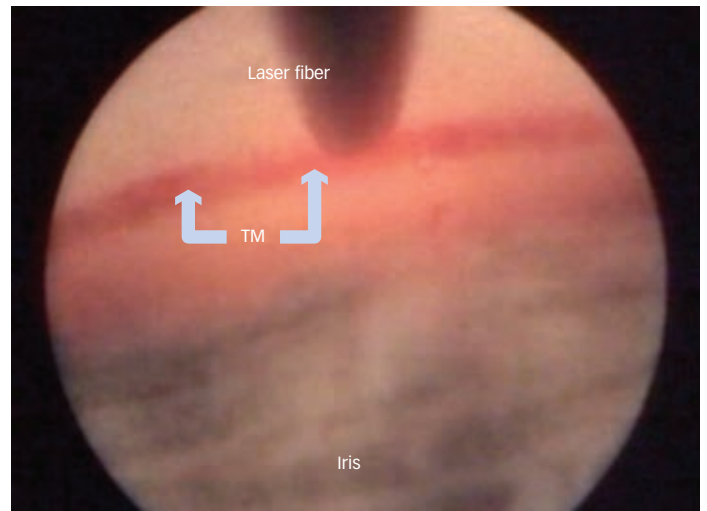
the laser tip must make contact with the tissue (see Figure 2). After laser application, a formation of bubbles can be seen together with a small retrograde bleeding. This indicates the perforation of the TM and the inner wall of Schlemm's canal (see Figure 3). Bleeding stops spontaneously almost immediately. At the end of the surgical procedure, the viscoelastics are removed with aspiration and irrigation and the globe is pressurized to approximately 15 mmHg.

We conducted a preliminary study that included 28 eyes of 28 patients with a pre-operative IOP of over 21 mmHg (mean 25.33 ± 2.85 mmHg). One year after combined phaco-ELT we found a mean IOP reduction of 8.79 ± 5.28 mmHg (-37.70 %, $p < 0.001$). During the same period, the number of antiglaucoma medications could be reduced by an average of 0.79 ± 1.50 per patient (-62.70 %, $p = 0.017$). The complication rate was similar to that of normal cataract surgery and no serious complications occurred. The success rate was 64.3 % (as defined by post-operative IOP < 21 mmHg in addition to IOP reduction of ≥ 20 % with or without medical therapy and no further glaucoma surgery within the follow-up period).⁷⁸

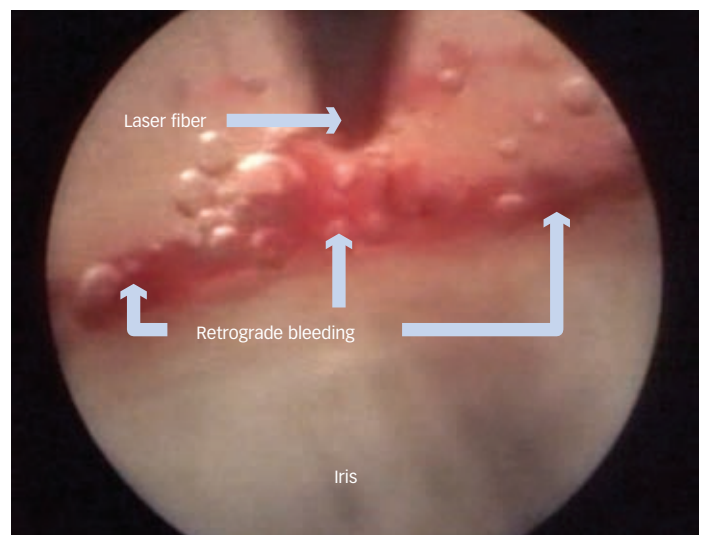
A larger study is ongoing. In this study, eyes with IOP less than 22 mmHg are also included. The preliminary results of 73 eyes of 64 patients with a mean age of 76.51 ± 9.36 years after a follow-up period of 12 months post-surgery are shown in Table 2.

Conclusion

A range of surgical options to lower IOP is available. TE with antimetabolites is still the gold standard. The goal of minimizing post-operative complications demands minimally invasive procedures. In the event of a very low target IOP, TE is the treatment of choice. However, it may also be possible to achieve a sufficient reduction in IOP with endoscopic surgical methods. Goniotomy is mostly used in infantile glaucoma, and goniopuncture is an option following deep sclerectomy. Excimer laser trabeculotomy could become more popular in combination with a phacoemulsification in minimally invasive endoscopic surgery, as it causes fewer complications compared to TE. For a selected cohort of glaucoma patients, in particular those with an IOP over 21 mmHg and at least moderate cataract, the combined procedure of ELT and

Figure 2: Image of the Anterior Chamber Angle before Laser Treatment, as seen through the Endoscopic Optics

The laser fiber is in direct contact with the trabecular meshwork (TM).

Figure 3: Image of the Anterior Chamber Angle immediately after Excimer Laser Trabeculotomy, as seen through the Endoscopic Optics

The formation of some bubbles is visible, as is a small retrograde bleed, indicating the perforation of the anterior wall of Schlemm's canal.

phacoemulsification appears to be a promising approach to avoid (or at least to delay for some years) the onset of TE. ■

- Quigley HA, Number of people with glaucoma worldwide, *Br J Ophthalmol*, 1996;80:389-93.
- Quigley HA, Broman AT, The number of people with glaucoma worldwide in 2010 and 2020, *Br J Ophthalmol*, 2006;90:262-7.
- Thylefors B, Negrel AD, The global impact of glaucoma, *Bull World Health Organ*, 1994;72:323-6.
- Resnikoff S, Donatella P, Etya'ale D, et al., Global data on visual impairment in the year 2002, *Bull World Health Organ*, 2004;82:844-51.
- Thylefors B, Negrel AD, Pararajasegaram R, Dadzie KY, Global data on blindness, *Bull World Health Organ*, 1995;73:115-21.
- Quigley HA, Addicks EM, Green WR, Maumenee AE, Optic nerve damage in human glaucoma. II. The site of injury and susceptibility to damage, *Arch Ophthalmol*, 1981;99:635-49.
- Boland MV, Quigley HA, Risk factors and open-angle glaucoma: classification and application, *J Glaucoma*, 2007;16:406-18.
- Brubaker RF, Clinical measurements of aqueous dynamics: implications for addressing glaucoma. In: Civan MM, *The Eye's Aqueous Humor From Secretion to Glaucoma*, San Diego: Academic Press, 1997:233-84.
- Larsson LI, Rettig ES, Brubaker RF, Aqueous flow in open-angle glaucoma, *Arch Ophthalmol*, 1995;113:283-6.
- Collaborative Normal-Tension Glaucoma Study Group, The effectiveness of intraocular pressure reduction in the treatment of normal-tension glaucoma, *Am J Ophthalmol*, 1998;126:498-505.
- Grant WM, Burke JF Jr, Why do some people go blind from glaucoma?, *Ophthalmology*, 1982;89:991-8.
- Heijl A, Leske MC, Bengtsson B, et al., Reduction of intraocular pressure and glaucoma progression: results from the Early Manifest Glaucoma Trial, *Arch Ophthalmol*, 2002;120:1268-79.
- Collaborative Normal-Tension Glaucoma Study Group, Comparison of glaucomatous progression between untreated patients with normal-tension glaucoma and patients with therapeutically reduced intraocular pressures, *Am J Ophthalmol*, 1998;126:487-97.
- The AGIS Investigators, The Advanced Glaucoma Intervention Study (AGIS): 7. The relationship between control of intraocular pressure and visual field deterioration, *Am J Ophthalmol*, 2000;130:429-40.

15. Palmberg P, Risk factors for glaucoma progression: where does intraocular pressure fit in?, *Arch Ophthalmol*, 2001;119:897–8.
16. Bergea B, Bodin L, Svedbergh B, Impact of intraocular pressure regulation on visual fields in open-angle glaucoma, *Ophthalmology*, 1999;106:997–1004.
17. Group CN-TGS, Comparison of glaucomatous progression between untreated patients with normal-tension glaucoma and patients with therapeutically reduced intraocular pressures, *Am J Ophthalmol*, 1998;126:487–97.
18. Investigators TAGIS, The Advanced Glaucoma Intervention Study (AGIS): 7. The relationship between control of intraocular pressure and visual field deterioration, *Am J Ophthalmol*, 2000;130:429–40.
19. Kass MA, Gordon MO, Hoff MR, et al., Topical timolol administration reduces the incidence of glaucomatous damage in ocular hypertensive individuals. A randomized, double-masked, long-term clinical trial, *Arch Ophthalmol*, 1989;107:1590–8.
20. Mao LK, Stewart WC, Shields MB, Correlation between intraocular pressure control and progressive glaucomatous damage in primary open-angle glaucoma, *Am J Ophthalmol*, 1991;111:51–5.
21. Feiner L, Piltz-Seymour JR, Collaborative Initial Glaucoma Treatment Study: a summary of results to date, *Curr Opin Ophthalmol*, 2003;14:106–11.
22. Wilensky JT, The role of medical therapy in the rank order of glaucoma treatment, *Curr Opin Ophthalmol*, 1999;10:109–11.
23. Cairns JE, Trabeculectomy. Preliminary report of a new method, *Am J Ophthalmol*, 1968;66:673–9.
24. Linner E, Microsurgical trabeculectomy 'ab externo' in glaucoma, *Trans Ophthalmol Soc UK*, 1970;89:475–9.
25. Spencer WH, Symposium: microsurgery of the outflow channels. Histologic evaluation of microsurgical glaucoma techniques, *Trans Am Acad Ophthalmol Otolaryngol*, 1972;76:389–97.
26. Jay JL, Allan D, The benefit of early trabeculectomy versus conventional management in primary open angle glaucoma relative to severity of disease, *Eye (Lond)*, 1989;3(5):528–35.
27. Migdal C, Gregory W, Hitchings R, Long-term functional outcome after early surgery compared with laser and medicine in open-angle glaucoma, *Ophthalmology*, 1994;101:1651–6.
28. Katz GJ, Higginbotham EJ, Lichter PR, et al., Mitomycin C versus 5-fluorouracil in high-risk glaucoma filtering surgery. Extended follow-up, *Ophthalmology*, 1995;102:1263–9.
29. Khaw PT, Chang L, Wong TT, et al., Modulation of wound healing after glaucoma surgery, *Curr Opin Ophthalmol*, 2001;12:143–8.
30. Lama PJ, Fechtner RD, Antifibrotics and wound healing in glaucoma surgery, *Surv Ophthalmol*, 2003;48:314–46.
31. Suzuki R, Dickens CJ, Iwach AG, et al., Long-term follow-up of initially successful trabeculectomy with 5-fluorouracil injections, *Ophthalmology*, 2002;109:1921–4.
32. Towler HM, McCluskey P, Shaer B, Lightman S, Long-term follow-up of trabeculectomy with intraoperative 5-fluorouracil for uveitis-related glaucoma, *Ophthalmology*, 2000;107:1822–8.
33. WuDunn D, Cantor LB, Palanca-Capistrano AM, et al., A prospective randomized trial comparing intraoperative 5-fluorouracil vs mitomycin C in primary trabeculectomy, *Am J Ophthalmol*, 2002;134:521–8.
34. Yoon PS, Singh K, Update on antifibrotic use in glaucoma surgery, including use in trabeculectomy and glaucoma drainage implants and combined cataract and glaucoma surgery, *Curr Opin Ophthalmol*, 2004;15:141–6.
35. Bill A, Phillips CI, Uveoscleral drainage of aqueous humor in human eyes, *Exp Eye Res*, 1971;12:275–81.
36. Pederson JE, Gaasterland DE, MacLellan HM, Uveoscleral aqueous outflow in the rhesus monkey: importance of uveal reabsorption, *Invest Ophthalmol Vis Sci*, 1977;16:1008–7.
37. Bill A, Editorial: The drainage of aqueous humor, *Invest Ophthalmol*, 1975;14:1–3.
38. Grant WM, Further studies on facility of flow through the trabecular meshwork, *AMA Arch Ophthalmol*, 1958;60:523–33.
39. Moses RA, Grodzki WJ Jr, Etheridge EL, Wilson CD, Schlemm's canal: the effect of intraocular pressure, *Invest Ophthalmol Vis Sci*, 1981;20:61–8.
40. Maepa O, Bill A, The pressures in the episcleral veins, Schlemm's canal and the trabecular meshwork in monkeys: effects of changes in intraocular pressure, *Exp Eye Res*, 1989;49:645–63.
41. Maepa O, Bill A, Pressures in the juxtacanalicular tissue and Schlemm's canal in monkeys, *Exp Eye Res*, 1992;54:879–83.
42. Seiler T, Wollensak J, The resistance of the trabecular meshwork to aqueous humor outflow, *Graefes Arch Clin Exp Ophthalmol*, 1985;223:88–91.
43. Filippopoulos T, Rhee DJ, Novel surgical procedures in glaucoma: advances in penetrating glaucoma surgery, *Curr Opin Ophthalmol*, 2008;19:149–54.
44. Jea SY, Mosaed S, Vold SD, Rhee DJ, Effect of a failed trabectome on subsequent trabeculectomy, *J Glaucoma*, 2012;21(2):71–5.
45. Kuikarni SV, Damji KF, Fournier AV, et al., Endoscopic goniotomy: early clinical experience in congenital glaucoma, *J Glaucoma*, 2010;19:264–9.
46. Holz HA, Lim MC, Glaucoma lasers: a review of the newer techniques, *Curr Opin Ophthalmol*, 2005;16:89–93.
47. Jacobi PC, Dietlein TS, Krieglstein GK, Experimental microendoscopic photoablative laser goniotomy as a surgical model for the treatment of dysgenetic glaucoma, *Graefes Arch Clin Exp Ophthalmol*, 1996;234:670–6.
48. Medow NB, Sauer HL, Endoscopic goniotomy for congenital glaucoma, *J Pediatr Ophthalmol Strabismus*, 1997;34:258–9.
49. Russell-Eggitt IM, Rice NS, Jay B, Wyse RK, Relapse following goniotomy for congenital glaucoma due to trabecular dysgenesis, *Eye (Lond)*, 1992;6(2):197–200.
50. Shaffer RN, Prognosis of goniotomy in primary infantile glaucoma (trabeculodysgenesis), *Trans Am Ophthalmol Soc*, 1982;80:321–5.
51. Shaffer RN, Hoskins HD, Montgomery lecture. Goniotomy in the treatment of isolated trabeculodysgenesis (primary congenital [infantile] developmental glaucoma), *Trans Ophthalmol Soc UK*, 1983;103(6):581–5.
52. Ambresin A, Shaarawy T, Mermoud A, Deep sclerectomy with collagen implant in one eye compared with trabeculectomy in the other eye of the same patient, *J Glaucoma*, 2002;11:214–20.
53. Anand N, Pilling R, Nd:YAG laser goniotomy after deep sclerectomy: outcomes, *Acta Ophthalmol*, 2010;88:110–5.
54. Mermoud A, Karlen ME, Schnyder CC, et al., Nd:Yag goniotomy after deep sclerectomy with collagen implant, *Ophthalmic Surg Lasers*, 1999;30:120–5.
55. Feltgen N, Mueller H, Ott B, et al., Endoscopically controlled erbium:YAG goniotomy versus trabeculectomy: effect on intraocular pressure in combination with cataract surgery, *Graefes Arch Clin Exp Ophthalmol*, 2003;241:94–100.
56. Funk J, Schlunck G, [Endoscopically controlled erbium YAG laser goniotomy. Initial preclinical trials], *Ophthalmologie*, 1998;95:33–6.
57. Babighian S, Caretti L, Tavalato M, et al., Excimer laser trabeculectomy vs 180 degrees selective laser trabeculoplasty in primary open-angle glaucoma. A 2-year randomized, controlled trial, *Eye (Lond)*, 2010;24:632–8.
58. Babighian S, Rapizzi E, Galan A, Efficacy and safety of ab interno excimer laser trabeculectomy in primary open-angle glaucoma: two years of follow-up, *Ophthalmologica*, 2006;220:285–290.
59. Herdener S, Pache M, [Excimer laser trabeculectomy: minimally invasive glaucoma surgery], *Ophthalmologie*, 2007;104:730–2.
60. Huang S, Yu M, Feng G, et al., Histopathological study of trabeculectomy after excimer laser trabeculectomy ab interno, *Yan Ke Xue Bao*, 2001;17:11–5.
61. Jahn R, Lierse W, Neu W, Jungbluth KH, Macroscopic and microscopic findings after excimer laser treatment of different tissue, *J Clin Laser Med Surg*, 1992;10:413–8.
62. Kaufmann R, Hibst R, Pulsed Er:YAG- and 308 nm UV-excimer laser: an in vitro and in vivo study of skin-ablative effects, *Lasers Surg Med*, 1989;9:132–40.
63. Muller-Stolzberg N, Muller GJ, Transmission of 308 nm excimer laser radiation for ophthalmic microsurgery – medical, technical and safety aspects, *Biomed Tech (Berl)*, 1989;34:131–8.
64. Neuhann T, Scharrer A, Haefliger E, Excimer laser trabecular ablation ab interno (ELT) in the treatment of chronic open-angle glaucoma. A pilot study, *Ophthalmol-Chirurgie*, 2001;13:3–7.
65. Pache M, Wilmsmeyer S, Funk J, [Laser surgery for glaucoma: excimer-laser trabeculectomy], *Klin Monbl Augenheilkd*, 2006;223:303–7.
66. Taliaferro K, Excimer laser trabeculectomy, *Ophthalmologica*, 2008;222:424.
67. Vogel M, Lauritzen K, [Selective excimer laser ablation of the trabecular meshwork. Clinical results], *Ophthalmologie*, 1997;94:665–7.
68. Vogel M, Lauritzen K, Quentin CD, [Targetted ablation of the trabecular meshwork with excimer laser in primary open-angle glaucoma], *Ophthalmologie*, 1996;93:565–8.
69. Vogel M, Scheurer G, Neu W, et al., [Ablation of the trabecular meshwork], *Klin Monbl Augenheilkd*, 1990;197:250–3.
70. Vogel MH, Schildberg P, [Histological findings after experimental laser-trabeculo-puncture (author's transl)], *Klin Monbl Augenheilkd*, 1973;163:353–8.
71. Walker R, Specht H, [Theoretical and physical aspects of excimer laser trabeculectomy (ELT) ab interno with the AIDA laser with a wave length of 308 nm], *Biomed Tech (Berl)*, 2002;47:106–10.
72. Wilmsmeyer S, Philippin H, Funk J, Excimer laser trabeculectomy: a new, minimally invasive procedure for patients with glaucoma, *Graefes Arch Clin Exp Ophthalmol*, 2006;244:670–6.
73. Dooley I, Charalampidou S, Malik A, et al., Changes in intraocular pressure and anterior segment morphometry after uneventful phacoemulsification cataract surgery, *Eye (Lond)*, 2010;24:519–26.
74. Hudovernik M, Pahor D, Intraocular pressure after phacoemulsification with posterior chamber lens implantation in open-angle glaucoma, *Klin Monbl Augenheilkd*, 2003;220:835–9.
75. Kim DD, Doyle JW, Smith MF, Intraocular pressure reduction following phacoemulsification cataract extraction with posterior chamber lens implantation in glaucoma patients, *Ophthalmic Surg Lasers*, 1999;30:37–40.
76. Shingleton BJ, Gamell LS, O'Donoghue MW, et al., Long-term changes in intraocular pressure after clear corneal phacoemulsification: normal patients versus glaucoma suspect and glaucoma patients, *J Cataract Refract Surg*, 1999;25:885–90.
77. Shrivastava A, Singh K, The effect of cataract extraction on intraocular pressure, *Curr Opin Ophthalmol*, 2010;21:118–22.
78. Toteberg-Harms M, Ciechanowski PP, Hirn C, Funk J, [One-year results after combined cataract surgery and excimer laser trabeculectomy for elevated intraocular pressure], *Ophthalmologie*, 2011;108:733–8.