

The Role of Glaucoma Drainage Devices in Paediatric Glaucoma

Esperanza Gutiérrez-Díaz,¹ Enrique Mencía-Gutiérrez² and Pilar Tejada-Palacios³

1. Head, Glaucoma Unit; 2. Staff Physician; 3. Associate Professor and Head of Paediatric Unit, Ophthalmology Department, 12 de Octubre Hospital, Complutense University, Madrid, Spain

Abstract

Glaucoma drainage devices may be indicated in glaucoma associated to complex congenital anomalies or dysgenesis of the anterior segment, secondary glaucomas such as those developed after congenital cataract surgery, severe primary congenital glaucoma after failed angle surgery and in eyes with severe conjunctival scarring. They can be combined with several other procedures, such as cataract extraction, intraocular lens implantation, keratoplasty or pars plana vitrectomy. This procedure may achieve a sustained and prolonged intraocular pressure reduction in children, with early post-operative success as high as 90 %, although it decreases over time, to 40–60 % survival at 4–6 years using the Kaplan-Meier analysis and most children need to reinstate glaucoma treatment postoperatively. We must bear in mind that complications may occur, especially tube malposition and exposure, and multiple repeated surgeries may be necessary. The advantages and complications should be weighed in each individual case.

Keywords

Ahmed valve, complications, glaucoma drainage device (GDD), glaucoma, paediatric, surgery

Disclosure: The authors have no conflicts of interest to declare.

Received: 15 August 2012 **Accepted:** 22 October 2012 **Citation:** *European Ophthalmic Review*, 2012;6(4):208–13 DOI: 10.17925/EOR.2012.06.04.208

Correspondence: Enrique Mencía-Gutiérrez, Ophthalmology Department, 12 de Octubre Hospital, E28041 Madrid, Spain. E: emencia.hdoc@salud.madrid.org

The treatment of glaucoma in childhood is primarily surgical. The goniotomy is considered the procedure of choice in primary congenital glaucoma,¹ but in secondary glaucoma and after failed angle surgery, other procedures should be considered. Among these the glaucoma drainage devices (GDD). The Molteno single-plate was the GDD used in children for the first time in 1973 by Molteno.² Since then, numerous papers dealing with the results and complications of this procedure in children have been published,^{3–27} and nowadays, the effectiveness of GDD has been well-established. However, we must bear in mind the extremely long life expectancy of a paediatric patient, which will probably require the care of two or more generations of ophthalmologists throughout his life. For this reason, all the possible surgical options should be considered and caution should be taken when selecting the most adequate one, which may be a GDD or some other procedure.

Indications

GDD may be indicated in glaucoma associated to complex congenital anomalies or dysgenesis of the anterior segment, such as Peter's syndrome or aniridia and secondary glaucomas such as those developed after congenital cataract surgery or in Sturge-Weber syndrome.³

Regarding primary congenital glaucoma, although goniotomy and trabeculotomy are undoubtedly the treatments of choice, in severe cases GDD may also be considered, as the prognosis following surgery is closely related to the severity of the glaucoma. Al-Hazmi et al.²⁸ have shown how severe primary congenital glaucoma had worse results than moderate or mild cases, regardless of the surgical procedure performed, with trabeculotomy achieving a success rate of only 10 % after one year in severe cases, versus 40 and 90 % in moderate and mild cases, respectively. Severe conjunctival scarring is a clear indication for GDD surgery.³

Device Selection

In the majority of series regarding paediatric glaucoma, the device employed has been the Ahmed glaucoma valve (New World Medical, Inc, Rancho Cucamonga, CA, US). This implant features flow restriction by means of a unidirectional valve that is designed to open at a pressure of 8 mmHg,²⁹ therefore potentially decreasing the risk of post-operative hypotony. Moreover, its post-operative management is easy, which is very important in children. Reports dealing with other devices, such as the Baerveldt (BGI; Advanced Medical Optics, Santa Ana, CA, US) or the Molteno implants (IOP Inc, Costa Mesa, CA, US), have been published^{4–8} but no randomised study comparing these devices in children has been performed to date. In adults, free-flow implants have shown better results, with lower intraocular pressure (IOP) and less need of post-operative glaucoma medications, but with a higher rate of complications and subsequent interventions.^{5,30,31}

The models usually employed are standard for adults. Although there are paediatric models of both Molteno and Ahmed implants, they are seldom used; only in very small eyes, as in children younger than six months of age, or in cases of microphthalmus. Pre-operative ultrasonography may help to determine the size of the globe. Also, in certain types of glaucoma, such as the one secondary to uveitis and in patients who have undergone cyclodestructive therapy, aqueous production may be reduced and small plates may be preferable. These paediatric models have a small size plate, of 96 mm² in the Ahmed valve and 133 mm² (8 mm of diameter) in the Molteno implant, which may result in insufficient aqueous outflow as the child grows up, sometimes requiring substitution with an adult model.

With regard to the material used, silicone implants have achieved better results in children. In the study by Kahn et al.,⁹ the silicone Ahmed valve

showed a mean survival time significantly longer (23 months) than the polypropylene valve (19.1 months). Also, the cumulative probabilities of survival at two years based on Kaplan–Meier analysis were higher for the silicone valve than for the polypropylene one, 90.9 versus 54.8 % respectively.

Surgical Technique

The details of the surgical procedure are basically the same as in adults, but some considerations must be made because of the special anatomical characteristics of the eye in children and to avoid hypotony and the most frequent complications in children.

As in adults, a fornix based flap is recommended to open the conjunctiva in the selected quadrant, with blunt dissection to expose the bare sclera.

The plate should be placed in the superior quadrants, avoiding the inferior nasal quadrant which poses a greater risk of motility disturbances. Thin non-absorbable sutures, such as 7/0 or 9/0 nylon or silk, should be used to secure the plate to the sclera. It can be positioned slightly closer to the limbus than in adults, with its anterior edge 6 to 10 mm posterior to the limbus. When placing an Ahmed valve in the superonasal quadrant in very small eyes, the distance to the limbus should not exceed 6-8 mm, because the posterior edge of the valve may reach the optic nerve and damage it by direct pressure from the plate or inclusion in the capsule. In very small orbits, in which there may not be enough space to insert the implant, a cantholysis can facilitate the insertion of the plate in the adequate position.

In buphthalmic eyes the sclera is very thin, so special care should be taken to avoid scleral perforation.³ In these cases, it has also been suggested that the sutures of the plate be placed in the muscular tendons, although this may also entail risk of muscle imbalance.¹⁰

The sclerostomy for the tube should be performed by means of a tunnel with a 23-gauge needle. In buphthalmic eyes with a very thin sclera, a 25-gauge needle is preferable, since the scleral compliance is highly increased and therefore an excessive outflow of aqueous directly through the tunnel around the tube is more likely.¹¹ Sudden changes in the trajectory of the needle should also be avoided, so that the tube can be easily inserted without excessive manipulation, which could cause tunnel dilation and allow peritubular flow.

It is convenient to flush the tube with a balanced salt solution through a 30-gauge cannula to ensure its patency before insertion; this manoeuvre is absolutely indispensable when using an Ahmed implant to open the valve.

In pseudophakic eyes, the best position for the tube is in the posterior chamber, or even the vitreous, but in phakic eyes, it must be placed in the anterior chamber. In this case, the tube should be placed as posteriorly as possible to prevent corneal touch.¹²⁻¹⁴

The end of the tube has to be trimmed, and we recommend that the bevel be laterally oriented, so the opening of the tube does not face the iris or the cornea (see *Figures 1 and 2*). In this manner, we can try to prevent possible occlusion from the iris and the potential retrograde flow towards the cornea. Furthermore, if a tube placed in the anterior chamber is moved to the posterior chamber, the lateral bevel continues to prevent occlusion from the iris, while when a tube

Figure 1: The End of the Tube is Trimmed and the Bevel is Laterally Oriented

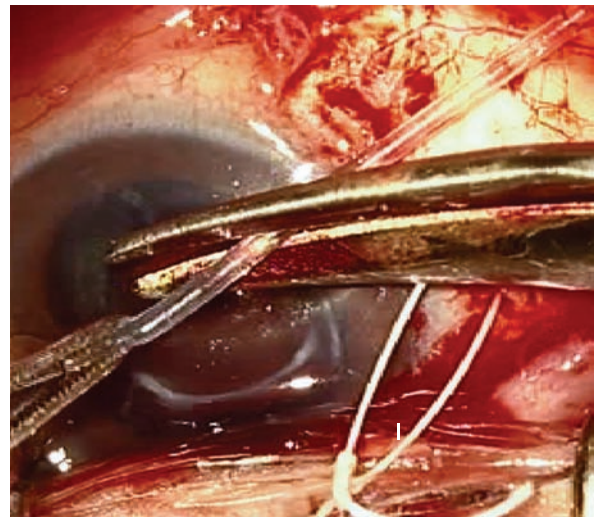
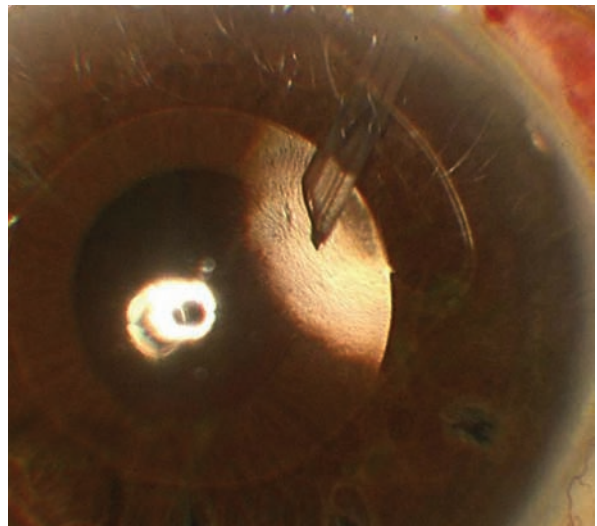
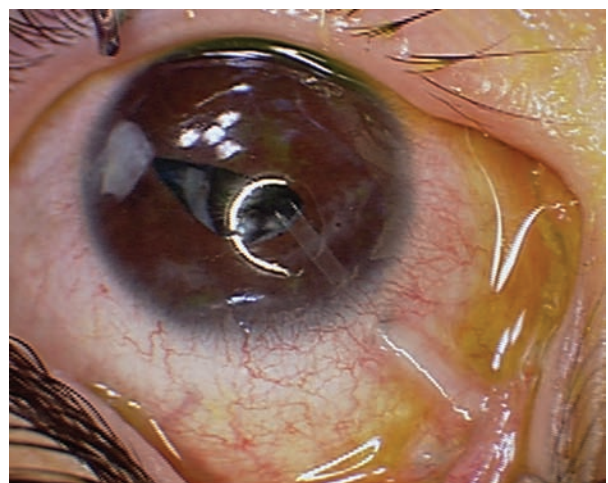


Figure 2: A Tube Located in the Anterior Chamber



The lateral bevel prevent possible occlusion from the iris and the potential retrograde flow towards the cornea.

Figure 3: Tube is Clearly Visible Under the Conjunctiva



Regular follow-ups specifically assessing the potential exposure is needed in cases like this.

beveled up towards the cornea is moved, the bevel will end up facing towards the iris and it will be more likely to become occluded if the bevel is not modified, unless it is long enough so that the end is within the pupil;³² to change the bevel, the tube must be trimmed again, and this may lead to excessively reducing the length of the tube.

Positioning the tube in the vitreous implies that an extensive vitrectomy must be done, since any remnants of the vitreous will be attracted to the opening of the tube and may block it.

Once inserted into the globe, the tube should be fastened to the sclera with a nylon 10/0 suture. It is useful to not fully introduce the complete length of the tube, but to leave a part of it outside the globe with a trajectory shaped in italic S and to fix the extra length in this position with nylon sutures. Later on, if the globe enlarges and the tube becomes too short inside the eye, these sutures can be released and the tube extended and pushed further again into the globe.³³

It is highly recommended that the extraocular portion of the tube be covered with a patch, which may be of conserved sclera, cornea, pericardium or fascia lata, as tube exposure is one of the most frequent complications in children and a potentially serious one, leading to endophthalmitis or tube extrusion. However, when inserting the tube through a very long tunnel, as recommend by Albis et al.,¹¹ neither patch grafts nor scleral fixation of the tube may be necessary. They considered the long tunnel to be preferable, since a normal angle between the conjunctiva and the cornea is maintained, reducing the risk of dellen, pain and foreign body sensation. In addition, it is secure, as no case of tube exposure has occurred in their series.

The conjunctiva can be sutured with re-absorbable sutures, such as polyglactin, which do not need to be removed postoperatively. Another alternative is to fix the conjunctiva with fibrin glue, which may also be used to secure the tube to the sclera and the patch over it, as has been describe by Freeman et al.¹⁵ They report no cases of conjunctival dehiscence or patch graft migration. The main advantage of this option is that the lack of suture exposure may reduce post-operative irritation and inflammation, an important consideration when treating the paediatric population. Decreased discomfort may help prevent eye-rubbing, with subsequent lower risk of self-inflicted displacement of the tube or implant. Another advantage would be reduced manual manipulation, which may decrease the total operating room time.

The last point to make with regards to surgical technique is the prevention of post-operative hypotony, which is very important in children, as the management of a flat or shallow anterior chamber often requires repeated general anaesthesia. This is one of the reasons the Ahmed glaucoma valve is preferred in children. Indeed, several authors have recommend using restrictive measures such as tube ligation even when inserting an Ahmed valve, with total^{6,14,16} or partial¹⁷ occlusion of the tube lumen using a re-absorbable ligation, or implanting the device in two phases, inserting the tube into the eye four to six weeks after the plate has been implanted.^{5,6,18} In this way, aqueous outflow is prevented in the early post-operative period and delayed until an adequate fibrous capsule has formed around the plate. Another useful option is to use a gas bubble, as has been described by Kirwan et al.,¹⁹ who advocate injecting an SF₆ bubble in the anterior chamber at the end of surgery. This bubble remains in the eye for 72 hours, giving enough time for aqueous production restoration.

Use of Antimetabolites

Few series have dealt with the use of mitomycin C (MMC) in children undergoing GDD procedures, but, as in adults,^{34,35} no improvement in the results has been observed with its use; in the series published by Kirwan et al.,¹⁹ no differences in IOP control or complications were found whether or not MMC was used. Indeed, Al Mobarak et al.²⁰ have demonstrated worse results when MMC was used, with a mean survival time significantly longer for the eyes not treated with MMC (22.15 months) than for those treated with MMC (16.25 months). Likewise, cumulative probabilities of success at two years were lower in MMC-treated eyes, with a 31.3 % success rate, versus an 80.0 % rate in non-MMC eyes. Finally, average survival times without medications were longer in the non-MMC eyes than in the treated eyes, 11.28 months versus 4.6 months, respectively. Furthermore, the need for post-operative glaucoma medications was lower in the non-MMC treated eyes. These authors hypothesise that the MMC-induced tissue death may stimulate a stronger reactive fibrosis adjacent to the area of application and around the plate, leading to excessive fibrosis and decreased filtration of the capsule.

Combined Procedures

GDD surgery can be combined with several other procedures, such as cataract extraction, intraocular lens implantation, keratoplasty, or par plana vitrectomy. Tesser et al.⁷ have presented a series of nine eyes with simultaneous implantation of an intraocular lens and a DDG, either a Baerveldt device or an Ahmed valve. Seven were aphakic and in the other two, cataract extraction was also performed. IOP control was achieved in eight eyes and the visual results were also good, without worsening in any eye and improvement in five eyes, three of them acquiring a visual acuity of 20/20. One advantage of implanting an intraocular lens in an aphakic eye is that it reduces the risk of vitreous entering into the tube.⁷ Banitt et al.²⁴ have described their results with the Baerveldt implant inserted through pars plana in a series. Kaplan-Meier analysis demonstrated an 85 % survival rate at 12 months, 81 % at 24 months, and 72 % at 36 months and an 83.3 % rate at the final follow-up. Among the complications there were 4 cases (13.3 %) of retinal detachment.

Complications

The global rate of complications reached as high as 84.6 % in the series by Chen et al.¹² (44/52 eyes) and they do occur with any type of GDD, such as the Ahmed valve, with complications arising in 28.9 % of the cases in the series by Albis et al.,¹¹ and in 17.6 % in the series by Yang et al.,¹⁷ or with the Baerveldt implant, with complications in 18.7 % of the cases in the series by Rolim de Moura et al.⁶

Besides their frequency, complications in children are even more important because many of them, at this age, must be resolved under general anaesthesia, leading to a high reported rate of additional interventions, 48.1 % in the series by Chen et al.¹² and 30.9 % in that by Overdam et al.²¹

Post-operative tube migration (typically anteriorly) is the most common complication in the vast majority of series, with figures as high as 34.8 % in the series by Beck et al.⁴ and 26.2 % in the series by Al Mobarak et al.¹³ Tube migration can occur more frequently in younger patients and buphthalmic eyes.³

Anterior displacement of the tube may be related to the higher relative rigidity of the tube compared to the elasticity of the sclera in children, which may result in a tendency of the tube to slowly straighten and rotate anteriorly towards the cornea, particularly if the tube has been forced

to bend at the limbus.²² This situation poses a high risk of tube-corneal touch and corneal decompensation. Chen et al.¹² have also suggested that it may be due to the contraction of the perivalvular fibrous tissue, and recommend placing the tube more posteriorly and closer to the iris. In most series, the incidence of tube-corneal touch ranged from 7 to 18.5 %, ^{12,14,18,21} but rose to 34.8 % in the series by Beck et al.,⁴ decreasing to lower than 2 % in the series by Morad et al.¹⁶ and Budenz et al.⁵

Another possibility of tube malposition is retraction, which occurred in 3.9 % of the cases in the series by Atratta et al.⁸ and 8.3 % in the Rolim de Moura et al.⁶ series. It may be caused by an enlargement of the globe increasing the distance between the plate and the limbus, which may be due to the normal development of the child, but can also occur if the IOP is not well-controlled. Another factor is the relative shrinking of the eye once the IOP is reduced.¹⁴ Finally, it may be due to a real retraction of the tube, related to a posterior displacement of a plate that is poorly attached to the sclera.

Conjunctival erosion with tube exposition is a particularly dangerous complication, since it may result in tube extrusion and endophthalmitis. This has also been frequently reported in the published series, with an incidence of 1.6 to 7 %, ^{5,6,8,12,14,17,21} Apart from the well-known factors involved in its development in adults, such as poor lubrication of the ocular surface, micro-movements of the tube, rubbing against the tarsal plate and previous use of MMC, in children its occurrence is even more likely to be produced by eye rubbing, which is hardly avoidable (see *Figure 3*). Children younger than two at the time of surgery appear to be at higher risk for this complication.⁴

As in adults, tube obstruction by blood, fibrin, iris, lens capsule, or vitreous can occur in children, but surgical repair is often required in these patients. This complication ranges from 13.5 % in the series by Chen et al.,¹² to less than 4 % in other series.^{5,8,17}

Iris retraction or entrapment in the tube track, leading to dyscoria, is also a tube related complication, very frequent in the series by Overdam et al.,²¹ in which it appeared in 21.8 % of the cases, all of them buphthalmic eyes.

Encapsulated bleb is another complication with difficult management in children. Kirwan et al.¹⁹ have described repeated needling of the valve. The procedure consists in injecting Healon GV® (Abbott Medical Optics Inc) under the conjunctival bleb over the valve plate to free any adhesions, followed by the injection of fluorouracil, 5 mg/0.2 ml. They have performed needling even three years or more after surgery and noted a successful outcome if there was an immediate drop in IOP. Nevertheless, this manoeuvre is difficult in small children and is seldom used. Another option is revision of the drainage implant, excising a portion of the capsule around the implant. However, encapsulation usually recurs. Most clinicians recommend adjunctive medical therapy, and if this fails, supplemental laser cyclophotocoagulation or even placement of an additional device in an unused quadrant.

Transient motility disorders, including diplopia and restriction of gaze, can occur in the early post-operative period, but they usually resolve spontaneously in a few weeks. Permanent motility disturbances can occur with all devices, although the larger ones, such as the Baerveldt implant, may pose a higher risk. The reported incidence varies from 1.9 % with the Ahmed valve in the series by Chen et al.,¹² to 7.3 % with the Baerveldt implant in the study by Overdam et al.²¹ This complication

can be secondary to a mass effect from the bleb or the implant itself, or to muscle dysfunction due to direct damage, inclusion in the capsule, posterior fixation (faden effect) due to scarring under the recti, or fat adhesion syndrome. These disorders are more common after placement in the superonasal or inferonasal quadrant.³

Hypotony, defined as an IOP under 5 mmHg, has been reported as very frequent in the series by Chen et al.,¹² with an incidence of 42.3 %, half of them requiring surgical management. In the same series, flat or shallow anterior chamber presented in 17.3 % of the eyes, two thirds of them requiring reformation. In other series its incidence is low, less than 10 %^{14,17,21} or even absent.^{11,13} Choroidal effusion, also an hypotony related complication, has been reported in between 2.1 to 4.2 % of the cases.^{6,8}

With regard to endophthalmitis, there are isolated cases in many series,^{5,8,12,14} and as many as 7.1 % in the series by Al Mobarak et al.¹³ In the Ahmed device it has been suggested that the valve mechanism and unidirectional flow may be partially protective against this complications, which has been reported almost exclusively in children, especially in those with tube exposure.^{23,36,37} Therefore, regular follow-ups specifically assessing the potential exposure are needed, with immediately treatment performed should this occur.

Complications of the posterior segment, such as retinal detachment, have also been described in children, with an incidence of 2.2 % in the series by Atratta et al.⁸ All occurred more than six months after the surgery, so the authors consider the relationship unclear. It occurred in 7.1 % of the cases in the series by Al Mobarak et al.,¹³ all in extremely buphthalmic eyes and 13.3 % in the series by Banitt et al.,²⁴ composed of Baerveldt devices implanted through pars plana. Isolated cases are reported in other series.^{8,12,17}

Vitreous haemorrhage appeared in 3.9 to 8 % of cases.⁵⁻⁸ In the series by Budenz et al.,⁵ all of them occurred in buphthalmic eyes and none was noticed in the first three months after the surgery, so the authors do not consider them to be directly related with the GDD procedure.

Other complications reported include hyphaema, cataract, inflammation and plate migration.

Results

Direct comparison of surgical outcomes is difficult because of the lack of uniformity in these studies, as they include several types of glaucoma of variable severity and use different devices.

The results of several series is listed in *Table 1*. Early post-operative success may be as high as 90 %, ^{11,21} but it decreases over time, to 40–60 % survival at 4–6 years using the Kaplan-Meier analysis.^{8,11,12} In our experience, survival using the Kaplan-Meier analysis has been 76 % at 6 months, 63 % at 1–3 years and 55 % at 4–8 years.²⁷ Ou et al.¹⁴ have studied the results after an implantation of a second GDD and have found a success rate of 86 % at one and two years decreasing to 69 % afterwards in the Kaplan-Meier survival analysis.

Most children need to reinitiate glaucoma treatment postoperatively. Previously reported percentages of patients without anti-glaucoma medication at last follow up vary from 17 to 64 %.^{3,21}

As risk factors for failure, the type of glaucoma, ethnicity, sex, post-operative complications and previous surgery have been proposed.

Table 1: Results of Glaucoma Drainage Devices in Paediatric Glaucoma

Author	GDD	Eyes (Patients)	Mean Age (Years)	Previous Surgery	Follow-up	Success	Survival (Years)						
							1	2	3	4	5		
Albis (2010)	Ahmed	128 (106)	7.58	32.8 %	25.7 months	68.8 %	82.4 %	78.8 %	70 %	41.6 %			
Al Mobarak (2009)	Ahmed	42 (36)	0.98	100 %	24 months		73.8 %	63.3 %					
Ou (2009)	Ahmed	30 (19)	1.8	93 %	57.6 months		63 %	50 %	50 %	41 %	33 %		
Banitt (2009)	Baerveldt	30 (30)	6.9	100 %	29.8 months	80 %	85 %	81 %	72 %				
Yang (2008)	Ahmed	34 (29)	5.5	44.1 %			68.6 %	45.7 %					
Autratta (2007)	Molteno Baerveldt	76 (76)	6.9	55.2 %	7.1 years	81.6 %	91 %	82 %	76 %	71 %	67 %		
Overdam (2006)	Baerveldt	55 (40)	3.3	61.8 %	31.9 months	80 %	94 %	94 %	85 %	78 %	44 %		
Chen (2005)	Ahmed	52 (41)	4.9	69.2 %	2.2 years		85.1 %	63.2 %	51.7 %	41.8 %			
Kirwan (2005)	Ahmed	19 (13)	8	47.4 %	32 months	95 %							
Rolim Moura (2005)	Baerveldt	48 (48)	4.1	30.9 %		77.1 %	90.5 %	83.7 %	74.4 %	58 %			
Budenz (2004)	Baerveldt	62 (60)	6.5	35.9 %	23.4 months		82 %	68 %	61 %	61 %	61 %		

Regarding the diagnosis, data are contradictory. Aphakic glaucoma has been found to have better prognosis in the study by Chen et al.,¹² with a success rate of 68.4 versus 45 % in congenital glaucoma and also in the series by Englert et al.,¹⁸ with success in 85.7 % of the cases. On the contrary, Yang et al.¹⁷ demonstrated better results in congenital glaucoma (75 versus 63.6 % in aphakic glaucoma) and Djodeyre et al.²³ noted this diagnosis to be significantly related to valve survival while Coleman et al.²⁵ suggested a higher risk of failure in congenital glaucoma. However, Budenz et al.⁵ found no difference in the success rate depending on the diagnosis and Autratta et al.⁸ who studied several factors, such as gender, age at surgery, previous surgeries, type of glaucoma and device implanted, pre-operative IOP and number of medications, found no relationship between success or failure and any of the factors.

Hispanic ethnicity and being female were associated with a higher risk of failure in the study by Ou et al.¹⁴ Moreover, Albis et al.¹¹ showed that any complication increased the likelihood of failure, as did previous glaucoma surgeries. This latter factor was also highlighted by Djodeyre et al.²³

With regard to vision, when it has been possible to determine the visual acuity before and after surgery, it worsened in 32.7 to 18.4 % of the cases.^{5,8,11,12}

Congenital glaucoma cases presented a tendency towards stabilisation or improvement of vision as compared to secondary or developmental glaucomas in the paper by Albis et al.¹¹

Glaucoma Drainage Devices versus Trabeculectomy

MMC-enhanced trabeculectomies provide good IOP control, but increase the risk of major complications like blebitis, endophthalmitis and bleb-leaks. In this regard, GDD may be a safer procedure in children.

No prospective, randomised trials comparing trabeculectomy with GDD in children are known to date, although there are two retrospective studies. Beck et al.⁴ compared the results of MMC-enhanced trabeculectomy versus Ahmed or Baerveldt devices in children under two and their results were favourable to the GDD, which had a cumulative success rate of 87 versus 36 % at 12 months and 53 versus 19 % at 72 months for the GDD group and the trabeculectomy group, respectively. However, complications were more frequent in the GDD group and these children also required more additional surgeries. In contrast, the Armenian Eye Care Project study¹⁰ reported similar success rates (88 versus 86 %) for the Ahmed valve and MMC enhanced trabeculectomy, with a mean follow-up of 18 months, similar results as those of Pakravan et al.²⁶

In conclusion, GDD can effectively control IOP in paediatric patients, but the advantages and complications should be weighed in each individual case. This procedure may achieve a sustained and prolonged IOP reduction in children, but we must bear in mind that complications may occur, especially tube malposition and exposure and multiple repeated surgeries may be necessary. ■

- Papadopoulos M, Khaw PT, Goniometry and trabeculectomy. In: Shaarawy T, Sherwood MB, Hitchings RA, Crowston JG, *Glaucoma vol. 2 Surgical management*, Elsevier, 2009:493.
- Molteno ACB, Ancer E, Biljon GV, Children with advanced glaucoma treated by draining implants, *S Afr J Ophthalmol*, 1973;1:55-61.
- Ishida K, Mandal AK, Netland PA, Glaucoma drainage implants in pediatric patients, *Ophthalmol Clin North Am*, 2005;18:431-42.
- Beck AD, Freedman S, Kammer J, Jin J, Aqueous shunt devices compared with trabeculectomy with mitomycin-C for children in the first two years of life, *Am J Ophthalmol*, 2003;136:994-1000.
- Budenz DL, Gedde SJ, Brandt JD, et al., Baerveldt glaucoma implant in the management of refractory childhood glaucomas, *Ophthalmology*, 2004;111:2204-10.
- Rolim de Moura C, Fraser-Bell S, Stout A, et al., Experience with the baerveldt glaucoma implant in the management of pediatric glaucoma, *Am J Ophthalmol*, 2005;139:847-54.
- Tesser R, Hess DB, Freedman SF, Combined intraocular lens implantation and glaucoma implant (tube shunt) surgery in pediatric patients: a case series, *J AAPOS*, 2005;9:330-5.
- Autratta R, Helmanova I, Oslejskova H, et al., Glaucoma drainage implants in the treatment of refractory glaucoma in pediatric patients, *Eur J Ophthalmol*, 2007;17:928-37.
- Khan AO, Al-Mobarak F, Comparison of polypropylene and silicone Ahmed valve survival 2 years following implantation in the first 2 years of life, *Br J Ophthalmol*, 2009;93:791-4.
- Hill R, Ohanesian R, Voskanyan L, Malayan A, The Armenian Eye Care Project: surgical outcomes of complicated paediatric glaucoma, *Br J Ophthalmol*, 2003;87:673-6.
- Albis-Donado O, Gil-Carrasco F, Romero-Quijada R, Thomas R, Evaluation of Ahmed glaucoma valve implantation through a needle-generated scleral tunnel in Mexican children with glaucoma, *Indian J Ophthalmol*, 2010;8:365-73.
- Chen TC, Bhatia LS, Walton DS, Ahmed valve surgery for refractory pediatric glaucoma: a report of 52 eyes, *J Pediatr Ophthalmol Strabismus*, 2005;42:274-83.
- Al-Mobarak F, Khan AO, Complications and 2-year valve survival following Ahmed valve implantation during the first 2 years of life, *Br J Ophthalmol*, 2009;93:795-8.
- Ou Y, Yu F, Law SK, Coleman AL, Caprioli J, Outcomes of Ahmed glaucoma valve implantation in children with primary congenital glaucoma, *Arch Ophthalmol*, 2009;127:1436-41.
- Freeman PD, Kahook MY, Curtis TH, Glaucoma drainage device implantation in children using fibrin glue, *J AAPOS*, 2010;14:169-71.
- Morad Y, Donaldson CE, Kim YM, et al., The Ahmed drainage implant in the treatment of pediatric glaucoma, *Am J Ophthalmol*, 2003;135:821-9.
- Yang HK, Park KH, Clinical outcomes after Ahmed valve implantation in refractory paediatric glaucoma, *Eye (Lond)*, 2009;23:1427-35.
- Englert JA, Freedman SF, Cox TA, The Ahmed valve in refractory pediatric glaucoma, *Am J Ophthalmol*, 1999;127:34-42.
- Kirwan C, O'Keefe M, Lanigan B, Mahmood U, Ahmed valve drainage implant surgery in the management of paediatric aphakic glaucoma, *Br J Ophthalmol*, 2005;89:855-8.
- Al-Mobarak F, Khan AO, Two-year survival of Ahmed valve implantation in the first 2 years of life with and without intraoperative mitomycin-C, *Ophthalmology*, 2009;116:1862-5.
- van Overdam KA, de Faber JT, Lemij HG, de Waard PW, Baerveldt glaucoma implant in paediatric patients, *Br J Ophthalmol*, 2006;90:328-32.
- Tanimoto SA, Brandt JD, Options in pediatric glaucoma after angle surgery has failed, *Curr Opin Ophthalmol*, 2006;17:132-7.
- Djodeyre MR, Peralta Calvo J, Abelairas Gomez J, Clinical evaluation and risk factors of time to failure of Ahmed Glaucoma Valve implant in pediatric patients, *Ophthalmology*, 2001;108:614-20.
- Banitt MR, Sidoti PA, Gentile RC, et al., Pars plana Baerveldt implantation for refractory childhood glaucomas, *J Glaucoma*, 2009;18:412-7.
- Coleman AL, Smyth RJ, Wilson MR, Tam M, Initial clinical

- experience with the Ahmed Glaucoma Valve implant in pediatric patients, *Arch Ophthalmol*, 1997;115:186–91.
26. Pakravan M, Homayoon N, Shahin Y, Ali Reza BR, Trabeculectomy with mitomycin C versus Ahmed glaucoma implant with mitomycin C for treatment of pediatric aphakic glaucoma, *J Glaucoma*, 2007;16:631–6.
 27. Colás-Tomás T, Gutiérrez-Díaz E, Tejada-Palacios P, et al., Intermediate results on the use of drainage devices for paediatric glaucoma, *Arch Soc Esp Ophthalmol*, 2012;87:38–43.
 28. al-Hazmi A, Zwaan J, Awad A, et al., Effectiveness and complications of mitomycin C use during pediatric glaucoma surgery, *Ophthalmology*, 1998;105:1915–20.
 29. Moss EB, Trope GE, Assessment of closing pressure in silicone Ahmed FP7 glaucoma valves, *J Glaucoma*, 2008;17:489–93.
 30. Christakis PG, Tsai JC, Zurakowski D, et al., Ahmed II, The Ahmed Versus Baerveldt study: design, baseline patient characteristics, and intraoperative complications, *Ophthalmology*, 2011;118:2172–9.
 31. Nassiri N, Kamali G, Rahnavardi M, et al., Ahmed glaucoma valve and single-plate Molteno implants in treatment of refractory glaucoma: a comparative study, *Am J Ophthalmol*, 2010;149:893–902.
 32. Tello C, Espana EM, Mora R, et al., Baerveldt glaucoma implant insertion in the posterior chamber sulcus, *Br J Ophthalmol*, 2007;91:739–42.
 33. Kim DK, Aslanides IM, Schmidt CM Jr, et al., Long-term outcome of aqueous shunt surgery in ten patients with iridocorneal endothelial syndrome, *Ophthalmology*, 1999;106:1030–4.
 34. Costa VP, Azuara-Blanco A, Netland PA, et al., Efficacy and safety of adjunctive mitomycin C during Ahmed glaucoma Valve implantation: a prospective randomized clinical trial, *Ophthalmology*, 2004;111:1071–6.
 35. Cantor L, Burgoyne J, Sanders S, et al., The effect of mitomycin C on Molteno implant surgery: a 1-year randomized, masked, prospective study, *J Glaucoma*, 1998;7:240–6.
 36. Al-Torbak AA, Al-Shahwan S, Al-Jadaan I, Al-Hommadi A, Edward DP, Endophthalmitis associated with the Ahmed glaucoma valve implant, *Br J Ophthalmol*, 2005;89:454–8.
 37. Gutiérrez-Díaz E, Montero-Rodríguez M, Mencia-Gutiérrez E, et al., Propionibacterium acnes endophthalmitis in Ahmed glaucoma valve, *Eur J Ophthalmol*, 2001;11:383–5.