

## Surgery for Myopic Macular Hole Without Retinal Detachment

Jose Garcia-Arumi,<sup>1,2</sup> Anna Boixadera,<sup>2</sup> Vicente Martinez-Castillo,<sup>2</sup> Miguel Angel Zapata<sup>2</sup> and Carme Macià<sup>2</sup>

1. Department of Ophthalmology, Instituto de Microcirugía Ocular; 2. Department of Ophthalmology, Hospital Vall d'Hebron, Barcelona, Spain

### Abstract

The purpose of this paper is to review the indications, surgical technique and surgical outcome of myopic macular holes (MHs). In myopic MH, the use of optical coherence tomography has been very useful both in the diagnosis and follow-up after surgery due to the difficulty in biomicroscopic diagnosis in high myopes. Myopic MH surgery is more difficult than idiopathic MH surgery due to the increased axial length, retinal pigment epithelium and choroidal atrophy, and thinner retina making internal limiting membrane and posterior hyaloid staining more important. Myopic MH vitreoretinal surgery achieves comparable anatomical success rates when compared with idiopathic MHs except in cases with posterior staphyloma and axial lengths equal to or over 30 mm where a macular buckle may be needed. The closure of myopic MH decreases the risk of retinal detachment secondary to MH.

### Keywords

Myopic macular hole, pars plana vitrectomy, optical coherence tomography, high myopia, foveoschisis, internal limiting membrane peeling, macular buckle

**Disclosure:** The authors have no conflicts of interest to declare.

**Received:** 12 October 2011 **Accepted:** 6 January 2012 **Citation:** *European Ophthalmic Review*, 2012;(6)4:204-7 DOI: 10.17925/EOR.2012.06.04.204

**Correspondence:** Jose Garcia-Arumi, Department of Ophthalmology, Instituto de Microcirugía Ocular, C/ Josep Maria Lladó no 3, 08002, Barcelona, Spain.  
E: 17215jga@comb.es

### Asymptomatic Myopic Macular Hole

Secondary macular hole (MH) can occur in eyes with high myopia and the characteristics and demographics of these MHs differ from those of most idiopathic holes. Myopic MHs tend to develop in younger subjects and may be associated with a rhegmatogenous retinal detachment surrounding the hole.<sup>1</sup> The mean age of patients in most myopic MH series is mid-fifties, whereas the mean age in idiopathic MH series is the upper sixties. The earlier onset of myopic MHs may be related to abnormal vitreomacular traction in myopic eyes, premature vitreous liquefaction, or other unknown factors predisposing these eyes to premature MHs – there is a predominance in women. The diagnosis may be difficult because of retinal pigment epithelium (RPE) and choroidal atrophy. Biomicroscopic diagnosis of MH in highly myopic eyes without retinal detachment is sometimes difficult. This could be due to a lack of contrast between the MH and RPE, particularly in the presence of a deep posterior staphyloma and severe chorioretinal atrophy. In asymptomatic myopic eyes with good vision, optical coherence tomography (OCT) has revealed the presence of MH.<sup>2</sup> Asymptomatic MH is more prevalent in eyes with higher degrees of myopia and pronounced posterior staphyloma. In the authors' experience of macular examination with optical coherence tomography in severely myopic eyes with posterior staphyloma, the authors have found that retinal detachment, retinoschisis, or both, are often seen at the fovea, suggesting that foveal retinal detachment may precede the onset of MH formation. Also, in these patients apparent complete posterior vitreous detachment (PVD) confirmed by biomicroscopy does not prevent vitreous remnants adhering to the retina, since vitreoschisis and a posterior vitreous cortex adherence has been found to persist. It may also be preceded by a foveal detachment causing the fovea to become extremely thin. The action of a tangential tensile force on this thinner retina might explain the occurrence of MH.

The exact relationship between retinoschisis and MH formation is not known; it has been suggested that retinoschisis develops before the MH.<sup>3</sup> Myopic foveoschisis, recently described based on OCT, may affect between 9 to 20 % of highly myopic eyes with posterior staphyloma.<sup>4</sup> Foveoschisis may develop in these eyes because of traction by either an epiretinal membrane or posterior vitreous cortex on the retina and it is believed to impair macular function and in some cases, result in MH formation and retinal detachment.<sup>5,6</sup> In many cases foveoschisis is asymptomatic, since initially the foveal detachment may be shallow and allow enough oxygen and nutrient diffusion from the choriocapillaris to the photoreceptors. It has been suggested that the combination of myopic foveoschisis and foveal detachment can lead to a MH.<sup>6,7</sup> Kobayashi et al. evaluated the efficacy of vitreous surgery for highly myopic eyes with foveal detachment and retinoschisis. Vitreous surgery may have a role as a prophylactic treatment for highly myopic eyes with a high risk of MH development.<sup>7</sup> It has been observed by Gaucher et al.<sup>6</sup> that especially when a tractional premacular structure is present on OCT, around 44 % of patients develop MH spontaneously or during follow-up after surgery. Gaucher et al.<sup>6</sup> identified two poor prognostic factors: the presence of a premacular structure and a foveal detachment. The premacular structure is seen as a hyper-reflective line on OCT scans and may represent a partially detached and condensed posterior hyaloid or a hyaloid lined with fibrous membranous proliferations. In addition a tense and rigid internal limiting membrane (ILM) has been described which affects the fit of the retinal boundary to the outer curvature of the eyeball.

In developed countries the prevalence of myopia is reported to be between 11 and 36 %.<sup>6</sup> The prevalence of degenerative myopia varies from 0.2 % in Egypt to 9.6 % in Spain<sup>8</sup> and 18 % in Japan.<sup>3,9</sup>

## Indications

All patients with a full-thickness myopic MH should undergo the following evaluations: best corrected visual acuity (BCVA), intraocular pressure measurement, slit-lamp examination of the anterior segment and fundus biomicroscopy. Pre-operative OCT should be performed using spectral domain OCT. If a full-thickness macular hole is diagnosed the patient should be scheduled for surgery.

## Myopic Macular Hole Surgery

The patients with a myopic MH without retinal detachment undergo a standard three-port pars plana vitrectomy. The authors normally perform 23-gauge pars plana vitrectomy. Simultaneous refractive lens exchange is performed in phakic eyes in most cases with phacoemulsification and intraocular lens placement in the capsular bag. The posterior hyaloid needs to be removed by active suction (in the few cases that do not have a posterior vitreous detachment) and triamcinolone or brilliant blue may be used to visualise persistence of posterior attachments of the posterior hyaloid (vitreoschisis). The ILM is then stained with brilliant blue (Fluoron GmbH, Germany), a vital dye with no retinal toxicity, which normally achieves a good ILM stain. Before brilliant blue was available, indocyanine green (ICG) dye (concentration 0.025 % during one minute) was used. Although ICG dye stains the ILM better, possible retinal toxicity, which has been found to be dose-dependent<sup>10</sup> needs to be taken into consideration. We routinely perform ILM peeling with intraocular forceps. The size of the ILM-peeling should range from 4 to 6 mm in diameter around the fovea. It should be mentioned that the ILM in highly myopic eyes seems to be thinner and tends to fragment into pieces requiring great care during ILM peeling so as to not create an iatrogenic MH.<sup>11</sup> Finally, fluid–air exchange is performed followed by injection of 10 % octafluoropropane (C3F8). The patients are instructed to maintain prone position post-operatively for one week.

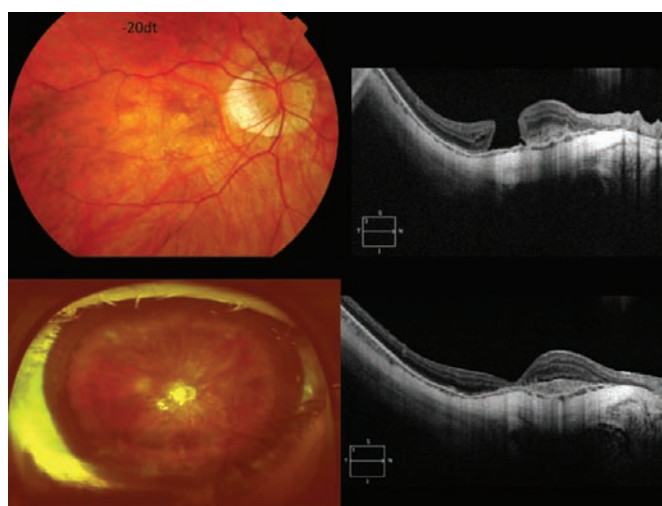
## Surgical Outcome

MH surgery can substantially improve visual acuity in myopic eyes, but the results do not seem to be as favourable as those reported for typical idiopathic MHs. Vitreoretinal surgery may effectively manage myopic MHs, thus improving the anatomic and visual outcomes (see *Figures 1–4*). In some cases the complete closure of the MH is not achieved and although the MH flattens and decreases in size there is not a complete apposition of the MH borders; in these cases the visual acuity normally improves (see *Figure 5*).

An important observation is that by closing the MH, vitreoretinal surgery may decrease the risk of a posterior retinal detachment in highly myopic eyes.<sup>8</sup> The visual results with one or more surgeries are good, with similar mean final visual acuity and improvement of three or more Snellen lines when compared with series of idiopathic MH.<sup>12</sup> We believe that MH surgery should be contemplated in patients with myopic MH.<sup>8,13</sup>

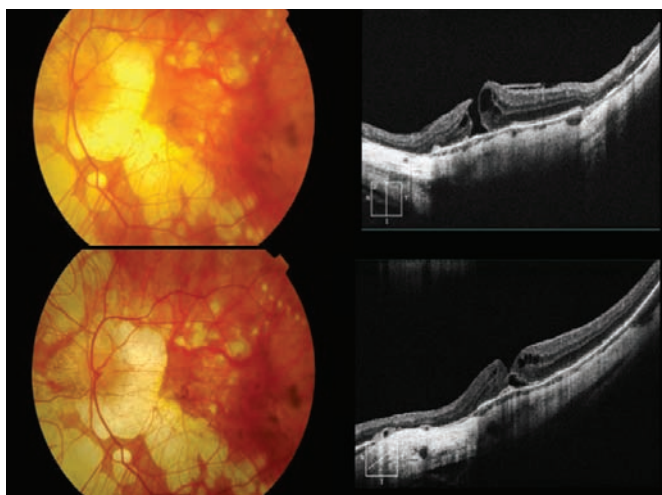
Certain differences between myopic and idiopathic MH should be considered during the surgical procedure. Highly myopic eyes present increased axial length, RPE and choroidal atrophy, and a thinner retina, which produce poorer surgical visibility. As the working distance between the macula and the sclerotomy in highly myopic eyes is greater, the surgeon has to enlarge the distance between the two sclerotomies in order to work with an adequate angle between the two instruments. The position of the instruments is more vertical, and in some cases the instruments may be too short, especially when there is a marked posterior staphyloma. There is an increased risk of complications, including retinal tears, rhegmatogenous retinal detachment, photic

**Figure 1: Pre- and Post-operative Myopic Macular Hole and Choroidal Neovascularisation**



Top left: Colour fundus photograph of a 50-year-old man with macular hole and inactive juxtafoveal choroidal neovascularisation. Best corrected visual acuity before surgery was 20/125 with refractive error of -20 dioptres. Top right: Spectral domain optical coherence tomography (OCT) showing a myopic macular hole (MH) and choroidal neovascularisation. Bottom: Colour fundus photograph one day after surgery with the vitreous cavity filled with gas and OCT showing complete MH closure.

**Figure 2: Myopic Macular Hole with Post-operative Macular Hole Closure and External Neurosurgery Detachment**

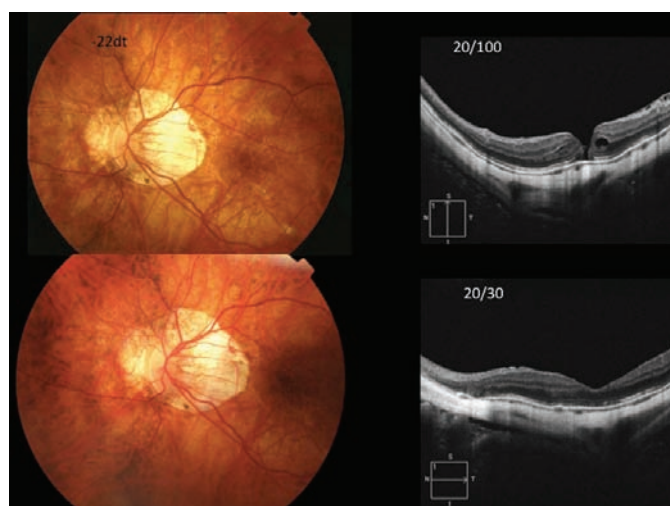

Top left: Colour fundus photograph of a 48-year-old woman with macular hole and posterior staphyloma. Best corrected visual acuity before surgery was 20/100 and axial length was 28 mm. Top right: Spectral domain optical coherence tomography (OCT) showing a myopic macular hole (MH) and associated epiretinal membrane. Bottom: Colour fundus photograph one month after surgery and OCT showing complete MH closure in the internal layers with an external neurosensory detachment.

toxicity or retinal pigment epithelial alterations, exudative retinal detachment, glaucoma and proliferative vitreoretinopathy.<sup>14</sup>

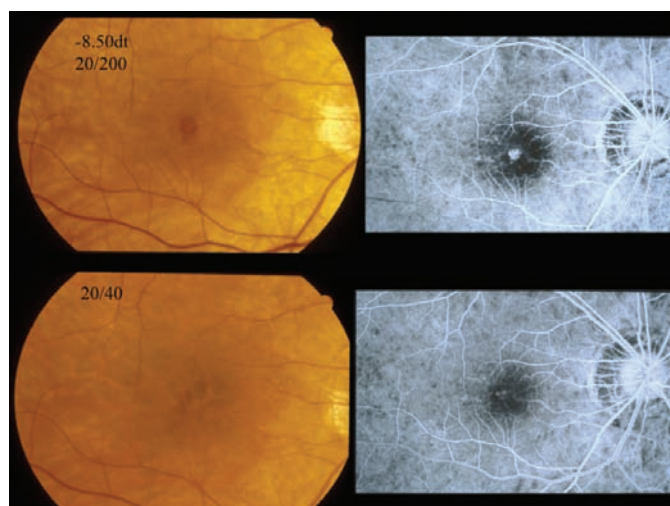
Fibroblast-like cells, myofibroblasts and glial cells have been found on the inner surface of the ILM in myopic MHs.<sup>15,16</sup> Based on these findings, it has been suggested that ILM removal would eliminate all tractional forces on the fovea and subsequently improve the flexibility of the retina, favouring MH closure and retinal re-attachment. Wide dissection of the ILM up to the limits of the staphyloma is important. ILM detachment can have a major role in

**Figure 3: Myopic Macular Hole with Successful Surgery**



Top left: Colour fundus photograph of a 58-year-old woman with macular hole and -22 dioptres. Best corrected visual acuity before surgery was 20/100. Top right: Spectral domain optical coherence tomography (OCT) showing a myopic macular hole (MH). Below: Colour fundus photograph two months after surgery and OCT showing complete MH closure. Visual acuity was 20/30.

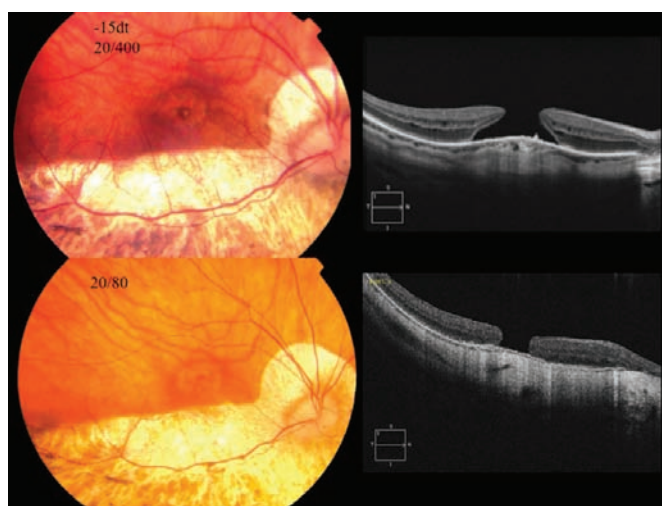
**Figure 4: Fluorescein Angiography in Myopic Macular Hole**



Top left: Colour fundus photograph of a 48-year-old man with -8.5 dioptres and a macular hole. Best corrected visual acuity before surgery was 20/200. Top right: Fluorescein angiography showing a myopic MH window defect. Below: Colour fundus photograph two months after surgery and fluorescein angiography showing MH closure. Visual acuity was 20/40.

the development of myopic foveoschisis.<sup>17</sup> In some cases of myopic MH, the surgeon has to dissect the thickened posterior hyaloid as well as the ILM.

**Figure 5: Myopic Macular Hole that Remains Flat and Open after Surgery**



Top left: Colour fundus photograph of a 64-year-old woman with macular hole, marked inferior chorioretinal atrophy and -15 dioptres. Best corrected visual acuity before surgery was 20/400. Top right: Spectral domain optical coherence tomography (OCT) showing a myopic macular hole (MH). Below: Colour fundus photograph two months after surgery and OCT showing incomplete MH closure with visual acuity improvement to 20/80.

Suda et al.<sup>18</sup> using spectral-domain OCT have determined that eyes with greater axial length and refractive error and more posterior staphyloma have a greater chance of anatomical failure after vitrectomy. According to Suda et al., patients with axial lengths of 26 mm or more had a final success rate of 91 % being similar to the findings previously published by Garcia-Arumi et al.<sup>8</sup> However, the anatomic success rate was 0 % in the three patients of the series of Suda et al. with axial length over 30 mm.

In case-control studies Sulkes et al. and Kobayashi et al. found no association between axial length and anatomical success of surgery.<sup>13,15</sup> However, these studies did not use OCT to confirm closure of the MH and it must be taken into consideration that it can be difficult to determine whether MHs are closed by biomicroscopic examination alone.

## Conclusion

In summary, the successful anatomic closure of myopic MHs is similar to idiopathic MHs but less so when a posterior staphyloma is present or in axial lengths of over 30 mm. To improve the anatomic success rate, it is important to completely remove the posterior cortical vitreous, the ILM and epiretinal membranes if present. There is increased surgical difficulty, and for this reason it is particularly important to stain the ILM. The risk of re-opening the MH is higher, especially in those cases with posterior staphyloma in which the use of a macular bucking may be considered. A definite benefit derived from MH closure in this group of patients is the reduced risk of retinal detachment secondary to MH. ■

- Morita H, Ideta H, Ito K, et al., Causative factors of retinal detachment in macular holes, *Retina*, 1991;11(3):281-4.
- Coppé AM, Ripanelli G, Parisi V, et al., Prevalence of asymptomatic macular holes in highly myopic eyes, *Ophthalmology*, 2005;112(12):2103-9.
- Tano Y, Pathologic myopia: where are we now?, *Am J Ophthalmol*, 2002;134(5):645-60.
- Baba T, Ohno-Matsui K, Futagami S, et al., Prevalence and characteristics of foveal retinal detachment without macular hole in high myopia, *Am J Ophthalmol*, 2003;135(3):338-42.
- Takano M, Kishi S, Foveal retinoschisis and retinal detachment in severely myopic eyes with posterior staphyloma, *Am J Ophthalmol*, 1999;128(4):472-6.
- Gaucher D, Haouchine D, Tadayoni R, et al., Long-term follow-up of high myopic foveoschisis: natural course and surgical outcome, *Am J Ophthalmol*, 2007;143(3):455-62.
- Kobayashi H, Kishi S, Vitreous surgery for highly myopic eyes with foveal detachment and retinoschisis, *Ophthalmology*, 2003;110(9):1702-7.
- García-Arumi J, Martínez V, Puig J, Corcostegui B, The role of vitreoretinal surgery in the management of myopic macular hole without retinal detachment, *Retina*, 2001;21(4):332-8.
- Curtin BJ, *The myopias: basic science and clinical management*, Philadelphia, US: Harper and Row, 1985.
- Rodrigues EB, Meyer CH, Mennel S, Farah ME, Mechanisms of intravitreal toxicity of indocyanine green dye: implications for chromovitrectomy, *Retina*, 2007;27:958-70.
- Kwok AK, Lai TY, Yip WW, Vitrectomy and gas tamponade without internal limiting membrane peeling for myopic foveoschisis, *Br J Ophthalmol*, 2005;89:1180-3.

12. Patel SC, Loo RH, Thompson JT, Sjaarda RN, Macular hole surgery in high myopia, *Ophthalmology*, 2001;108(2):377-80.
13. Sulkes DJ, Smiddy WE, Flynn HW, Feuer W, Outcomes of macular hole surgery in severely myopic eyes: a case-control study, *Am J Ophthalmol*, 2000;130(3):335-9.
14. Park SS, Marcus DM, Duker JS, et al., Posterior segment complications after vitrectomy for macular hole, *Ophthalmology*, 1995;102(5):775-81.
15. Kadosono K, Yazama F, Itoh N, et al., Treatment of retinal detachment resulting from myopic macular hole with internal limiting membrane removal, *Am J Ophthalmol*, 2001;131(2):203-7.
16. Kumar A, Wagh VB, Prakash G, et al., Visual outcome and electron microscopic features of indocyanine green-assisted internal limiting membrane peeling from macular hole of various aetiologies, *Indian J Ophthalmol*, 2005;53(3):159-65.
17. Sayanagi K, Morimoto Y, Ikuno Y, Tano Y, Spectral-domain optical coherence findings in myopic foveoschisis, *Retina*, 2010;30:623-8.
18. Suda K, Hangai M, Yoshimura N, Axial length and outcomes of macular hole surgery assessed by spectral-domain optical coherence tomography, *Am J Ophthalmol*, 2011;151:118-27.e1.
19. Kobayashi H, Kobayashi K, Okinami S, Macular hole and myopic refraction, *Br J Ophthalmol*, 2002;86:1269-73.