

Advances in the Surgical Management of Glaucoma – The Role of the EX-PRESS® Glaucoma Filtration Device

A report on the satellite symposium 'Advances in glaucoma surgery: new evidence in filtration surgery' held at the World Glaucoma Congress, 30 June 2011, Paris

David W Cope, Medical Writer, Touch Medical Communications, UK

Reviewed for scientific accuracy by Robert Fechtner,¹ Leo de Jong,² Elie Dahan,³ Malik Kahook,⁴ Marlene Moster⁵ and Ivan Goldberg⁶

1. Institute of Ophthalmology and Visual Science, New Jersey Medical School, Newark, NJ, US; 2. Academic Medical Centre, Amsterdam, The Netherlands; 3. Ein Tal Eye Hospital, Tel Aviv, Israel; 4. Department of Ophthalmology, University of Colorado, Denver, CO, US; 5. Wills Eye Institute, Philadelphia, PA, US; 6. Glaucoma Unit, Sydney Eye Hospital, and Discipline of Ophthalmology, University of Sydney, Australia

Abstract

Clinicians aim to arrest the glaucomatous process by reducing intraocular pressure (IOP).¹⁻⁵ Available strategies include medical, laser and surgical techniques. Trabeculectomy is the traditional standard drainage surgery technique to achieve this. These MIGS techniques therefore appear to be adequate for patients whose glaucomatous damage is mild to moderate and whose target IOPs fall into this range. To achieve lower IOPs in patients with more advanced visual loss, efforts have simultaneously been made to fine-tune trabeculectomy. The use of the EX-PRESS® Glaucoma Filtration Device (Alcon) under a scleral flap is one such approach. How does the EX-PRESS Glaucoma Filtration Device benefit the conventional trabeculectomy procedure? What tips and tricks can contribute to its successful use? How safe is it? Is the additional cost to our health system justifiable? The satellite symposium 'Advances in glaucoma surgery: new evidence in filtration surgery', held at the 2011 World Glaucoma Congress, chaired by Dr Ivan Goldberg and sponsored by Alcon, set out to try to answer these questions.

Keywords

Aqueous outflow, filtration surgery, glaucoma, intraocular pressure, trabeculectomy

Disclosure: David Cope is a medical writer at Touch Medical Communications.

Received: 30 August 2011 **Accepted:** 20 October 2011 **Citation:** *European Ophthalmic Review*, 2012;6(2):83-91 DOI: 10.17925/EOR.2012.06.02.83

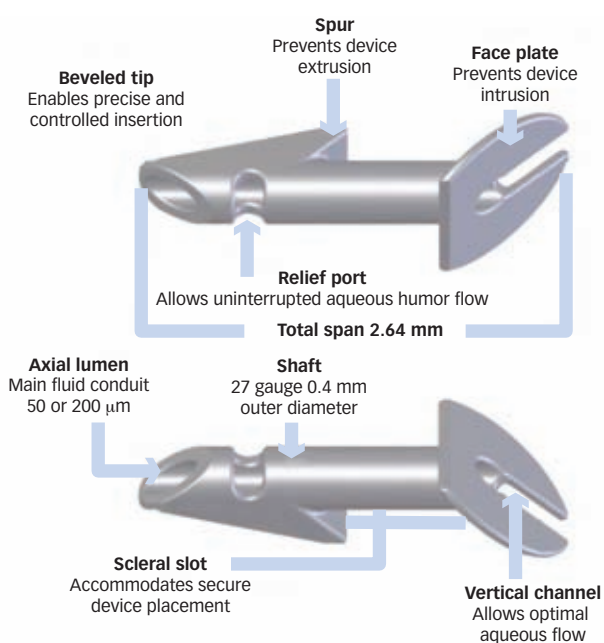
Support: The editorial support for and publication of this article were funded by Alcon.

Glaucoma is a progressive optic neuropathy caused by the death of retinal ganglion cells and degeneration of their axons in the optic nerve.⁶ This leads to damage of the optic disc and subsequent loss of the visual field.⁶ Glaucoma is known to be one of the principal causes of blindness worldwide.^{7,8} Population-based data indicate that 1–9 % of adults older than 40 years have some form of glaucoma, with prevalence depending on age, gender and ethnic background.^{6,9,10} In 2010, 60.5 million people worldwide were estimated to have glaucoma and, because of increasing population numbers combined with increased population ageing, this will probably affect approximately 80 million people by 2020.¹¹ The economic burden associated with glaucoma globally is considerable and related not only to treatment costs, but also to rehabilitation and patient costs, including increased household costs and loss of earnings.^{12,13}

Although statistically elevated intraocular pressure (IOP) is no longer a defining criterion for glaucoma,⁶ it is a major risk factor for the development and progression of the disease.¹⁻⁵ Medical, laser and surgical therapeutic treatments that reduce IOP can delay or halt, but not reverse, disease progression.^{14,15} Trabeculectomy has been

the traditional standard of filtration surgery for 40 years, and is the primary method for the surgical management of open-angle glaucoma following the failure of medical therapy or non-incisional procedures such as laser trabeculoplasty.¹⁶⁻¹⁸ Trabeculectomy can control IOP effectively,¹⁹⁻²² even five years after surgery.²³⁻²⁷ However, published success rates vary considerably, in part because of the lack of standard definitions for success²⁸ and also because trabeculectomy is associated with complications, including early postoperative hypotony, bleb leaks, blebitis and bleb failure, choroidal effusion, endophthalmitis, hyphaema, shallowing of the anterior chamber and accelerated cataract progression.¹⁶ Moreover, trabeculectomy can fail to control IOP adequately in some patients, who therefore require a secondary surgical intervention such as a repeat trabeculectomy or implantation of a drainage device.²⁹ As a result, some studies indicate that the risks associated with trabeculectomy outweigh the benefits.^{24,30} However, incremental improvements that refined the trabeculectomy technique have proved valuable, including the use of a corneal traction suture to control eye position; appropriate and optimal use of wound-healing techniques to prevent fibrosis

Figure 1: The P-series EX-PRESS Glaucoma Filtration Device



and scarring; use of a fornix-based conjunctival flap; creation of a large scleral flap to maximise posterior aqueous flow and enable the development of a diffuse bleb; adjustable sutures to control aqueous flow; and a standardised punch to control trabeculectomy aperture.^{31–34}

One such incremental advance is the development of the EX-PRESS® Glaucoma Filtration Device (Alcon), an attempt to standardise trabeculectomy aperture and enable a predictable aqueous flow.³⁵ The satellite symposium ‘Advances in glaucoma surgery: new evidence in filtration surgery’, held at the World Glaucoma Congress 2011, examined some of the recent findings to evaluate the performance of the EX-PRESS Device and the role it can play in improving conventional trabeculectomy surgery.

What is the EX-PRESS Glaucoma Filtration Device and How is it Different from Traditional Trabeculectomy?

Report on a Presentation by Robert Fechtner

Dr Fechtner’s presentation provided a broad overview of the EX-PRESS Glaucoma Filtration Device and began by describing the device and its properties. It is a <3 mm long implant made from 316L medical grade stainless steel that is fully biocompatible with the eye (see *Figure 1*).^{35,36} The device comes with a spur to prevent extrusion and an end-plate to prevent intrusion into the anterior chamber. It is non-valved and designed to divert aqueous away from the anterior chamber to the subconjunctival space, in a similar manner to traditional trabeculectomy, with the flow being controlled by the diameter of the lumen and resistance from a scleral flap.³⁵ In addition, a vertical slot in the end-plate is designed to facilitate the generation of a diffuse bleb.³⁵ The P-series EX-PRESS Device is available with a lumen size of 50 or 200 μm. Standardisation of the lumen therefore makes one step of the trabeculectomy procedure more predictable.

Initial versions of the EX-PRESS Device were implanted directly under the conjunctiva through full thickness sclera, but this led to excessive postoperative complications, which included sustained hypotony (because of the lack of resistance to aqueous flow), subconjunctival

scar-tissue formation, endophthalmitis and conjunctival erosions.^{37–39} In 2005, the procedure was improved by implanting the EX-PRESS Device under a half-thickness scleral flap.⁴⁰ In the initial description of the revised procedure, IOP was well-controlled at 24 months with few complications, transient hypotony being the most common.⁴⁰ As with traditional trabeculectomy, the current EX-PRESS Device implantation technique is therefore a guarded procedure. In 2007, the results of the first large, retrospective study to compare guarded EX-PRESS Device implantation trabeculectomies with traditional trabeculectomies were published.⁴¹ The EX-PRESS Device was implanted in 50 eyes of 49 patients and a traditional trabeculectomy performed in 50 eyes of 47 patients. The IOP reduction from baseline was similar in both groups after 12 months (39.9 and 42.1 %, respectively) with fewer incidences of early postoperative hypotony and choroidal effusion in those implanted with the EX-PRESS Device.⁴¹ This initial study therefore showed that implantation of the EX-PRESS Device was as effective as traditional trabeculectomy in controlling IOP, but with fewer postoperative complications.

Dr Fechtner then described the standard procedure for implantation of the EX-PRESS Device (see *Figure 2*).⁴⁰ A fornix-based conjunctival flap is created in the nasal or temporal upper quadrant, as in traditional trabeculectomy, leaving sufficient room for additional surgery if required later. Appropriate wound-healing modulating agents techniques are applied to the sclera to prevent potential scarring and fibrosis. A limbus-based scleral flap of approximately half-thickness is dissected up to the clear cornea, similar to traditional trabeculectomy, of sufficient size to cover the device end-plate. Dr Fechtner suggests a minimum size of 3 x 3 millimetres for surgeons new to the technique. At this point a paracentesis can be created and the chamber deepened before the anterior chamber is entered with a 25–27 gauge needle under the scleral flap posterior to the blue–grey transition zone between the sclera and cornea. The EX-PRESS Device is inserted through the perforation using the EX-PRESS Glaucoma Filtration Device delivery system (see *Figure 3*). The device is loaded onto the wire of the delivery system and released once in position by depression of a button on the EDS that withdraws the guide wire. Finally, as in traditional trabeculectomy, the scleral flap is sutured with releasable or adjustable sutures and the conjunctival flap sutured watertight. Postoperative care with anti-inflammatories and antibiotics is also similar to that after traditional trabeculectomy. As well as providing good control of IOP,^{40,41} EX-PRESS Device implantation has several advantages compared with traditional trabeculectomy. Implantation of the EX-PRESS Device does not require a great leap in surgical skill; the skills required are the same as those for traditional trabeculectomy. Intraoperatively, there is no requirement for iridectomy so there is less inflammation and less potential for bleeding. It standardises one step in the trabeculectomy procedure, which enables predictable aqueous outflow. Finally, as already indicated, the incidence of postoperative complications is fewer compared than in traditional trabeculectomy.⁴¹ Some eyes that might be candidates for trabeculectomy may not necessarily be candidates for EX-PRESS Device implantation. There must be sufficient conjunctiva and sclera to create a flap of appropriate size. In the setting of extensive prior surgery or scarring, there may not be enough room for an EX-PRESS Device. Similarly, there should be enough room in the angle to accommodate the device. When there is not enough room for an EX-PRESS Device it may still be possible to perform traditional trabeculectomy. The device also has a financial cost. Dr Fechtner finished his presentation by saying that this cost may be offset by reduced operating times when using the EX-PRESS Device and potentially reduced lifetime costs to the healthcare system.

Table 1: Complete Success Rates for Defined Target Intraocular Pressures over Five Years following EX-PRESS Device Implantation or Traditional Trabeculectomy

Year	IOP ≤ 18 mmHg			IOP ≤ 15 mmHg		
	EX-PRESS Device (%)	Trabeculectomy (%)	p-value	EX-PRESS Device (%)	Trabeculectomy (%)	p-value
1	86.8	61.5	0.01	80.0	51.3	0.01
2	76.3	51.3	0.02	71.1	48.7	0.046
3	66.7	41.0	0.02	66.7	38.5	0.01
4	64.1	46.2	0.11	61.5	46.2	0.17
5	59.0	46.2	0.25	59.0	46.2	0.26

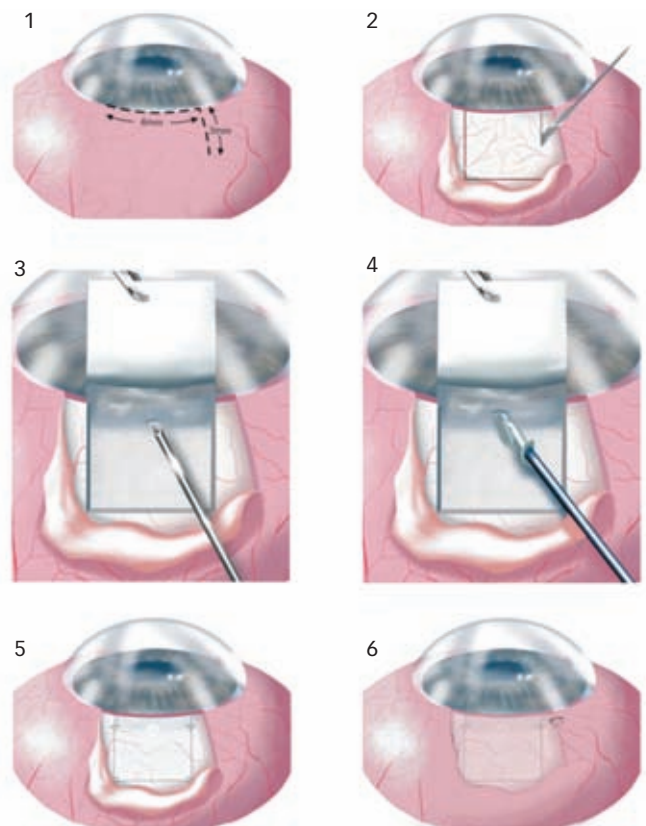
Number of patients in the EX-PRESS Device implantation group = 39; number of patients in the trabeculectomy group = 39; IOP = intraocular pressure. Adapted from de Jong, et al., 2011.⁴⁵

Improving the Efficacy and Predictability of Filtration Surgery with the EX-PRESS Glaucoma Filtration Device

Report on a Presentation by Leo de Jong

There is a lack of prospective, randomised, long-term clinical studies that compare trabeculectomy with the EX-PRESS Device with trabeculectomy alone. Most studies to date have been retrospective and short-to-medium term only.⁴⁰⁻⁴³ In his presentation, Dr de Jong presented recent findings from a prospective five-year study building on previous results that compared EX-PRESS Device implantation with trabeculectomy alone.⁴⁴

In the current study, 39 eyes were implanted with the EX-PRESS Device and 39 underwent traditional trabeculectomy in patients who had primary open-angle glaucoma and inadequately controlled IOP.⁴⁵ Individuals were excluded if they had other ocular diseases or had received previous ocular surgery other than cataract extraction.⁴⁵ The study evaluated not only the differences in IOP levels between the two treatments, but also the requirement for additional IOP-lowering medications or further surgical procedures to maintain IOP at target pressures of either ≤ 18 mmHg or, more stringently, of ≤ 15 mmHg.⁴⁵ At baseline, IOP values in the two treatment groups were similar, but at one, two and three years after surgery, IOP levels were significantly lower in patients implanted with the EX-PRESS Device than in patients who underwent trabeculectomy alone (see *Figure 4*).⁴⁵ IOP levels were similar in the two treatment groups at years four and five. At all time points the number of patients receiving additional IOP-lowering medications was lower in those implanted with the EX-PRESS Device than in those in the traditional trabeculectomy group, as was the mean number of drugs used per patient.⁴⁵ Complete success rates, defined as IOP ≤ 18 mmHg or ≤ 15 mmHg without additional medications or surgical intervention, were significantly higher up to three years after treatment in the patients receiving the EX-PRESS Device and equivalent in years four and five (see *Table 1*).⁴⁵ Moreover, the time-to-treatment failure was significantly longer in the EX-PRESS Device group than in the traditional trabeculectomy group for target IOP levels of ≤ 18 mmHg or ≤ 15 mmHg with response criteria of complete success (with no medications and no surgery – see *Figure 5*) and partial success (with medications, but no surgery).⁴⁵ Time-to-treatment failure also favoured the EX-PRESS Device over traditional trabeculectomy with a response criterion of marginal success (with both medications and surgery).⁴⁵ Patients who underwent trabeculectomy alone required more surgical interventions than patients implanted with the EX-PRESS Device. For two patients (one in each group), the primary surgery failed and both individuals required a Baerveldt device implant. More patients required bleb needling in the traditional trabeculectomy group compared with those implanted with the EX-PRESS Device (nine versus three, respectively) and more patients required cataract

Figure 2: Implantation of the EX-PRESS Glaucoma Filtration Device

A: A fornix-based conjunctival flap is created in the upper quadrant. B: A 50% depth limbal-based scleral flap is created. C: The anterior chamber is penetrated under the scleral flap with a 25–27 gauge needle entering through the blue-grey transition zone between the sclera and the clear cornea. D: The EX-PRESS Glaucoma Filtration Device is inserted. E: The scleral flap is sutured. F: The conjunctival flap is sutured watertight. Adapted from Dahan and Carmichael, 2005.⁴⁰

extraction in the traditional trabeculectomy group than in the EX-PRESS Device group (eight versus five, respectively).⁴⁵

Dr de Jong summarised the findings of his study: after five years of follow-up, the EX-PRESS Device provided better IOP control than trabeculectomy alone for at least the first three years. Moreover, the time-to-treatment failure was longer in patients who received the EX-PRESS Device irrespective of the criteria used to define the response. Patients who underwent EX-PRESS Device implantation required fewer IOP-lowering medications or additional surgical interventions than patients in the trabeculectomy alone group. Finally, Dr de Jong postulated that the equivalence in IOP control at years four and five between those patients implanted with the EX-PRESS Device and those who underwent trabeculectomy alone

Figure 3: The EX-PRESS Glaucoma Filtration Device Delivery System

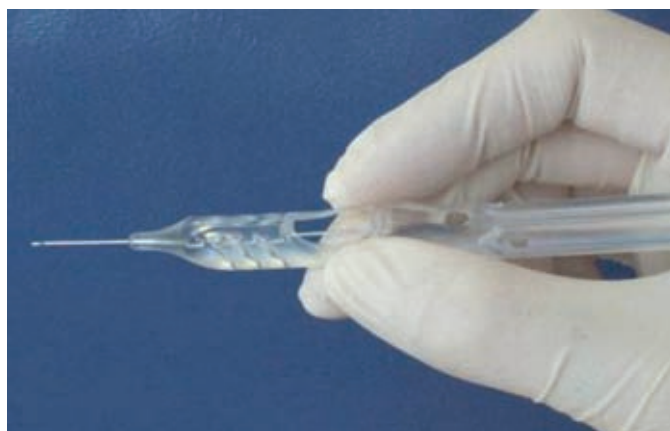
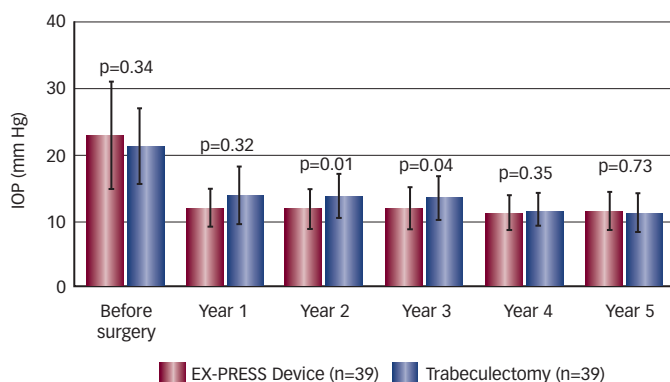


Figure 4: Intraocular Pressure Control over a Five-year Follow-up Period after EX-PRESS Device Implantation or Traditional Trabeculectomy



Data are presented as mean ± standard deviation; n = number of patients in each group. IOP = intraocular pressure. Adapted from de Jong et al., 2011.⁴⁵

may result from the increased need for additional medical or surgical intervention to regulate inadequately controlled IOP in the trabeculectomy alone group.

Improving Patient Visual Recovery in Filtration Surgery – Results from a Newly Published Study on the EX-PRESS Glaucoma Filtration Device Report on a Presentation by Malik Kahook

Important aspects of glaucoma surgery are not only the extent and longevity of IOP reduction to prevent further damage to the optic nerve, the incidence of postoperative complications and the requirement for additional medications or surgery, but also how rapidly vision recovers following surgical intervention. Furthermore, the health and integrity of the postoperative bleb is an important consideration following trabeculectomy or related surgical procedures. The presentation by Dr Kahook highlighted a recent study that focused both on IOP control and on evaluating the recovery of visual acuity, differences in bleb morphology and the number of follow-up visits following EX-PRESS Device implantation compared with traditional trabeculectomy. In a retrospective consecutive case-control series, 70 patients underwent either EX-PRESS Device implantation (n=35) or traditional trabeculectomy (n=35). The mean follow-up time was 28 months. Complete success was defined as IOP ≤18 mmHg and at least a 30 % decrease compared to baseline without the use of

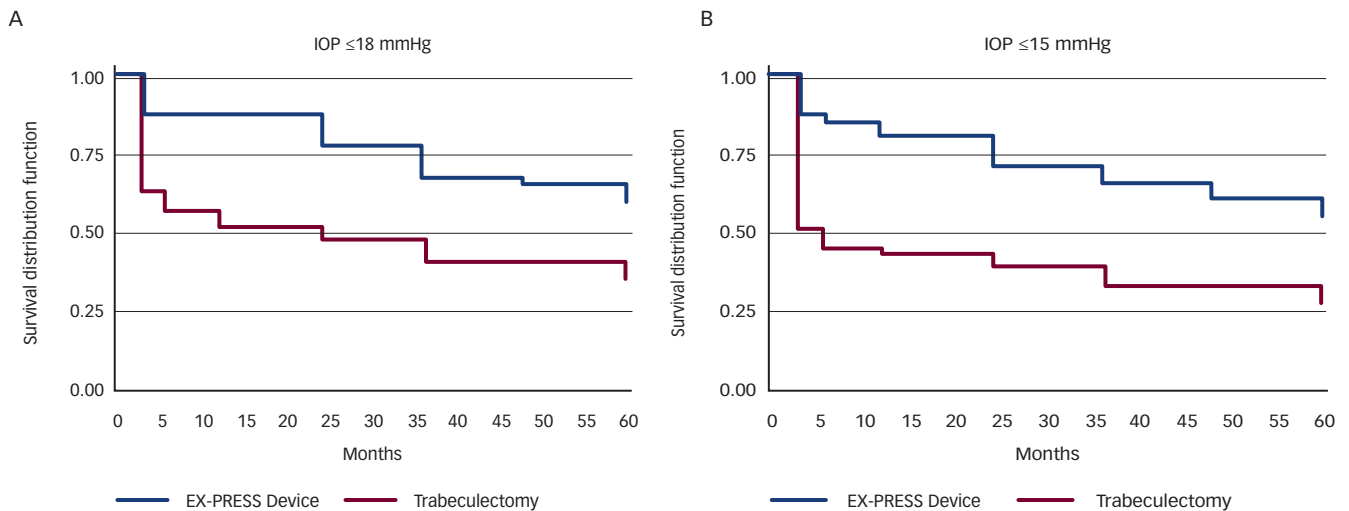
additional IOP-lowering medications. Qualified success was defined as the same as complete success except that the use of medications was included.⁴⁶

The IOP change from baseline to the time of the final follow-up was similar between patients implanted with the EX-PRESS Device and those who underwent traditional trabeculectomy (45.2 and 48.5 %, respectively). Moreover, complete success rates were similar between the two treatment groups (77.1 and 74.3 %, respectively). Qualified success was achieved in a further two (5.71 %) EX-PRESS Device procedures and three (8.57 %) traditional trabeculectomy surgeries at final follow-up (p=0.99). The mean number of postoperative medications per patient was similar in both the EX-PRESS Device and the traditional trabeculectomy groups (0.15 and 0.20, respectively). Rates of complications, including early postoperative hypotony and hyphaema, were lower, but not significantly, in the EX-PRESS Device group (2/35 and 1/35, respectively) than in the trabeculectomy alone group (5/35 and 4/35, respectively).⁴⁶ An equal number of patients in both groups (2/35) required bleb needling postoperatively.

Bleb morphology was graded using the Moorfields Bleb Grading System (www.blebs.net) that evaluates the area, height and vascularity of the bleb. Central and peripheral bleb vascularity and peripheral non-bleb vascularity were reduced in those patients implanted with the EX-PRESS Device compared with those who received trabeculectomy alone during a follow-up period of up to 18 months. For bleb height and bleb area, for the first 12–18 months patients in the EX-PRESS Device group had lower and more diffuse blebs than those in the traditional trabeculectomy group. However, at final follow-up there was no difference in the area, height and vascularity of blebs between the two treatment groups. For the recuperation of visual acuity, the time to recovery of the logarithm of the minimal angle of resolution (logMAR) to preoperative levels was shorter in patients implanted with the EX-PRESS Device than in those patients who underwent traditional trabeculectomy. In the EX-PRESS Device group, logMAR recovered to preoperative levels after one week, whereas in the traditional trabeculectomy group it took one month (see Figure 6). Finally, the mean number of postoperative visits in the first three months of follow-up was significantly lower in those implanted with the EX-PRESS Device (6.1) than in those who underwent traditional trabeculectomy (8.2).⁴⁶

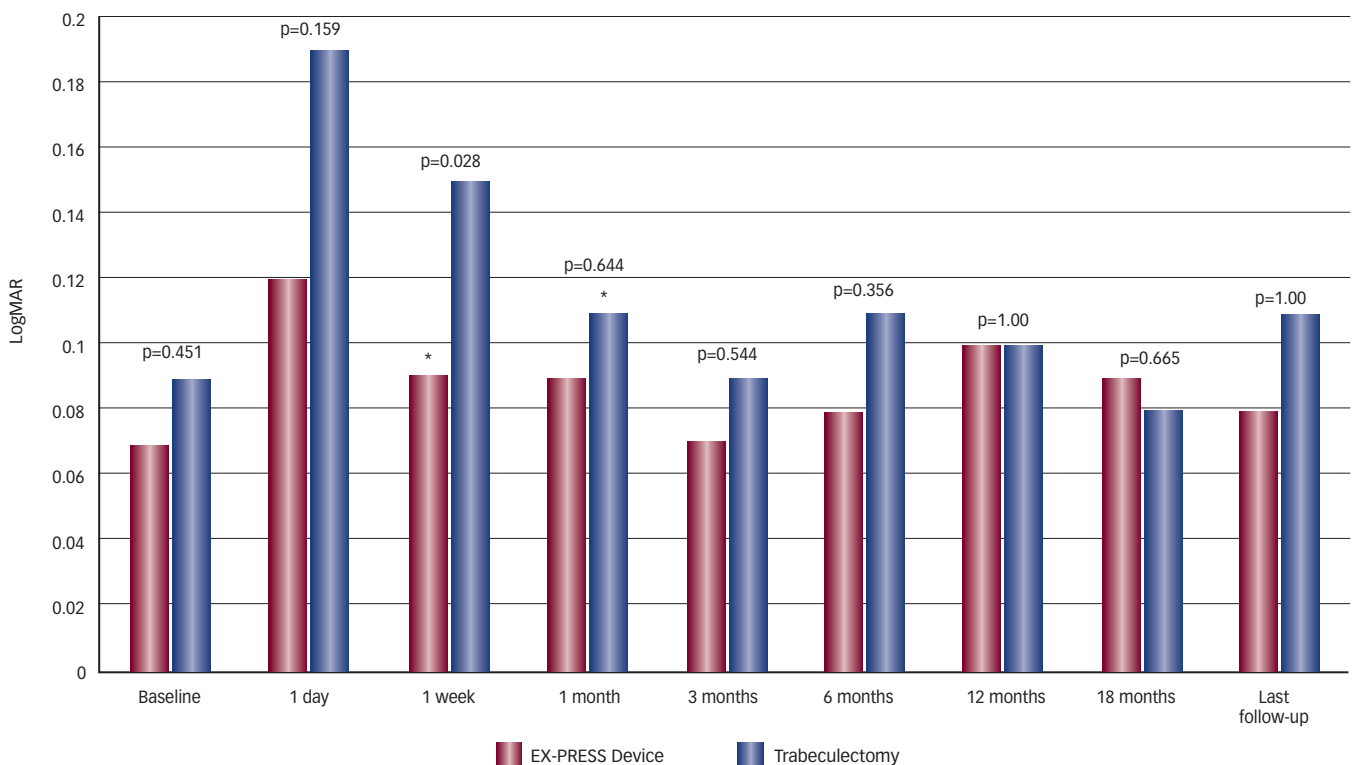
In the final part of his presentation, Dr Kahook discussed an important issue relating to EX-PRESS Device implantation, namely whether the device has significant impacts on patient safety when they undergo magnetic resonance imaging (MRI). Although the EX-PRESS Glaucoma Filtration Device is made from high-grade medical steel considered to be non-ferromagnetic, its compatibility with MRI is largely unknown. Using the American Society for Testing and Materials guidelines for MRI compatibility, Dr Kahook presented recent findings that examined the movement, force and heating of individual EX-PRESS devices in a set of magnetic fields of different strengths.⁴⁷ At MRI strengths of 1.5 and 3.0 tesla (T) there was no rotation, no displacement and minimal angular deflection of the device (see Table 2).⁴⁷ Moreover, there was no apparent translational force or heating. At 4.7 T, there was considerable displacement of the device (which prevented the accurate measurement of rotation), increased angular deflection and a

Figure 5: Kaplan–Meier Survival Curves Comparing EX-PRESS Device Implantation with Traditional Trabeculectomy



A: Survival curves for target intraocular pressure (IOP) ≤18 mmHg; B: Survival curves for target IOP ≤15 mmHg. Adapted from de Jong, et al., 2011.⁴⁵

Figure 6: Comparison of Visual Recovery as Measured by Logarithm of the Minimal Angle of Resolution following EX-PRESS Device Implantation or Traditional Trabeculectomy



The asterisks indicate the point at which logMAR values were not significantly different to those at baseline. LogMAR = Logarithm of the Minimal Angle of Resolution.

greater amount of translational force than those with magnetic fields of 1.5 and 3.0 T. However, even at 4.7 T, there was no heating of the device (see Table 2).⁴⁷

In summary, EX-PRESS Device implantation in Dr Kahook’s patient group is comparable with traditional trabeculectomy in terms of IOP reduction, postoperative complications and the need for additional surgical interventions, but it is associated with quicker visual recovery and more favourable bleb morphology postoperatively. In addition, patients implanted with the EX-PRESS Device require fewer postoperative visits than those that underwent traditional trabeculectomy. In conclusion, Dr

Kahook offered some tips and pearls of wisdom for successful implantation of the EX-PRESS Device which, together with those given by Dr Fechtner and Dr Dahan, provided a perfect lead into the final talk by Dr Moster.

Tips and Pearls for Using the EX-PRESS Glaucoma Filtration Device

Report on a Presentation by Marlene Moster

The presentation by Dr Moster focused on guidance for using the EX-PRESS Device gathered from her own experience in the clinic. Dr Moster began by saying that initially she used the EX-PRESS Device

Table 2: Movement, Force and Temperature Changes of the EX-PRESS Glaucoma Filtration Device in Magnetic Fields of Various Strengths

MRI Strength (tesla)	Rotation (°)	Displacement (mm)	Angular Deflection (°)	Force (dyn)	ΔT (°C)
1.5	0	0	5.0	0.2	+0.1
3.0	0	0	11.0	0.4	0.0
4.7	n/a	>40	40.0	1.8	0.0

MRI = magnetic resonance imaging; n/a = unable to detect; ΔT = change in temperature. Adapted from Seibold, et al., 2011.⁴⁷

almost exclusively in individuals with advanced or complex glaucoma, that is in patients who may already have had multiple surgeries. However, as her experience evolved she began to use the device at earlier stages in a patient’s history, and often as a first resort in those patients refractory to medication or laser trabeculoplasty. Successful use of the EX-PRESS Device is, in part, dependent on patient selection. In agreement with Dr Fechtner and Dr Kahook, an ideal patient should be a candidate for trabeculectomy, preferably pseudophakic with primary open-angle glaucoma, wide-open angles and a deep anterior chamber. Although patients may be refractory to medication and laser trabeculoplasty, ideally they should have clear corneal temporal wounds and no previous conjunctival surgery. In patients whose glaucoma was controlled inadequately following trabeculectomy or deep penetrating surgery, EX-PRESS Device implantation is also a viable option provided there is sufficient room, either temporally or nasally, to insert the device. Moreover, the EX-PRESS Device is an alternative option to implantation of the larger Ahmed, Baerveldt or Molteno drainage devices, which themselves are associated with postoperative complications, including corneal decompensation, tube erosion, migration of the plate or the tube itself, failure of the corneal graft and diplopia. However, Dr Moster emphasised that the EX-PRESS Device is increasingly seen as a first-line surgical treatment for glaucoma even in patients who have not previously undergone trabeculectomy when medical and laser therapy has failed.

For the EX-PRESS Device implantation procedure itself, Dr Moster advocated the use of a ‘blitz’ anaesthesia regime with non-preserved xylocaine 1 % both intracamerally and beneath the conjunctiva–Tenon’s capsule to produce a reservoir of anaesthetic. The conjunctival flap is created in the standard manner with a fornix-based incision, and a half-thickness scleral flap generated. Dr Dahan highlighted the need to create a large scleral flap, perhaps as much as 5 X 5 mm, to enable a large, diffuse postoperative bleb to arise. He also suggested applying appropriate wound-healing techniques to the bed of the scleral flap only rather than over the whole of the sclera. Dr Moster uses a 3 x 3 scleral flap and advocated pre-placing sutures in the scleral flap before breaching the anterior chamber so as not to induce additional astigmatism later on during the operation.

Each member of the symposium faculty stressed the need for a paracentesis, as with traditional trabeculectomy, during EX-PRESS Device implantation in case of intraoperative complications such as shallowing of the anterior chamber, and there was a general consensus on the position beneath the scleral flap for device insertion. The initial perforation should be made in the blue–grey transition zone between the sclera and the clear cornea, using a 25 gauge needle in the first few cases undertaken by the surgeon for greater ease of insertion of the device and, once suitable experience has been gained, moving on to a 26 gauge needle for a tighter device

fit in the sclera. The EX-PRESS Device itself is inserted on its side and then rotated clockwise into the final position before being released from the delivery system (see Figure 3). Dr Kahook stressed the importance of holding the delivery system in the correct position before inserting the EX-PRESS Device. Ensuring one’s finger is in the correct position over the release button so that it can be depressed fully without having to look away from the microscope reduces the risk of incorrect device insertion. For suturing of the scleral flap, Dr Moster emphasised that releasable sutures are the most appropriate so that aqueous flow can be controlled tightly, either during the operation itself or postoperatively at the slit lamp; however, laserable sutures can work as well. The conjunctival flap should be sutured watertight to prevent any wound leak, of particular importance when using appropriate wound-healing techniques. Postoperatively, Dr Kahook underlined the importance of treating patients who have undergone EX-PRESS Device implantation no differently to patients who have undergone traditional trabeculectomy. Wound healing must be monitored carefully, as must evidence of fibrosis around the scleral flap or conjunctival incision.

Dr Moster then concluded her talk with three individual case studies. In the first, the patient presented with an IOP of 28 mmHg and -11 D of myopia. The decision was made to implant an EX-PRESS Device to prevent hypotony maculopathy. In this instance, the predictable aqueous outflow from the EX-PRESS Device combined with the use of releasable sutures enabled the precise titration of IOP to a final, stable value of approximately 15 mmHg. In the second case, the patient presented with a sinking intraocular lens (IOL) and IOP of 40 mmHg with pseudoexfoliation. Having performed minimally invasive surgery to suture the IOL haptic to the sclera and prevent further sinking, the patient still presented with excessively high IOP. Here, the EX-PRESS Device was used instead of a traditional trabeculectomy to prevent further surgical interference with the eye and to reduce the incidence of postoperative complications. Using the tips and pearls of wisdom outlined above, IOP was well controlled at the desired level. In her final case study, Dr Moster highlighted the need to remain flexible during the intraoperative period. The patient was undergoing an EX-PRESS Device implantation, but having created the scleral flap a thin section of sclera beneath the flap was apparent close to the desired implantation site. Just prior to device insertion the patient sneezed, which caused the thin section of the scleral bed to rupture and the iris to prolapse. As a result, the EX-PRESS Device implantation had to be abandoned and the operation was continued as a standard trabeculectomy. Use of the EX-PRESS Device therefore provides a great deal of comfort for the operating surgeon, as it enables the right decisions to be made at the right times.

Conclusions

The EX-PRESS Glaucoma Filtration Device is a valuable addition to the glaucoma surgeon’s armamentarium, because it makes one step of the trabeculectomy procedure (aqueous outflow) more predictable. Both retrospective and prospective trials indicate that the EX-PRESS Device controls IOP levels as well as, and in some cases better than, traditional trabeculectomy, and is associated with fewer postoperative complications. In some studies, eyes that were implanted with the EX-PRESS Device required fewer additional IOP-lowering medications and fewer postoperative surgical interventions. In some studies, complete success rates were higher and the time-to-treatment failure longer with the EX-PRESS Device than those of standard trabeculectomy. Whereas the use of the EX-PRESS Device was

once primarily for patients with advanced or complex glaucoma, it is used increasingly at earlier stages of the disease and is a viable first-line treatment. The EX-PRESS Device is MRI-compatible, and implantation can be combined successfully with more complex surgical procedures, for instance cataract phacoemulsification,⁴² or

in instances where previous surgical intervention has failed.⁴³ The EX-PRESS Glaucoma Filtration Device is an advance over traditional trabeculectomy. It can be used by any ophthalmic surgeon skilled in trabeculectomy and provides an additional option for the management of glaucoma. ■ EXP11652JS

- Collaborative Normal-Tension Glaucoma Study Group, The effectiveness of intraocular pressure reduction in the treatment of normal-tension glaucoma, *Am J Ophthalmol*, 1998;126:498–505.
- The AGIS Investigators, The Advanced Glaucoma Intervention Study (AGIS): 7, The relationship between control of intraocular pressure and visual field deterioration, *Am J Ophthalmol*, 2000;130:429–40.
- Leske MC, Heijl A, Hussein M, et al., Factors for glaucoma progression and the effect of treatment. The Early Manifest Glaucoma Trial, *Arch Ophthalmol*, 2003;121:48–56.
- Sommer A, Tielsch JM, Katz J, et al., Relationship between intraocular pressure and primary open angle glaucoma among white and black Americans, *Arch Ophthalmol*, 1991;109:1090–5.
- Wesselink C, Marcus MW, Jansoni NM, Risk factors for visual field progression in the Groningen Longitudinal Glaucoma Study: a comparison of different statistical approaches, 2011;doi:10.1097/IJG.0b013e31822543e0.
- Quigley HA, Glaucoma, *Lancet*, 2011;377:1367–77.
- Foster A, Resnikoff S, The impact of Vision 2020 on global blindness, *Eye*, 2005;19:1133–5.
- Resnikoff S, Pascolini D, Etya'ale D, et al., Global data on visual impairment in the year 2002, *Bull World Health Organ*, 2004;82:844–51.
- Leske MC, Open-angle glaucoma – an epidemiologic overview, *Ophthalmic Epidemiol*, 2007;14:166–72.
- Rudnicka AR, Mt-Isa S, Owen CG, et al., Variations in primary open-angle glaucoma prevalence by age, gender, and race: a Bayesian meta-analysis, *Invest Ophthalmol Vis Sci*, 2006;47:4254–61.
- Quigley HA, Broman AT, The number of people with glaucoma worldwide in 2010 and 2020, *Br J Ophthalmol*, 2006;90:262–7.
- Poulsen PB, Buchholz P, Walt JG, et al., Cost analysis of glaucoma-related blindness in Europe, *Int Congr Ser*, 2005;1282:262–6.
- Traverso CE, Walt JG, Kelly SP, et al., Direct costs of glaucoma and severity of the disease: a multinational long term study of resource utilisation in Europe, *Br J Ophthalmol*, 2005;89:1245–9.
- Heijl A, Leske MC, Bengtsson B, et al., Reduction of intraocular pressure and glaucoma progression. Results from the Early Manifest Glaucoma Trial, *Arch Ophthalmol*, 2002;120:1268–79.
- Lichter PR, Musch DC, Gillespie BW, et al., Interim clinical outcomes in The Collaborative Initial Glaucoma Treatment Study comparing initial treatment randomized to medications of surgery, *Ophthalmology*, 2001;108:1943–53.
- Edmunds B, Thompson JR, Salmon JF, et al., The National Survey of Trabeculectomy. III. Early and late complications, *Eye*, 2002;16:297–303.
- Sharaawy T, Bhartiya S, Surgical management of glaucoma: evolving paradigms, *Indian J Ophthalmol*, 2011;59(Suppl. 1):S123–30.
- Mantravadi AV, Myers JS, Reconsidering trabeculectomy's strengths and weaknesses, *Clin Experiment Ophthalmol*, 2010;38:827–8.
- Edmunds B, Thompson JR, Salmon JF, et al., The National Survey of Trabeculectomy. II. Variations in operative technique and outcome, *Eye*, 2001;15:441–8.
- Gedde SJ, Schiffman JC, Feuer WJ, et al., Treatment outcomes in the Tube Versus Trabeculectomy Study after one year of follow-up, *Am J Ophthalmol*, 2007;143:9–22.
- Ehrnrooth P, Lehto I, Puska P, et al., Long-term outcome of trabeculectomy in terms of intraocular pressure, *Acta Ophthalmol Scand*, 2002;80:267–71.
- Diestelhorst M, Khalili MA, Kriegelstein GK, Trabeculectomy: a retrospective follow-up of 700 eyes, *Int Ophthalmol*, 1999;22:211–20.
- Beckers HUM, Kinders KC, Webers CAB, Five-year results of trabeculectomy with mitomycin C, *Graefes Arch Clin Exp Ophthalmol*, 2003;241:106–10.
- Bindlish R, Condon GP, Schlosser JD, et al., Efficacy and safety of mitomycin-C in primary trabeculectomy, *Ophthalmology*, 2002;109:1336–42.
- Bevin TH, Molteno ACB, Herbison P, Otago Glaucoma Surgery Outcome Study: long-term results of 841 trabeculectomies, *Clin Experiment Ophthalmol*, 2008;36:731–7.
- Molteno ACB, Bosma NJ, Kittelson JM, Otago Glaucoma Surgery Outcome Study. Long-term results of trabeculectomy – 1976 to 1995, *Ophthalmology*, 1999;106:1742–50.
- Crowston JG, Long-term outcomes of trabeculectomy, *Clin Experiment Ophthalmol*, 2008;36:705–6.
- Rotchford AP, King AJ, Moving the goal posts. Definitions of success after glaucoma surgery and their effect on reported outcome, *Ophthalmology*, 2010;117:18–23.
- Patel S, Pasquale LR, Glaucoma drainage devices: a review of the past, present, and future, *Semin Ophthalmol*, 2010;25:265–70.
- DeBry PW, Perkins TW, Heatley G, et al., Incidence of late-onset bleb-related complications following trabeculectomy with mitomycin, *Arch Ophthalmol*, 2002;120:297–300.
- Jones E, Clarke J, Khaw PT, Recent advances in trabeculectomy technique, *Curr Opin Ophthalmol*, 2005;16:107–13.
- Papadopoulos A, Khaw PT, Improving glaucoma filtering surgery, *Eye*, 2001;15:131–2.
- Gale J, Wells AP, Medium-term outcomes of safe surgery system trabeculectomies, *Br J Ophthalmol*, 2008;92:1232–5.
- Stalmans I, Gillis A, Lafaut A-S, et al., Safe trabeculectomy technique: long term outcome, *Br J Ophthalmol*, 2008;90:44–7.
- Salim S, Ex-PRESS glaucoma filtration device – surgical technique and outcomes, *Int Ophthalmol Clin*, 2011;51:83–94.
- Nyska A, Glovinsky Y, Belkin M, et al., Biocompatibility of the Ex-PRESS miniature glaucoma drainage implant, *J Glaucoma*, 2003;12:275–80.
- Stewart RM, Diamond JG, Ashmore ED, et al., Complications following Ex-PRESS glaucoma shunt implantation, *Am J Ophthalmol*, 2005;140:340–1.
- Traverso CE, De Feo F, Messas-Kaplan A, et al., Long term effect on IOP of a stainless steel glaucoma drainage implant (Ex-PRESS) in combined surgery with phacoemulsification, *Br J Ophthalmol*, 2005;89:425–9.
- Wamsley S, Moster MR, Rai S, et al., Results of the use of the Ex-PRESS miniature glaucoma implant in technically challenging, advanced glaucoma cases: a clinical pilot study, *Am J Ophthalmol*, 2004;138:1049–51.
- Dahan E, Carmichael TR, Implantation of a miniature glaucoma device under a scleral flap, *J Glaucoma*, 2005;14:98–102.
- Maris JPIG, Ishida K, Netland PA, Comparison of trabeculectomy with Ex-PRESS miniature glaucoma device implanted under scleral flap, *J Glaucoma*, 2007;16:14–9.
- Kanner EM, Netland PA, Sarkisian Jr SR, et al., Ex-PRESS miniature glaucoma device implanted under a scleral flap alone or combined with phacoemulsification cataract surgery, *J Glaucoma*, 2009;18:488–91.
- Lankaranian D, Razeghinejad MR, Prasad A, et al., Intermediate-term results of the Ex-PRESS miniature glaucoma implant under a scleral flap in previously operated eyes, *Clin Experiment Ophthalmol*, 2011;39:421–8.
- De Jong LAMS, The Ex-PRESS glaucoma shunt versus trabeculectomy in open-angle glaucoma: a prospective randomized study, *Adv Ther*, 2009;26:336–45.
- De Jong L, Lafuma A, Aguade A-S, et al., Five-year extension of a clinical trial comparing the Ex-PRESS glaucoma filtration device and trabeculectomy in primary open-angle glaucoma, *Clin Ophthalmol*, 2011;5:527–33.
- Good TJ, Kahook MY, Assessment of bleb morphologic features and postoperative outcomes after Ex-PRESS drainage device implantation versus trabeculectomy, *Am J Ophthalmol*, 2011;151:507–13.
- Seibold LK, Rorrer RAL, Kahook MY, MRI of the Ex-PRESS stainless steel glaucoma drainage device, *Br J Ophthalmol*, 2011;95:251–4.

