

Comparing Visco canalostomy with Trabeculectomy

Roberto G Carassa, MD

Director, Italian Glaucoma Center

Abstract

Visco canalostomy is a non-penetrating procedure aimed at increasing the outflow facility by creating significant morphologic changes at the trabecular meshwork level. It is an effective procedure in lowering intraocular pressure (IOP) in open-angle glaucomatous eyes. Compared with trabeculectomy, meta-analysis studies have shown that final IOPs are significantly higher. Nevertheless, visco canalostomy is a safer technique with significantly fewer complications compared with trabeculectomy. Visco canalostomy is therefore a better option in eyes where target IOPs are in the mid-high teens, or in eyes at high risk of complications with trabeculectomy.

Keywords

Glaucoma surgery, visco canalostomy, non-penetrating surgery, trabeculectomy, Schlemm's canal surgery

Disclosure: The author has no conflicts of interest to declare.

Received: August 12, 2011 **Accepted:** August 31, 2011 **Citation:** *US Ophthalmic Review*, 2011;4(2):88-91 DOI: 10.17925/USOR.2011.04.02.88

Correspondence: Roberto G Carassa, MD, Italian Glaucoma Center, Piazza Repubblica, 1, 20124 Milan, Italy. E: carassa@glaucoma.it

In recent years, non-penetrating glaucoma surgery has been seen as a safer alternative to trabeculectomy. This class of procedures is mainly represented by 'deep sclerectomy', 'visco canalostomy,' and 'canaloplasty' (a recent and more reproducible variation of visco canalostomy). The aim of all these procedures is to allow drainage of the aqueous humor from the anterior chamber, not through a patent scleral opening but by slow percolation through the inner trabecular meshwork and/or Descemet's membrane ('sclerodescemet membrane'). This avoids sudden drops in intraocular pressure (IOP), hypotony, and flat chambers. The absence of anterior chamber opening and iridectomy limits the risk of cataract and infection. The advantages of visco canalostomy and canaloplasty are that not only are they non-penetrating, like deep sclerectomy, but also, most importantly, they restore the physiologic outflow pathway, thus avoiding external filtration in the majority of eyes. This makes the success of the procedure partly independent of conjunctival or episcleral scarring, a leading cause of failure in trabeculectomy, with fewer indications for wound healing modulation. Moreover, the absence of an elevated filtering bleb avoids related ocular discomfort, and the procedures can be carried out in any quadrant.

Operative Technique

Visco canalostomy is a demanding surgical technique that requires a long learning curve.¹ First, a fornix-based conjunctival flap is created. Then, a 5 x 5 mm outer parabolic flap, approximately 200 µm thick, is dissected, followed by an inner concentrically 4 x 4 mm scleral flap sculpted beneath the previous one (see *Figure 1*). The internal flap should be dissected deep enough to have a dark reflex from the underlying choroid. While the cut is advanced anteriorly, Schlemm's canal is de-roofed. The two ostia of Schlemm's canal are then cannulated with the specific 190 µm cannula and Schlemm's canal is dilated by slow and repeated injections of

high-molecular-weight sodium hyaluronate (see *Figure 2*). During canaloplasty, dilation of Schlemm's canal is made by catheterization of the entire canal length with a microcatheter and by controlled release of high-molecular-weight sodium hyaluronate inside the whole canal. A 10-0 polypropylene suture is then passed inside the canal and, through a suture loop, tightened to distend the trabecular meshwork inward placing the tissue in tension (see *Figure 3*).

By gently pulling the inner scleral flap upwards and delicately depressing the floor of the canal and Descemet's membrane with the tip of a cotton swab, the membrane itself is then cleaved from the cornea and the cleavage is advanced in clear cornea for approximately 1 mm, thus creating the so-called 'trabeculo-descemet window' (see *Figure 4*). As soon as the window is completed, the inner scleral flap is excised. The next step is the sealing of the lake, which is obtained by tightly suturing the outer scleral flap with seven 10-0 nylon stitches. High-molecular-weight sodium hyaluronate is then injected underneath the flap to fill the intrascleral space temporarily, preventing it from collapsing and scarring in the early post-operative period. Finally, the conjunctiva is sutured in place.

Mechanism of Action

Visco canalostomy increases the aqueous outflow through different paths. Injection of viscoelastic into the canal not only dilates the canal and associated collectors but also disrupts the internal and external walls of Schlemm's canal and adjacent trabecular layers, thus increasing the trabecular outflow facility and making the procedure act as a 'micro-trabeculotomy' (see *Figure 5*).² Aqueous outflow facility is also increased by damage to the inner wall of Schlemm's canal and adjacent trabeculum at the site of surgery, thus enhancing aqueous

outflow into the scleral lake. From here, aqueous can leave the eye via three different paths:

- through the cut ends and previously nonfunctional sectors of Schlemm's canal to collector channels;
- by external filtration into the subconjunctival space; or
- by absorption into the subchoroidal space.

External filtration and filtering blebs are uncommon in visco canalostomy and can only be detected by biomicroscopy or by ultrasound biomicroscopy in up to one-third of eyes.³ A supraciliary hypoechoic area, suggesting aqueous drainage into the subchoroidal space, has been shown by the use of ultrasound biomicroscopy (see *Figure 6*).⁴ In eyes with elevated IOP after surgery, a small opening of the trabeculo-descemetic membrane can be made using a neodymium-doped yttrium aluminum garnet (Nd:YAG) laser. This procedure, named 'laser goniopuncture,' enhances the external filtration, thereby changing the basic mechanism of action of visco canalostomy, and is indicated in eyes where Schlemm's canal dilation was insufficient to increase the trabecular outflow facility significantly. The rate of laser goniopuncture varies among visco canalostomy studies from 4⁵ to 33 %.⁶ In a larger study on canaloplasty (a procedure with well-controlled Schlemm's canal dilation), the need for goniopuncture was only 4.7 %.⁷

Results

Visco canalostomy is an effective procedure for lowering IOP with a good safety profile. It has few complications, an easy post-operative management and induces significantly less eye discomfort than trabeculectomy, as would be expected considering the absence of the filtering bleb in the majority of cases.

Compared with trabeculectomy, even if many of the studies fail to find significant differences between the procedures, the final IOPs seem to be higher after visco canalostomy. Unlike after trabeculectomy (which generally results in IOPs in the low-teens), IOPs after visco canalostomy are in the normal range (i.e. in the mid-high teens). This can be explained by the mechanism of action of visco canalostomy, which is based on increased outflow facility through the trabecular meshwork.

A direct comparison between different studies aimed at comparing visco canalostomy with trabeculectomy is difficult because criteria for success, length of follow-up and techniques are different. Many papers also deal with combined visco canalostomy and cataract surgery.

Jonescu-Cuipers et al. in 2001,⁸ at six months showed a complete success rate (IOP <20 mmHg) of 0 % after visco canalostomy and 50 % after trabeculectomy on 20 eyes. In 2002, the same research group⁹ performed a study on 60 patients and found that one year after visco canalostomy or trabeculectomy was performed, 30 % of the visco canalostomy patients showed an IOP of <22 mmHg without medication compared with 56.7 % of the trabeculectomy patients. Visco canalostomy showed significantly fewer complications compared with trabeculectomy.

O'Bart et al.¹⁰ showed a one-year success rate (IOP ≤21 mmHg on no medication) of 100 % after trabeculectomy with antimetabolites and 64 % after visco canalostomy. Not all the visco canalostomies were performed

Figure 1: Dissection of the Internal Flap

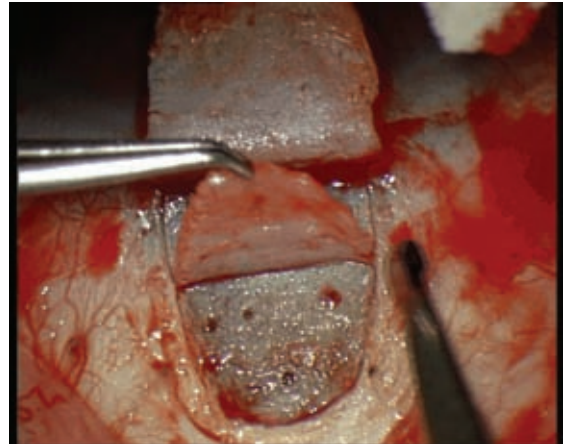
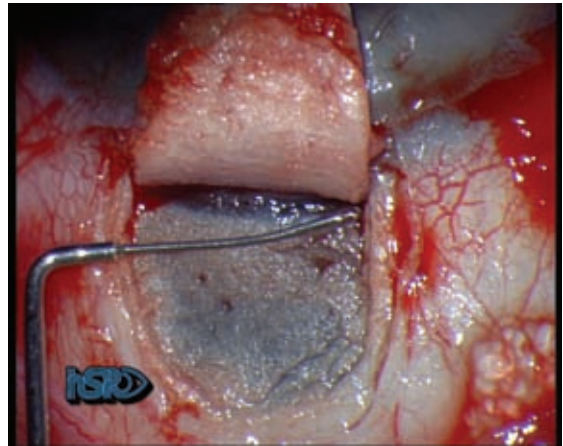


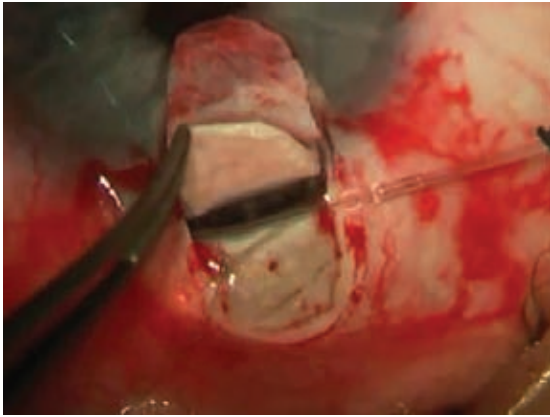
Figure 2: Incannulation of Schlemm's Canal and Injection with High Molecular Weight Sodium Hyaluronate



using the standard protocol because Schlemm's canal was dilated using viscoelastic in only half of the cases. In a 24-month randomized controlled trial comparing visco canalostomy with trabeculectomy, Carassa et al.⁵ reported similar final IOP levels of 16.3 ± 5.1 mmHg after visco canalostomy and 14.0 ± 4.6 mmHg after trabeculectomy. Also, no significant difference was found between the two procedures with IOP targets of ≤21 mmHg (76 versus 80 %) or <16 mmHg (56 versus 72 %) with no medication. The trabeculectomy group had more complications, required a significantly greater number of post-operative visits with greater additional interventions (as needlings or 5-fluorouracil injections). At 12 months, patients who underwent visco canalostomy reported less eye discomfort compared with patients who underwent trabeculectomy.

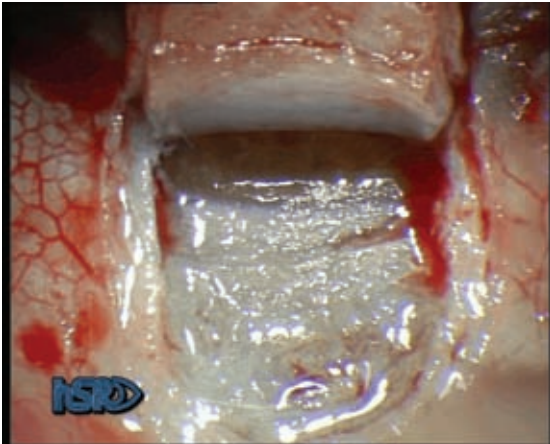
A study by Yalvac et al.¹¹ on 50 eyes followed for 36 months found similar results. At three years, the mean IOP was 17.8 ± 4.6 mmHg in the visco canalostomy group and 16.0 mmHg ± 7.07 in the trabeculectomy group ($p=0.694$). Complete success (IOP 6 to 21 mmHg without medication) was achieved in 35.3 % after visco canalostomy and 55.1 % after trabeculectomy ($p>0.05$). Post-operative hypotony and cataract formation occurred more frequently in the trabeculectomy group than in the visco canalostomy group ($p=0.002$).

Figure 3: Canaloplasty



The microcatheter is inserted in Schlemm's canal and a 10-0 polypropylene suture is fixed to the catheter to be passed inside the canal.

Figure 4: Sclerodescemet Membrane with Aqueous Percolation



O'Brart et al.¹² in a 20-month randomized controlled trial comparing viscocanalostomy with trabeculectomy with adjunctive use of antimetabolites on 50 eyes, found a significantly lower complete success rate (IOP ≤ 21 mmHg) after viscocanalostomy (34 %) than after trabeculectomy (68 %). Early transient complications such as anterior chamber shallowing and encysted blebs were more common in the trabeculectomy group ($p < 0.05$). Late post-operative cataract formation was similar between the two groups.

These findings were not confirmed by Yarangumeli et al.,¹³ who were unable to detect significant differences between viscocanalostomy and trabeculectomy on the two fellow eyes of 22 patients. After a mean follow-up of 18 months, complete success (IOP ≤ 18 mmHg) without medication was found in 64 % of the trabeculectomy group and in 59 % of the viscocanalostomy group. No significant differences were found for complications. Trabeculectomy eyes had a borderline significant increase in cataract progression compared with viscocanalostomy eyes.

Kobayashi et al.¹⁴ performed a study on 25 patients to compare viscocanalostomy with mitomycin-C trabeculectomy. At 12 months, IOP was controlled more effectively after trabeculectomy than after

viscocanalostomy (12.6 ± 4.3 versus 17.1 ± 1.5 mmHg, respectively, $p < 0.0001$). An IOP ≤ 20 mmHg without medication was achieved in 88 % of the eyes after trabeculectomy and in 64 % of the eyes after viscocanalostomy ($p = 0.02$). Nevertheless, this study also confirmed the better safety profile of viscocanalostomy given that after trabeculectomy 16 % of the eyes had shallow anterior chambers and 20 % had hypotony.

In a four-year follow-up prospective study, Gilmour et al.¹⁵ confirmed better results after trabeculectomy than after viscocanalostomy and a significantly higher success rate: an IOP < 18 mmHg with no medication was achieved in 42 % of the eyes after trabeculectomy and in 21 % after viscocanalostomy ($p = 0.018$).

To date, only one randomized controlled trial¹⁶ has been performed with the aim of comparing non-penetrating glaucoma surgery (in 19 eyes), including viscocanalostomy (11 eyes), with trabeculectomy (11 eyes) for refractive changes. Post-operative IOP levels and visual acuity (logMar values) did not differ among groups. Average induced astigmatism was lower in the non-penetrating surgery group than in the trabeculectomy group and showed a less against-the-rule shift over six months.

A retrospective study¹⁷ has compared phaco-viscocanalostomy with phaco-trabeculectomy. At three years, phaco-viscocanalostomy showed a higher success rate (IOP < 21 mmHg with no medication) than phaco-trabeculectomy, 58.2 versus 36.0 %, and a lower incidence of vision-threatening complications. A more recent prospective randomized comparison¹⁸ showed no significant differences between the two procedures with regard to IOP control and success rate; however, there were fewer complications associated with phaco-viscocanalostomy.

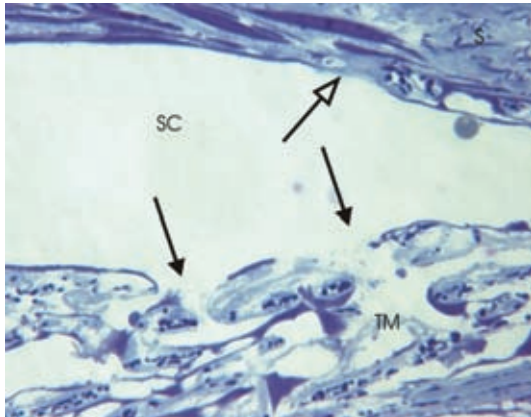
To try to achieve more conclusive results, three articles have reported the meta-analysis of studies that compared viscocanalostomy with trabeculectomy. The first two papers by Cheng et al.^{19,20} showed that trabeculectomy had a better efficacy with a risk difference for complete success of -0.16 (95 % confidence interval [CI]: -0.30 to -0.02), a mean IOP reduction at two years of 45.6 % for trabeculectomy and 30.2 % for viscocanalostomy, and a complete success rate at four years of 47.6 and 22.7 %, respectively. The two studies confirmed fewer complications after viscocanalostomy than after trabeculectomy. Chai et al.²¹ confirmed these results: they showed that trabeculectomy had a greater pressure-lowering effect but a higher complication rate.

Only one retrospective study has compared canaloplasty with trabeculectomy with 12 months of follow-up.²² Canaloplasty was highly effective in reducing IOP with a final IOP of 13.3 ± 3.6 mmHg and a mean percentage decrease of pressure from baseline of 32 ± 22 %. Trabeculectomy achieved significantly better results with a final IOP of 11.3 ± 4.1 ($p = 0.05$) and a mean percentage decrease of pressure from baseline of 43 ± 28 % ($p = 0.072$). An IOP > 18 or < 4 mmHg was found in 12.1 % of eyes after canaloplasty and in 4.3 % after trabeculectomy. Trabeculectomy was nevertheless affected by a significantly greater number of complications.

Indications

Based on the results of studies reported in the literature, it is possible to define major indications and contraindications for viscocanalostomy.

Figure 5: Trabecular Meshwork of a Visco canalostomy-treated Monkey Eye

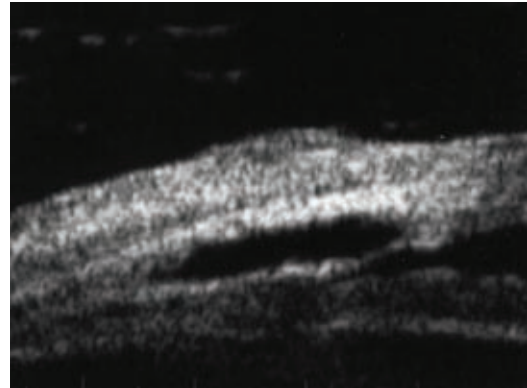


Visco canalostomy was performed about 4 mm from the 12-o'clock limbus two months earlier. Larger defects, about 1 to 5 μm long, are present in the inner and outer wall of Schlemm's canal (SC). Source: Tamm et al., 2004.²

Given that the major changes are made at the trabecular meshwork level, the procedure cannot be effective when the angle is closed or neovascularized, or when Schlemm's canal is likely to be damaged. This is the case in previously operated eyes where an extensive cautery of the perilimbal area has been made. However, eyes with hypertension or glaucoma owing to trabecular meshwork impairment should respond the best to visco canalostomy. This has been shown, for example, in glaucomas secondary to uveitis (with well-controlled inflammation),²³ in juvenile glaucomas²⁴ and in congenital glaucomas.²⁵

Owing to its final IOP levels, the procedure is indicated in primary open-angle glaucoma when target IOP is not very low (as indicated by the guidelines for glaucoma produced by the European Glaucoma Society²⁶ and by the Consensus Series book by the Association of International Glaucoma Societies²⁷). The advantage of the absence

Figure 6: Ultrasound Biomicroscopy Image Showing the Intrascleral Lake and the Intact Sclerodescemetic Membrane



of (or very reduced) external filtration make the technique safe and particularly indicated in eyes with chronic blepharitis, in contact lens wearers, or when the surgery has to be performed in the lateral or inferior quadrants.

Summary and Key Points

Visco canalostomy is an effective surgery for lowering IOP in glaucomatous eyes. It has several advantages over trabeculectomy, such as a lower rate of complications, fewer incidences of cataracts, less risk of infection-related side effects, fewer refractive changes, significantly less eye discomfort and easy post-operative management with fewer visits and fewer additional interventions. When considering final IOPs between 16 and 21 mmHg, the rate of failure over time is similar between the two procedures; however, with trabeculectomy there is a greater chance of achieving lower IOPs. Visco canalostomy is nevertheless technically demanding, it requires a long learning curve and is a longer procedure than trabeculectomy. ■

- Stegmann R, Pienaar A, Miller D. Visco canalostomy for open-angle glaucoma in black African patients, *J Cataract Refract Surg*, 1999;25:316–22.
- Tamm ER, Carassa RG, Albert DM, et al., Visco canalostomy in Rhesus monkeys, *Arch Ophthalmol*, 2004;122:1826–38.
- Carassa R, Bettin P, Fiori M, Brancato R, Visco canalostomy: a pilot study, *Eur J Ophthalmol*, 1998;8:57–61.
- Negri-Aranguren I, Croxatto O, Grigera DE, Midterm ultrasound biomicroscopy findings in eyes with successful visco canalostomy, *J Cataract Refract Surg*, 2002;28:752–7.
- Carassa RG, Bettin P, Fiori M, Brancato R, Visco canalostomy versus trabeculectomy in white adults affected by open-angle glaucoma: a 2-year randomized, controlled trial, *Ophthalmology*, 2003;110:882–7.
- Alp MN, Yarangumeli A, Koz OG, Kural G, Nd:YAG laser goniotomy in visco canalostomy: penetration in non-penetrating glaucoma surgery, *Int Ophthalmol*, 2010;30:245–52.
- Lewis RA, von Wolff K, Tetz M, et al., Canaloplasty: circumferential viscodilation and tensioning of Schlemm canal using flexible microcatheter for the treatment of open-angle glaucoma in adults. Two-year interim clinical study results, *J Cataract Refract Surg*, 2009;35:814–24.
- Jonescu-Cuyper C, Jacobi P, Konen W, Kriegelstein G, Primary visco canalostomy versus trabeculectomy in white patients with open-angle glaucoma: a randomized clinical trial, *Ophthalmology*, 2001;108:254–8.
- Luke C, Dietlein TS, Jacobi PC, et al., A prospective randomized trial of visco canalostomy versus trabeculectomy in open-angle glaucoma: a 1-year follow-up study, *J Glaucoma*, 2002;11:294–9.
- O'Brart DSP, Rowlands E, Islam N, Noury AMS, A randomised, prospective study comparing trabeculectomy augmented with antimetabolites with a visco canalostomy technique for the management of open angle glaucoma uncontrolled by medical therapy, *Br J Ophthalmol*, 2002;86:748–54.
- Yalvac IS, Sahin M, Eksioğlu U, et al., Primary visco canalostomy versus trabeculectomy for primary open-angle glaucoma: three-year prospective randomized clinical trial, *J Cataract Refract Surg*, 2004;30:2050–7.
- O'Brart DP, Shiew M, Edmunds B, A randomised, prospective study comparing trabeculectomy with visco canalostomy with adjunctive antimetabolite usage for the management of open angle glaucoma uncontrolled by medical therapy, *Br J Ophthalmol*, 2004;88:1012–7.
- Yarangumeli A, Gureser S, Koz OG, et al., Visco canalostomy versus trabeculectomy in patients with bilateral high-tension glaucoma, *Int Ophthalmol*, 2004;25:207–13.
- Kobayashi H, Kobayashi K, Okinami S, A comparison of the intraocular pressure-lowering effect and safety of visco canalostomy and trabeculectomy with mitomycin C in bilateral open-angle glaucoma, *Graefes Arch Clin Exp Ophthalmol*, 2003;241:359–66.
- Gilmour DF, Manners TD, Devenport H, et al., Visco canalostomy versus trabeculectomy for primary open angle glaucoma: 4-year prospective randomized clinical trial, *Eye (Lond)*, 2009;23:1802–7.
- Egrilmez S, Ates H, Nalcaci S, et al., Surgically induced corneal refractive change following glaucoma surgery: nonpenetrating trabeculectomy versus trabeculectomy, *J Cat Refract Surg*, 2004;30:1232–9.
- Park M, Hayashi K, Takahashi H, et al., Phaco-visco canalostomy versus phaco-trabeculectomy: a middle-term study, *J Glaucoma*, 2006;15:456–61.
- Kobayashi H, Kobayashi K, Randomized comparison of the intraocular pressure-lowering effect of phaco-visco canalostomy and phacotrabeculectomy, *Ophthalmology*, 2007;114:909–14.
- Cheng JW, Xi GL, Wei RL, et al., Efficacy and tolerability of nonpenetrating filtering surgery in the treatment of open-angle glaucoma: a meta-analysis, *Ophthalmologica*, 2010;224:138–46.
- Cheng JW, Cheng SW, Cai JP, et al., Systematic overview of nonpenetrating glaucoma surgery in the treatment of open angle glaucoma, *Med Sci Monit*, 2011;17:155–63.
- Chai C, Loon SC, Meta-analysis of visco canalostomy versus trabeculectomy in uncontrolled glaucoma, *J Glaucoma*, 2010;19:519–27.
- Ayyala RS, Chaudhry AL, Okogbaa CB, Zurakowski D, Comparison of surgical outcomes between canaloplasty and trabeculectomy at 12 months follow-up, *Ophthalmology*, 2011;[Epub ahead of print].
- Miserocchi E, Carassa RG, Bettin P, Brancato R, Visco canalostomy in patients with uveitis: a preliminary report, *J Cataract Refract Surg*, 2004;30:566–70.
- Stangos AN, Whatham AR, Sunaric-Megevand G, primary visco canalostomy for juvenile open-angle glaucoma, *Am J Ophthalmol*, 2005;140:490–6.
- Noureddin BN, El-Haibi CP, Cheikha A, Bashhsur ZF, Visco canalostomy versus trabeculectomy ab externo in primary congenital glaucoma: 1-year follow-up of a prospective controlled pilot study, *Br J Ophthalmol*, 2006;90:1281–5.
- European Glaucoma Society, *Terminology and Guidelines for Glaucoma*, second edition, Savona: Dogma, 2003.
- Carassa RG, Goldberg I, Non penetrating glaucoma drainage surgery. In: Weinreb RN, Crowston JG (eds), *Glaucoma Surgery. Open Angle Glaucoma*, The Hague: Kugler, 2005;91–106.