

## Sub-1 Millimeter—700 Micron Cataract Surgery

Dhivya Ashok Kumar, MD<sup>1</sup> and Amar Agarwal, MS, FRCS, FRCOphth<sup>2</sup>

1. Doctor; 2. Professor, Dr Agarwal's Eye Hospital and Eye Research Centre, Chennai

### Abstract

We have reviewed the surgical technique, advantages, and limitations of sub-1 mm–700 micron cataract surgery or 'microphakonit.' The small clear corneal incision is made with the 0.8 mm microphakonit knife and the instruments, such as the phacoemulsification needle, irrigating chopper, and bimanual irrigation aspiration set, are made with a 0.7 mm diameter. We have also reviewed some of the work done by the authors in 700 micron cataract surgery and our analysis of microphakonit wound architecture has been explained. The clear corneal wound architecture in microphakonit has been evaluated with anterior segment optical coherence tomography and the healing process has been assessed. The microphakonit has proven to have early wound healing and less post-operative astigmatism as compared with the wound with extension.

### Keywords

Microphakonit, MICS, 700 micron cataract surgery, air pump, gas-forced infusion, sub-1 mm cataract surgery

**Disclosure:** The authors have no conflicts of interest to declare.

**Received:** July 20, 2011 **Accepted:** August 28, 2011 **Citation:** *US Ophthalmic Review*, 2011;4(2):92–6 DOI: 10.17925/USOR.2011.04.02.92

**Correspondence:** Amar Agarwal, MS, FRCS, FRCOphth, Dr Agarwal's Eye Hospital and Eye Research Centre, 19 Cathedral Road, Chennai 600086, India. E: dragarwal@vsnl.com

The current objective or goal in cataract surgery is to achieve the preferred visual outcome with minimal trauma to the cornea. The advances in phacoemulsification techniques and phaco machines, along with the invention of foldable intraocular lenses (IOLs), made clear corneal incisions of less than 3 mm size possible.<sup>1–13</sup> The main advantages of the smaller incisions are early wound healing and less post-operative astigmatism. The smallest cataract incisions reported till now are performed in the technique 'microphakonit.' In this article we have reviewed the technique, instrumentation, advantages, and limitations of microphakonit.

### History and Nomenclature

The sub-1 mm–700 micron cataract surgery or microphakonit technique was introduced by the author (AA) in 2005. This technique was termed microphakonit so as to differentiate the method from 0.9 mm phakonit which was introduced by the author (AA) in 1998. The name was coined as microphakonit as the incision was smaller than in phakonit, which is called phakonit because phaco was carried out using a needle (N), through an incision (I), and with the tip (T) of the phaco needle (needle incision technology) (NIT).

In 1999, Crozafon reported<sup>14</sup> the successful use of a sleeveless 21-gauge Teflon®-coated tip for minimally invasive bimanual phaco. Crozafon felt that thermal burn could be prevented by coating the phaco tip with Teflon, which has poor thermal conductivity.

In 1999, Hiroshi Tsuneoka from Japan<sup>7,8</sup> studied the use of ultrasonic phacoemulsification and aspiration for lens extraction through a microincision of 1.4 mm. Tsuneoka used a larger incision as he felt that

when the incision size is larger than the phaco tip, the tip gets cooled by the leakage of infusion solution through the incision. The extra space, according to him, also prevents deformation at the incision site due to tip movement.

Jorge Alio from Spain<sup>15</sup> coined the term microincision cataract surgery (MICS). This meant cataract surgery being performed through an incision of 1.5 mm or less. In 2001, Randall Olson<sup>16</sup> from the US reported the feasibility of sleeveless phaco through a 1.0 mm incision using the Sovereign® (AMO, US) with WhiteStar™ technology. Olson found that tip heating could be minimized by setting the machine to pulse mode so that ultrasound was generated for extremely short intervals. He coined the term 'Microphaco.'

### Surgical Technique

A side-port incision is made and an ophthalmic viscosurgical device is injected from this port. The main and side-port incisions are made with a 0.8 mm microphakonit knife. A 5–6 mm capsulorhexis is performed with the 26-gauge needle bent to form a cystotome. A 25-gauge rhexis forceps (MST) may also be used. In the non-dominant hand, a globe stabilization rod can be used to control the eye movement.

Cortical cleaving hydrodissection is performed and the fluid wave passing under the nucleus should be checked, as well as checking for rotation of the nucleus. One can perform hydrodissection from both incisions so that even the subincisional areas can get easily hydrodissected. The dissection can be carried out in multiple points so that the cleavage is as complete as in any phacoemulsification. It is of note, however, that because there is little escape of fluid, one

**Table 1: Fluid Exiting from Various Irrigating Choppers with and without Gas-forced Infusion (Values in ml/minute)**

Irrigating Chopper	Without Gas-forced Infusion	With Gas-forced Infusion Using the ACCURUS® Machine at 50 mmHg	With Gas-forced Infusion Using the ACCURUS Machine at 75 mmHg	With Gas-forced Infusion Using the ACCURUS Machine at 100 mmHg	Air Pump with Regulator at Low	Air Pump with Regulator at High
0.9 mm side opening	25	36	42	48	37	51
0.9 mm end opening	34	51	57	65	52	68
0.7 mm end opening	27	39	44	51	41	54

should be careful during hydrodissection. If too much fluid is passed into the eye, a complication such as a posterior capsular rent may occur and therefore it is necessary to decompress the anterior chamber during this maneuver by applying slight posterior pressure on the scleral lip while performing hydromaneuvers. The 22-gauge (0.7 mm) irrigating chopper (MicroSurgical Technology, Redmond, WA) is connected to the infusion line of the phaco machine and introduced with the foot pedal on position 1. The phaco probe is connected to the aspiration line and the 0.7 mm phaco tip (without an infusion sleeve) is introduced through the clear corneal incision. Using the phaco tip and moderate ultrasound power, the center of the nucleus is directly embedded starting from the superior edge of the rhexis, with the phaco probe directed obliquely downward toward the vitreous. The settings at this stage are: phaco power 30–50 %; aspiration flow rate 20 cm<sup>3</sup>/min; and vacuum 100–200 mmHg. The setting is usually for grade 1 and 2 nuclear sclerosis cataract. However, for denser cataracts, phaco power can be increased. Using the karate-chop technique (see *Figure 1A*), the nucleus is chopped and removed. Cortical wash-up is then accomplished using the bimanual I/A (0.7 mm set) technique see *Figure 1B*). During this whole procedure, gas-forced infusion is used.

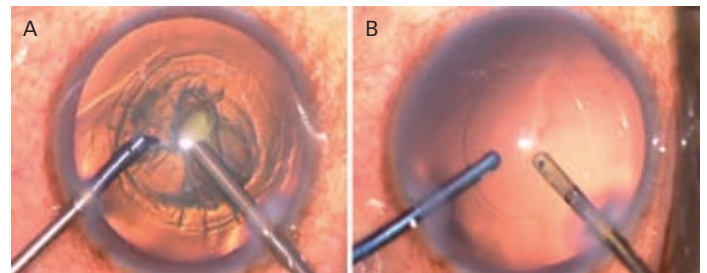
### Gas-forced Infusion

One of the limitations in bimanual MICS is the destabilization of the anterior chamber during surgery. This has been overcome by the introduction of gas-forced infusion by Dr Sunita Agarwal.<sup>17</sup> Gas-forced infusion (see *Figure 2*)<sup>17,18</sup> pushes more fluid into the eye through the irrigating chopper and also prevents surge. Thus we are able to use a 20/21-gauge irrigating chopper as well as solving the problem of destabilization of the anterior chamber during surgery. Now, with a 22-gauge (0.7 mm) irrigating chopper, it is essential that gas-forced infusion be used in the surgery. This is also called external gas-forced infusion.

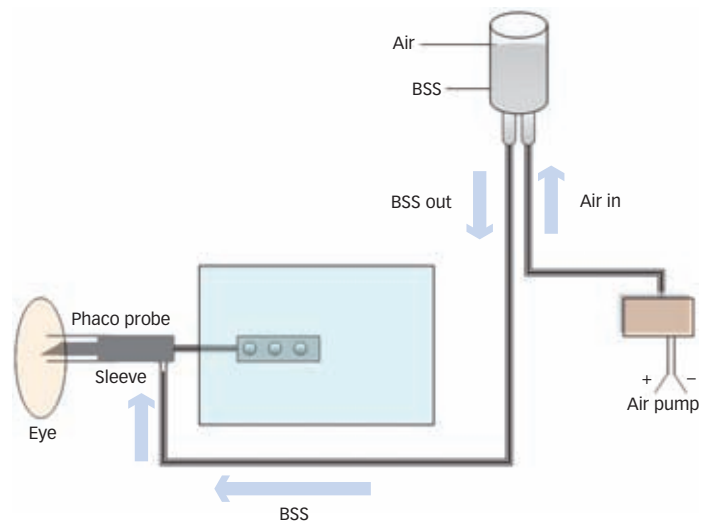
When the surgeon uses the air pump contained in the same phaco machine, it is called internal gas-forced infusion (IFI). To solve the problem of infection we use a millipore filter connected to the machine. The Stellaris machine (Bausch and Lomb) has an in-built air pump to give pressurized infusion. When we are using a 0.7 mm irrigating chopper the problem is that the amount of fluid entering the eye is not enough. To solve this problem gas-forced infusion is a must. We preset the infusion pump at 100 mmHg when we are performing microphakinit.

### Instrumentation

The microphakinit chopper is a 0.7 mm open-end irrigating chopper and the bimanual irrigation/aspiration handpiece is also designed for the 0.7 mm diameter small incision of microphakinit. Both the microphakinit

**Figure 1: Microphakinit—Phacoemulsification with 700 micron instruments (A) and Bimanual Irrigation and Aspiration (B)**

*Microphakinit performed with 700 micron phaco needle and 700 micron irrigating chopper (MicroSurgical Technology, US) (A) and bimanual irrigation aspiration performed with 700 micron bimanual I/A Set (MicroSurgical Technology, US) (B).*

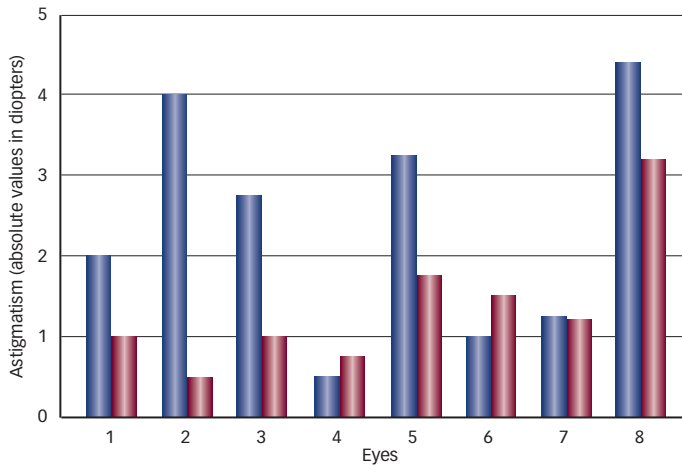
**Figure 2: Schematic Diagram of Gas-forced Infusion**

*BSS = balanced salt solution.*

needle tip and microphakinit irrigating chopper can fit onto the handles of the Duet system (MicroSurgical Technology, Redmond, WA).

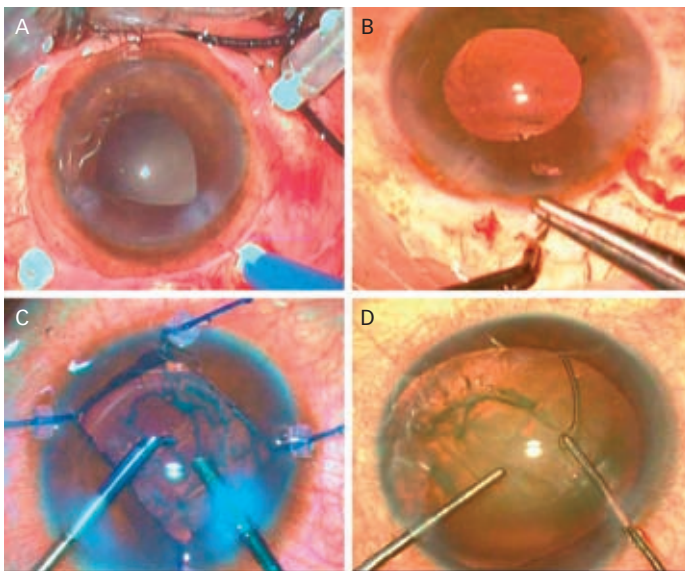
An anticipated problem with the 0.7 mm microphakinit needle, compared with the 0.9 mm phakonit needle, is a decrease in the speed of surgery due to a decrease in the aspiration flow rate. This has

**Figure 3: Bar Diagram Showing the Post-operative Astigmatism in Eyes with Microphakoni Surgery**



No significant change observed ( $p=0.069$ ).

**Figure 4: Combined Procedures with Microphakoni**



A: 25-gauge pars plana transconjunctival vitrectomy; B: Trabeculectomy; C: Iris-retracting hooks; D: Endocapsular ring.

been tackled by designing a tip (Larry Laks, MST, US) with thinner walls, resulting in a relative increase in the inner diameter of the tip. This allowed the speed of surgery to increase. When the authors decided for a 0.7 mm irrigating chopper they had to opt for an end-opening irrigating chopper. This is because, as the bore of the irrigating chopper is smaller, the amount of fluid coming out of it would be less and so an end-opening chopper would maintain the fluidics better. With gas-forced infusion the amount of fluid entering and exiting from the anterior chamber would be balanced. The amount of fluid coming out of the various irrigating choppers with and without an air pump has been measured (see Table 1). Bimanual irrigation aspiration is carried out with the bimanual irrigation aspiration instruments (Microsurgical Technology, Redmond, WA).

## Intraocular Lens Implantation

The IOL is implanted by extending the wound incision with keratome, since there are no sub-1 mm IOLs so far available that can pass through 0.7 mm incisions. The ThinOptX® (Thinoptx, Abingdon, VA) modified ultrathin rollable IOL can be implanted with minimal wound extension. However, for other foldable IOLs an extension of more than 2 mm is carried out. We used acrylic foldable IOLs of larger size; hence we had to enlarge the incision to 2 mm. However, for newer MICS, IOL wounds can be extended to 1.8 mm.

## Corneal Topography

MICS continues to gain more attention because it leads to less post-operative induced astigmatism compared with conventional phacoemulsification. Post-operative corneal astigmatism in eyes which had undergone microphakoni were analyzed. Orbscan® (Bausch and Lomb, US) was used for topography estimation. In a small prospective topographic analysis of microphakoni eyes, eight eyes of eight patients were evaluated. The nuclear sclerosis was grade 2 in all the operated eyes. There was no wound extension in these eyes. Pre- and post-operative changes analyzed with Orbscan in eyes with 700 micron cataract surgery (see Table 1) were observed to have no significant (Wilcoxon signed-rank test  $p=0.069$ ) post-operative changes (see Figure 3).

## Combined Surgeries

Microphakoni can be combined with pars plana vitrectomy, 25-gauge sutureless vitrectomy (see Figure 4A), and trabeculectomy (see Figure 4B). The combination of 700 micron cataract surgery with 'no anesthesia' can be performed. It can be combined with iris-retracting hooks (see Figure 4C) in eyes with small pupils or with endocapsular ring implantation (see Figure 4D) in eyes with subluxated cataract.

## Wound Architecture

Microphakoni is the smallest incision so far introduced for cataract removal. It has got its own advantages which are as follows:

### Faster Wound Healing

The wound healing<sup>17</sup> seemed to be faster in microphakoni without extension (see Figure 5A), as 82.3 % of the eyes had no endothelial gape on day 3 and 100 % on day 7, as compared with 57.1 % on day three and 57.1 % on day seven in 2.8 mm extended wounds.

### No Difference in Healing in Main or Side Port

On comparing the main port with the side-port incision in the immediate post-operative period in the five microphakoni eyes without IOL implantation, no significant difference in the wound morphology, namely coaptation loss ( $p=0.374$ ) and endothelial misalignment ( $p=0.146$ ), was seen between the wounds with and without phaco needle.<sup>19</sup>

### Early Tight Closure at the Incision Site

One of the advantages that were seen with microphakoni was that there was tight closure at the incision site in the immediate post-operative period (see Figure 5) as compared with the incisions in which an extension was made. Tight closure was assessed by the Seidel test for wound leak.

### Less Fluid Ingress and Infection

Tight closure at the incision site in the immediate post-operative period decreases the chance of ingress of fluid and organisms from the ocular surface into the anterior chamber and would in turn decrease the chances of endophthalmitis.

### Self-sealed/No Sutures

The incisions in microphakonit were also self-sealed, without any suture, and no external wound gaping as early as day 1 which was seen as a well-formed tunnel in optical coherence tomography. Moreover, the incisions used for microphakonit<sup>4-6</sup> are so small and self-sealing that the chance of their opening as a result of lid or ocular movements is negligible.

### Lesser Post-operative Leak and Shallow Anterior Chamber

Microphakonit wounds have lesser post-operative leak and shallow anterior chamber, and thereby less incidence of post-operative infection, by their property of early wound apposition and healing.

### No Change in Intraocular Pressure

There was no significant difference between the mean intraocular pressure of the eyes with and without endothelial misalignment or coaptation loss.<sup>19</sup>

### Less Topographic Change

Agarwal et al. have studied the wound morphology in MICS and have shown early wound closure.<sup>19</sup> Pre- and post-operative changes were analyzed with Orbscan topography in those eyes with 700 micron cataract surgery without extension and it has been observed that there were no significant post-operative changes.

### Cost-effectiveness

Cost-effectiveness here implies the economic analysis of relative costs and practical outcomes after cataract surgery. Though we have not analyzed the cost-utility and cost-effectiveness of microphakonit per se, we would like to do this in future. Only with the invention of injectable or microincision IOLs can the original benefit of these techniques be obtained.

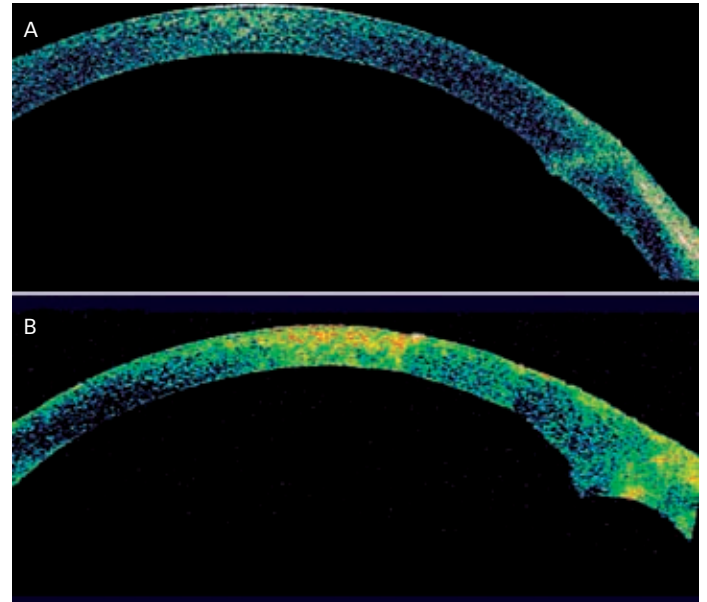
### Learning Curve

Microphakonit has only a short learning curve. In our experience of training phacoemulsification surgeons, this technique is easily accepted and learned in a short period.

### Limitations

Though there is evidence of post-cataract endophthalmitis in clear corneal incisions, as of now there are no studies comparing the incidence

**Figure 5: High-resolution Cross-sectional Image of Wound in the Anterior Segment Optical Coherence Tomography on Day One**



A: Microphakonit without extension; B: Microphakonit with 2.8 mm extension.

of endophthalmitis between smaller (sub-1 mm) and larger clear corneal incisions. With the appropriate use of aseptic methods, including careful draping, proper selection of anesthesia including the no-anesthesia technique, and pre-operative, intra-operative and post-operative chemoprophylaxis, along with the selection of the optimum clear corneal wound design and construction, the risks of post-operative infection should be low. The absence of IOLs which can go through sub-1 mm incisions acts as a limitation. Nevertheless, with the growing technology and future availability of IOLs that can go through such small incisions, microphakonit can become an option for the ophthalmic surgeon and a benefit for the patient.

### Conclusions

The recent focus on improving techniques in cataract surgery has been in reducing incision size and improving visual outcome. Smaller incisions result in less induced astigmatism, faster visual rehabilitation, and improved wound healing. Even though there are many reports analyzing post-operative induced astigmatism, there is no study comparing the sub-1 mm incisions with conventional phacoemulsification. Future studies evaluating the topographic and wavefront changes in sub-1 mm clear corneal incisions are required. With the only limitation being the absence of sub-1 mm IOLs, the full clinical advantages of these microincisions are yet to be realized. ■

1. Agarwal A, Agarwal A, Agarwal S, et al., Phakonit: phacoemulsification through a 0.9 mm incision, *J Cataract Refract Surg*, 2001;27:1548–52.
2. Pandey S, Werner L, Agarwal A, et al., Phakonit: Cataract removal through a sub 1.0 mm incision with implantation of the Thinoptx rollable IOL, *J Cataract Refract Surg*, 2002;28:1710–3.
3. Agarwal A, Agarwal S, Agarwal A, Phakonit with an acricite IOL, *J Cataract Refract Surg*, 2003;29:854–5.
4. Agarwal A, Trivedi RH, Jacob S, et al., Microphakonit: 700 micron cataract surgery, *Clin Ophthalmol*, 2007;1(3):323–5.
5. Agarwal A, Jacob S, Sinha S, et al., Combating endophthalmitis with microphakonit and no-anesthesia technique, *J Cataract Refract Surg*, 2007;33(12):2009–11.
6. Agarwal A, Jacob S, Agarwal A, Combined microphakonit and 25-gauge transconjunctival sutureless vitrectomy, *J Cataract Refract Surg*, 2007;33(11):1839–40.
7. Tsuneoka H, Shiba T, Takahashi Y, Feasibility of ultrasound cataract surgery with a 1.4 mm incision, *J Cataract Refract Surg*, 2001;27:934–40.
8. Tsuneoka H, Shiba T, Takahashi Y, Ultrasonic phacoemulsification using a 1.4 mm incision (clinical results), *J Cataract Refract Surg*, 2002;28:81–6.
9. Alio J, Rodriguez-Prats JL, Galal A, et al., Outcomes of microincision cataract surgery versus coaxial phacoemulsification, *Ophthalmology*, 2005;112(11):1997–2003.
10. Dossou AA, Cottet L, Burqener ND, et al., Outcomes of coaxial microincision cataract surgery versus conventional coaxial

- cataract surgery, *J Cataract Refract Surg*, 2008;34(2):284–8.
11. Agarwal A, Agarwal S, Agarwal A, Phakonit: A new technique of removing cataracts through a 0.9 mm incision. In: Agarwal A, Agarwal S, Agarwal A (eds), *Phacoemulsification, Laser cataract surgery and foldable IOLs*, 1st edition, New Delhi: Jaypee, 1998;139–43.
  12. Agarwal A, Agarwal S, Agarwal A, Phakonit and laser phakonit: Lens surgery through a 0.9 mm incision. In: Agarwal A, Agarwal S, Agarwal A (eds) *Phacoemulsification, Laser cataract surgery and foldable IOLs*, 2nd edition, New Delhi: Jaypee, 2000;204–16.
  13. Agarwal A, Trivedi R, Jacob S, et al., Microphakonit:700 micron cataract surgery, *Clin Ophthalmol*, 2007;1(3):323–5.
  14. Hiroshi Tsuneoka, Ultrasmall incision bimanual phaco surgery and foldable IOL. In: Agarwal S, Agarwal A, Agarwal A, *Phacoemulsification*, Third edition, New Delhi: Jaypee Publishers, 2004;337–47.
  15. Alio JL, What does MICS require? The transition to microincisional surgery. In: Alio JL, Rodriguez Prats JL, Galal A (eds), *MICS: Micro-incision Cataract Surgery*, Republic of Panama: Highlights of Ophthalmology International, 2004;1–4.
  16. Soscia W, Howard JG, Olson RJ, Microphacoemulsification with WhiteStar. A wound-temperature study, *J Cataract Refract Surg*, 2002;28(6):1044–6.
  17. Agarwal A, Agarwal S, Agarwal A, Antichamber collapse, *J Cataract Refract Surg*, 2002;28:1085–6.
  18. Chaudhry P, Prakash G, Jacob S, et al., Safety and efficacy of gas-forced infusion (air pump) in coaxial phacoemulsification, *J Cataract Refract Surg*, 2010;36(12):2139–45.
  19. Agarwal A, Kumar DA, Jacob S, Agarwal A, *In vivo* analysis of wound architecture in 700 microm microphakonit cataract surgery, *J Cataract Refract Surg*, 2008;34(9):1554–60.