

Age-related Macular Degeneration—Review and Current Concepts

Rajeev K Seth, MD,¹ Eric J Sigler, MD² and Ron A Adelman, MD, MPH, FACS³

1. Assistant Professor of Ophthalmology, and Director of Retina Service, Department of Ophthalmology, University of Arizona College of Medicine; 2. Chief Resident;

3. Associate Professor of Ophthalmology and Director of Retina Center, Department of Ophthalmology and Visual Science, Yale University School of Medicine

Abstract

Age-related macular degeneration (ARMD) continues to be a significant public health concern, given its high prevalence and potential blinding prognosis in the elderly. Several risk factors have been identified in the development of ARMD, including age, race, and family history. The pathogenesis of ARMD continues to be elucidated, and recent research has focused on genetic factors. ARMD presents in either the atrophic or exudative form. Treatment for atrophic disease consists of antioxidants and zinc and close monitoring. Treatment for exudative disease is aimed at targeting choroidal neovascularization. The development of anti-vascular endothelial growth factor (anti-VEGF) agents has revolutionized the treatment of exudative ARMD, providing a more favorable prognosis for previously blinding disease. Considerable amount of research is being carried out on new treatment modalities for both the atrophic and exudative forms of the disease.

Keywords

Age-related macular degeneration (ARMD), choroidal neovascularization, Bevacizumab, Ranibizumab, vascular endothelial growth factor (VEGF)

Disclosure: The authors have no conflicts of interest to declare.

Acknowledgments: Funding and support in part by Leir Foundation, Newman's Own Foundation, Connecticut Lions Eye Research Foundation, and Research to Prevent Blindness.

Received: January 17, 2011 **Accepted:** March 1, 2011 **Citation:** *US Ophthalmic Review*, 2011;4(1):96–100 DOI: 10.17925/USOR.2011.04.01.96

Correspondence: Ron A Adelman, MD, MPH, FACS, Department of Ophthalmology and Visual Science, 40 Temple St, 3rd Floor, New Haven, CT 06510. E: ron.adelman@yale.edu

Age-related macular degeneration (ARMD) is a highly prevalent, severely visually disabling disease affecting millions of people worldwide. As its name implies, the disorder affects the macula and therefore central vision, thereby causing significant disability and immeasurable personal impact not only to the patient, but also the family and loved ones caring for those afflicted.

There are two major forms of the disease: atrophic or 'dry' macular degeneration and exudative or 'wet' ARMD. These are distinguished by the presence in the latter of the proliferation of abnormal new blood vessels, or formation of a choroidal neovascular membrane. The vast majority of patients with ARMD have the atrophic form, commonly presenting with drusen and retinal pigment epithelial (RPE) atrophic changes of the central macula. Although the atrophic form of the disease is much more prevalent, the largest numbers of patients that develop severe visual loss have the exudative form of ARMD.

While the precise cause of the disease remains elusive, many risk factors have been identified that contribute to the complex interaction of genetic and environmental influences that underlie the pathogenesis. More recently, genetic predisposing factors have been investigated and several candidate genes and molecular culprits have been identified.

Many treatment modalities have been employed to halt the progression of macular degeneration. Management for the atrophic form of the disease is aimed at prevention, risk reduction, education, and

recognition of more advanced disease. One early treatment modality for exudative ARMD consisted of thermal laser application to choroidal neovascular membranes. While these occasionally resulted in good anatomical results, the visual results were often poor. To the delight of many practitioners and patients, progress has been made over the past decade. Research on drugs capable of stopping abnormal new blood vessel growth led to the development of anti-vascular endothelial growth factors (anti-VEGFs), which are highly successful in halting the progression of both the disease process and visual loss associated with exudative macular degeneration. Furthermore, a large body of research is currently under way to develop new diagnostic and treatment modalities.

Epidemiology

ARMD is the major cause of severe central visual loss in the US in people over 60 years of age.^{1,2} Overall, the disease appears to be much more common in Caucasians. It is estimated that there are between 15 and 20 million Americans living with at least the earliest signs of ARMD, affecting approximately 18% of Americans between 65 and 74 years of age.³ This figure varies worldwide with lower prevalence in the Asian and African continents. More than eight million people in the US have bilateral intermediate or unilateral advanced disease,⁴ with approximately 1.75 million Americans having advanced disease.⁵

Although legal blindness rarely occurs before the seventh or eighth decade of life, over 200 cases per million per year will result in legal

blindness, with between 60 and 80% of these cases arising from neovascular ARMD.¹⁻³ The overall prevalence of either neovascular AMD or geographic atrophy in people over 40 in the US is about 1.5%, while the overall prevalence of one or more large drusen is 6.12%.¹ As the elderly population in the US is expected to dramatically increase over the next two decades, the number of people affected by ARMD is predicted to rise as well.

Impact on Society

ARMD proves to be a major public health concern, not only because of its current and predicted increased prevalence, but also because of the disabling impact it has on those suffering vision loss as a result of advanced ARMD. ARMD has a dramatic impact on the elderly in terms of daily living and overall quality of life.^{6,7} Not only are visual impairments associated with difficulty with activities of daily living, but also with increased risk of depression and accidental injury.^{8,9} In addition, significant occupational impairment may result from even mild visual impairment. Furthermore, elderly patients with blinding disease have higher likelihood of multiple sensory impairments.^{10,11}

Risk Factors

Risk factors for development of ARMD include advancing age, hyperopia, light skin pigmentation, family history, smoking, female gender, hypertension, hypercholesterolemia, and cardiovascular disease.¹²⁻¹⁹

Pathogenesis and Clinical Manifestations

The pathogenic basis of ARMD is diverse and complex, depending on the stage of disease.²⁰⁻²² A massive body of research has been undertaken in order to elucidate the genetic and environmental interplay that leads to the development of various stages and phenotypic variations of the disease.

The atrophic form of the disease is characterized by macular RPE alterations, the accumulation of lipofuscin and drusen, retinal pigment epithelial atrophy, and degeneration of segments of the choriocapillaris.^{23,24} Perhaps the earliest sign of the development of ARMD is the presence of macular drusen, or lipid-rich material with various amounts of collagen fibrils that accumulate at the level of the sub-RPE and Bruch's membrane²⁵ (see *Figure 1*).

Pigment changes early in the disease consist of more focal areas of RPE hyperpigmentation and areas of non-contiguous, mottled depigmentation. Histologically, this represents atrophic areas of RPE overlying drusen deposits.²⁶ As atrophic macular degeneration progresses, extensive areas of RPE and retinal atrophy ensue leading to the late stage known as geographic atrophy. This stage is characterized ultrastructurally by RPE loss and damaged photoreceptors in association with abnormal distribution of opsins in degenerating cells,²⁷ with overlying thinning of the neurosensory retina.²⁸ Segments of the choriocapillaris underlying the degenerating RPE become atrophic as well.

Drusen are classified by size, with small drusen considered to be <64µm, intermediate drusen 64–124µm, and large drusen >125µm.²⁴ Larger drusen may give rise to areas of RPE detachment, sometimes referred to as a drusenoid pigment epithelial detachment (PED). Larger-

Figure 1: Fundus Photograph of the Left Eye of a Patient with Dry Age-related Macular Degeneration with Large Drusen and Non-central Geographic Atrophy

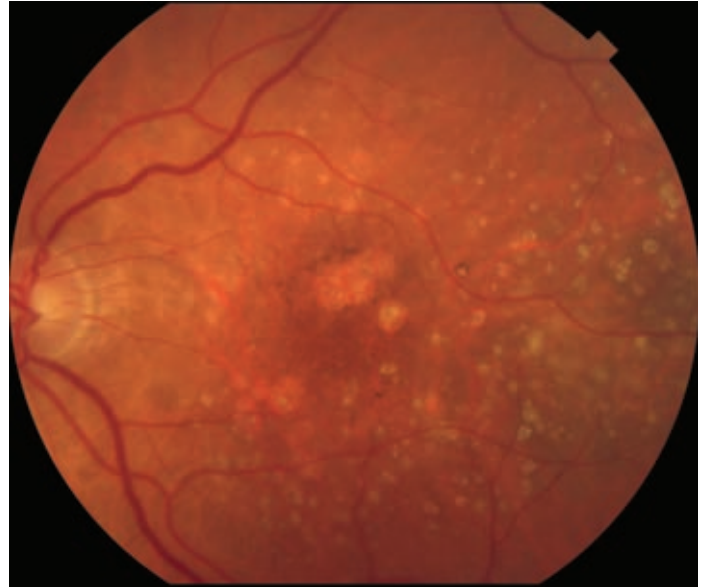
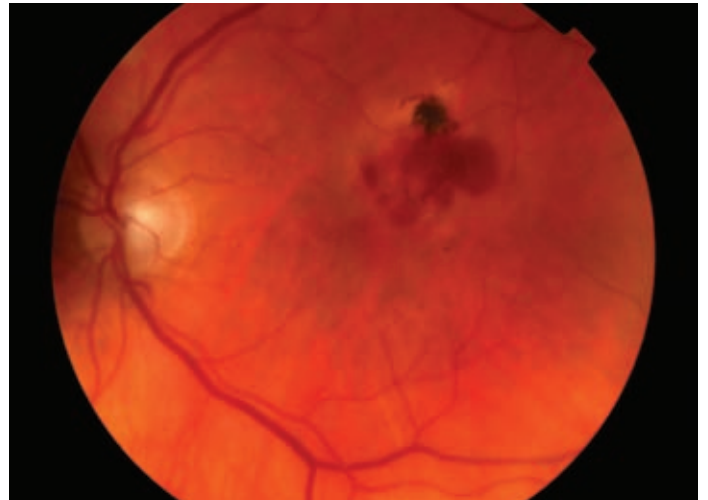


Figure 2: Fundus Photograph of the Left Eye of a Patient with Exudative Age-related Macular Degeneration

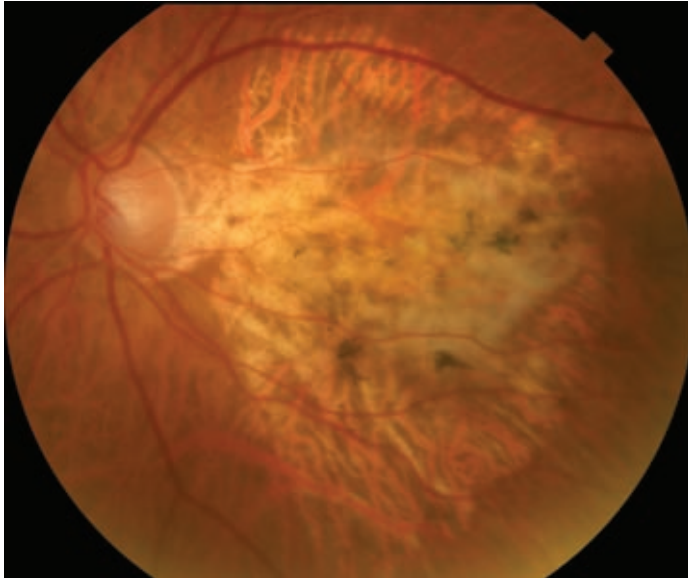


Note subretinal hemorrhage below an area of retinal pigment epithelium clumping.

sized drusen, larger number of drusen, confluence of drusen, and presence of soft drusen have been noted to be associated with more advanced atrophic as well as exudative forms of ARMD.^{2,29} Clinically, patients with less-severe atrophic macular degeneration most often have few symptoms. However, with the presence of central geographic atrophy, patients can have severe vision loss and central scotoma (blind spot).

Exudative (or wet) macular degeneration is characterized by formation of choroidal neovascular membrane, which occurs when fibrovascular tissue begins to grow from the choroid through Bruch's membrane, thereby destroying the architecture of the overlying RPE and outer

Figure 3: Fundus Photograph of the Left Eye of a Patient with End-stage Age-related Macular Degeneration



Evidenced by a central subretinal fibrosis known as a disciform scar.

retina. Patients present with variable degrees of metamorphopsia (perception of straight lines appearing wavy), decline in visual acuity, or scotoma. Clinically, examination reveals presence of intra-retinal or subretinal fluid; hemorrhage at any layer (pre-, intra-, or subretinal or sub-RPE); RPE detachment; and/or presence of lipid (see *Figure 2*). The end-result of untreated neovascularization is fibrotic scar formation, known as a disciform scar, with permanent central vision loss (see *Figure 3*). Fluorescein angiography, indocyanine green angiography, and optical coherence tomography (OCT) imaging are used to aid in the diagnosis of exudative ARMD.

The specific cascade of events that leads to this wet form of ARMD is complex and continues to be completely elucidated.³⁰ It is thought that focal defects in Bruch's membrane and oxidative stress may contribute to the pathophysiologic development of choroidal neovascularization. Furthermore, upregulation of pro-angiogenic factors such as VEGF and platelet-derived growth factor (PDGF) or the downregulation of anti-angiogenic factors such as pigment epithelial-derived growth factor (PEDF) or endostatin are known to play a major role in the process, and now serve as possible therapeutic targets in the management of exudative ARMD.^{31,32} Thus, the major event seems to be a disruption in the balance of pro-angiogenic and anti-angiogenic factors. The initiating event in this process remains elusive and is likely diverse. Many soluble factors such as VEGF, hypoxia-inducible factor (HIF), fibroblast growth factor (FGF), PDGF, insulin-like growth factor (IGF) and many others have been shown to have pro-angiogenic properties.³⁰⁻³³ Additionally, there is recent evidence showing that drusen or their components may have some pro-angiogenic effects.³⁴

Genetic Factors

Recently, genetic factors have been investigated, and several candidate susceptibility polymorphisms have been identified. An association with variation in fibulin 5 was demonstrated in patients with ARMD.³⁵

Subsequently, genome-wide linkage analysis led to the identification of several candidate genes.^{36,37} Polymorphisms on chromosomes 1, 2, 3, 10, and 16 have been identified by several genome-wide scans.³⁸

Complement factor H polymorphism variant on chromosome 1 has a significant association with various stages of ARMD.³⁹⁻⁴¹ Interestingly, this resides within a binding site for cross-reactive protein and is an important regulator of various aspects of the complement cascade. The polymorphism is significantly associated with both neovascular ARMD and geographic atrophy, as well as conferring a higher risk of bilateral disease. More recently, an additional locus on chromosome 10q LOC387715 that confers an independent risk of ARMD has been identified.⁴² The apparent importance of genes involved in the complement cascade has led to further studies and identification of several additional candidate genes, including complement component 2.⁴³

Although several biologic predispositions are known to exist and continue to be uncovered, the risk and development of ARMD has a highly complex and multifactorial etiology. As we begin to further understand the pathogenesis of the disease more clearly, there appears to be a variety of genetic risk factors that are then modified by environmental risk factors to result in a final common pathway with variable ocular manifestations and phenotypic expression.

Therapy

Dry (Atrophic) Age-related Macular Degeneration

Current therapy of atrophic ARMD revolves around vitamin supplementation to reduce progression. This is compounded with the patient's overall risk assessment, patient education, avoidance of cigarette smoking, regular follow-up examination schedule, and home monitoring by the patient for new metamorphopsia or scotoma with the aid of an Amsler grid.

The Age-Related Eye Disease Study (AREDS) developed a grading scale for macular degeneration and evaluated the benefit of zinc and antioxidant therapy for preventing vision loss in various stages of AMD.^{44,45} Patients with intermediate ARMD (defined as a few intermediate or at least one large drusen, or non-central geographic atrophy) or unilateral advanced ARMD (vision loss secondary to ARMD in one eye) were found to benefit from a supplement of antioxidants (500mg vitamin C, 400IU vitamin E, 15mg beta carotene), and zinc (80mg zinc oxide and 2mg cupric oxide to prevent zinc-induced anemia). Results from AREDS showed that those with intermediate or unilateral advanced ARMD who received the above combination of supplements had a 25% risk reduction in the progression to advanced AMD as well as a 19% risk reduction in rates of moderate vision loss (loss of three or more lines of visual acuity) at five years. AREDS 2 is currently under way examining the possible added benefit of lutein, zeaxanthin and omega 3 fatty acids on ARMD progression.

Wet (Exudative) Age-related Macular Degeneration

Neovascular ARMD has been a historically challenging disease to treat. Early treatment modalities included laser photocoagulation to well-defined areas of extrafoveal or juxtafoveal choroidal neovascularization. Subfoveal lesions were poor candidates for laser photocoagulation, given

resulting central scotoma as a result of the treatment. In the Macular Photocoagulation Study (MPS), the goal of laser photocoagulation was to decrease the risk of additional visual loss. While this treatment was shown to decrease the risk of severe visual loss (defined as loss of six or more lines of vision or a quadrupling or worse of the visual angle) at five years after treatment,⁴⁶ patients develop a permanent scotoma. Therefore, except for serving as an option for extrafoveal lesions (that would not leave a central scotoma), this treatment modality has become obsolete in the era of newer therapies.

Photodynamic therapy (PDT), involving the systemic administration of a photosensitive agent (e.g. verteporfin) followed by activation via sensitizing light, was investigated in order to treat subfoveal neovascularization. The Treatment of Age-Related Macular Degeneration with Photodynamic Therapy (TAP) and Verteporfin in Photodynamic Therapy (VIP) trials provided the basis for the use of verteporfin PDT in treating ARMD, as PDT was shown to reduce the risk of severe visual loss for certain types of choroidal neovascular membrane.^{47,48} Since the advent of anti-VEGF agents, PDT has fallen out of favor as primary treatment, but is used in combination with anti-VEGF agents and/or steroids for lesions recalcitrant to anti-VEGF agents alone.

Currently, the first-line management for choroidal neovascularization in ARMD is anti-angiogenic therapy. Three anti-VEGF agents have been used in the treatment of exudative ARMD, two of which are US Food and Drug Administration (FDA) approved for use in macular degeneration (pegaptanib sodium and ranibizumab), with the third being used off-label in the treatment of ARMD (bevacizumab). The currently available mode of delivery of all these agents is repeated intra-vitreous injection.

Pegaptanib sodium (Macugen; OSI/Eyetech, Inc., Melville, NY) is an RNA aptamer that binds specifically only to VEGF isoform 165. Injection of pegaptanib every six weeks was shown to result in a significant reduction in severe visual loss for subfoveal neovascularization in the VEGF Inhibition Study In Ocular Neovascularization (VISION), with 70% of treated patients losing fewer than three lines of vision compared with 55% of those receiving sham injection.⁴⁹ Pegaptanib was approved by the FDA for ARMD treatment in 2004, but is not used with the availability of other anti-VEGF agents with a more potent effect.

Ranibizumab (Lucentis; Genentech, Inc., San Francisco, CA) is a non-selective recombinant humanized monoclonal antibody fragment that inhibits all VEGF-A isoforms, and is derived from the same parent murine antibody as bevacizumab (Avastin; Genentech, Inc.). The Minimally Classic/Occult Trial of the Anti-VEGF Antibody Ranibizumab in the Treatment of Neovascular AMD (MARINA) and Anti-VEGF Antibody for the Treatment of Predominantly Classic CNV in AMD (ANCHOR) trials provided data for FDA approval of ranibizumab in the treatment of all

subtypes of exudative ARMD.^{50,51} Most importantly, these trials were the first to show an improvement in vision in patients treated for ARMD.

In the MARINA trial, 95% of subjects at 12 months and 90% at 24 months receiving monthly ranibizumab injections lost fewer than three lines of vision compared with 62 and 53%, respectively, receiving sham injections. Furthermore, 34% at 12 months and 33% at 24 months gained three or more lines of vision compared with 4 and 5% receiving sham injections.⁵⁰ In the ANCHOR trial, 96% of subjects at 12 months and 90% at 24 months receiving monthly ranibizumab injections lost fewer than three lines of vision compared with 64 and 66%, respectively, receiving PDT. Furthermore, 40% at 12 months and 41% at 24 months gained three or more lines of vision compared with 6% at both 12 and 24 months receiving PDT.^{51,52}

Bevacizumab is FDA-approved for use in metastatic colorectal, lung, and breast cancer, and is being used off-label for the treatment of ARMD. Since the first report of its use in the treatment of ARMD, numerous retrospective and prospective studies have shown its effectiveness in treating exudative ARMD.^{53–55} The agent appears to be safe and effective for intra-vitreous use^{56,57} and has gained popularity given its significantly lower cost compared with ranibizumab.

A variety of dosing intervals for bevacizumab and ranibizumab have been studied, but there remains no consensus as to the most desirable treatment strategy for the use of anti-VEGF agents in the treatment of exudative ARMD, although treatment based on OCT imaging seems beneficial.^{55,58,59} Combination therapies involving intra-vitreous corticosteroids,^{60,61} PDT and anti-VEGF agents are being increasingly researched for potential synergistic effects or for use in recalcitrant disease.

Future therapies being investigated include blocking the effects of VEGF by different mechanisms, such as a decoy receptor with VEGF trap (Regeneron Pharmaceuticals, Tarrytown, NJ); small interfering RNA (siRNA) agents that downregulate the VEGF or VEGF receptor genes (e.g. bevasiranib (OPKO Health, Inc./Acuity Pharmaceuticals, Miami, FL) and AGN211745 (Allergan, Inc., Irvine, CA)); and focal strontium-90 beta radiation delivered via the Epi-Rad 90 Ophthalmic System (NeoVista, Fremont, CA).

In summary, ARMD remains a significant public health concern and important cause of blindness in the elderly. Recent research has focused on the genetic factors responsible for the pathogenesis of ARMD. ARMD presents in either the atrophic form, which is mainly managed with close monitoring and antioxidant and zinc therapy, or the exudative form, for which there is currently effective treatment with anti-VEGF agents. Future therapies are being researched to target both the atrophic and exudative forms of ARMD. ■

- Friedman DS, O'Colmain BJ, Munoz B, et al., Prevalence of age-related macular degeneration in the United States Eye Diseases Prevalence Research Group, *Arch Ophthalmol*, 2004;122:564–72.
- Klein R, Klein BE, Jensen SC, et al., The five-year incidence and progression of age-related maculopathy: the Beaver Dam Eye Study, *Ophthalmology*, 1997;104:7–21.
- Klein R, Klein BE, Linton KL, Prevalence of age-related maculopathy: the Beaver Dam Eye Study, *Ophthalmology*, 1992;99:933–43.
- Age-Related Eye Disease Study Research Group, Potential public health impact of Age-Related Eye Disease Study results: AREDS report no. 11, *Arch Ophthalmol*, 2003;121:1621–4.
- Eye Diseases Prevalence Research Group, Prevalence of age-related macular degeneration in the United States, *Arch Ophthalmol*, 2004;122:564–72.
- Rein DB, Wittenborn JS, Zhang X, et al., Vision Health Cost-Effectiveness Study Group, Forecasting age related macular degeneration through the year 2050: the potential impact of new treatments, *Arch Ophthalmol*, 2009;127:533–40.
- Slakter JS, Stur M, Quality of life in patients with age-related macular degeneration: impact of the condition and benefits of treatment, *Surv Ophthalmol*, 2005;50:263–73.
- Augustin A, Sahel JA, Bandello F, et al., Anxiety and depression prevalence rates in age-related macular degeneration, *Invest Ophthalmol Vis Sci*, 2007;48:1498–503.
- Brody BL, Gamst AC, Williams RA, et al., Depression, visual acuity, comorbidity, and disability associated with age-related

- macular degeneration, *Ophthalmology*, 2001;108:1893–900.
40. Knudtson MD, Klein BE, Klein R, et al., Age-related eye disease, quality of life, and functional activity, *Arch Ophthalmol*, 2005;123:807–14.
 41. La Cour, M, Kiilgaard JF, et al., Age Related Macular Degeneration: epidemiology and optimal treatment, *Drugs Aging*, 2002;19:101–33.
 42. Cong R, Zhou B, Sun Q, et al., Smoking and the risk of age-related macular degeneration: a meta-analysis, *Ann Epidemiol*, 2008;18:647–56.
 43. Age-Related Eye Disease Study Research Group, Risk factors associated with age-related macular degeneration. A case-control study in the age-related eye disease study: Age-Related Eye Disease Study Report Number 3, *Ophthalmology*, 2000;107:2224–32.
 44. Ikram MK, van Leeuwen R, Vingerling JR, et al. Relationship between refraction and prevalent as well as incident age-related maculopathy: the Rotterdam Study, *Invest Ophthalmol Vis Sci*, 2003;44:3778–82.
 45. Hogg RE, Woodside JV, Gilchrist SE, et al., Cardiovascular disease and hypertension are strong risk factors for choroidal neovascularization, *Ophthalmology*, 2008;115:1046–52.e2.
 46. Vingerling JR, Hofman A, Grobbee DE, et al., Age-related macular degeneration and smoking: the Rotterdam Study, *Arch Ophthalmol*, 1996;114:1193–6.
 47. Clemons TE, Milton RC, Klein R, et al., Age-Related Eye Disease Study Research Group. Risk factors for the incidence of Advanced Age-Related Macular Degeneration in the Age-Related Eye Disease Study (AREDS) AREDS report number 19, *Ophthalmology*, 2005;112(4):533–9.
 48. Klein R, Klein BE, Tomany SC, et al., The association of cardiovascular disease with the long-term incidence of age-related maculopathy: the Beaver Dam Eye Study, *Ophthalmology*, 2003;110:1273–80.
 49. van Leeuwen R, Ikram MK, Vingerling JR, et al., Blood pressure, atherosclerosis, and the incidence of age-related maculopathy: the Rotterdam Study, *Invest Ophthalmol Vis Sci*, 2003;44:3771–7.
 50. Ambati J, Ambati BK, Yoo SH, et al., Age-related macular degeneration: etiology, pathogenesis, and therapeutic strategies, *Survof Ophthalmol*, 2003;48:257–93.
 51. Holz FG, Pauleikhoff D, Klein R, et al., Pathogenesis of lesions in late age-related macular disease, *Amer J Ophthalmol*, 2004;137:504–10.
 52. Zarbin MA, Current concepts in the pathogenesis of age-related macular degeneration, *Arch Ophthalmol*, 2004;122:598–614.
 53. Gass JD, Drusen and disciform macular detachment and degeneration, *Arch Ophthalmol*, 1973;90:206–17.
 54. Bird AC, Bressler NM, Bressler SB, et al., An international classification and grading system for age-related maculopathy and age-related macular degeneration. The International ARM Epidemiological Study Group, *Surv Ophthalmol*, 1995;39:367–74.
 55. Green WR, Enger C, Age-related macular degeneration histopathologic studies. The 1992 Lorenz E. Zimmerman Lecture, *Ophthalmology*, 1993;100:1519–35.
 56. Bressler NM, Silva JC, Bressler SB, et al., Clinicopathologic correlation of drusen and retinal pigment epithelial abnormalities in age-related macular degeneration, *Retina*, 1994;14:130–42.
 57. Shelley EJ, Madigan MC, Natoli R, et al., Cone degeneration in aging and age-related macular degeneration, *Arch Ophthalmol*, 2009;127:483–92.
 58. Green WR, Key SN, Senile macular degeneration: a histopathologic study, *Trans Am Ophthalmol Soc*, 1977;75:180–254.
 59. Maguire MG, Bressler SB, Bressler NM, et al., Macular Photocoagulation Study Group: relationship of drusen and abnormalities of the retinal pigment epithelium to the prognosis of neovascular macular degeneration, *Arch Ophthalmol*, 1990;108:1442–7.
 60. Zhang SX, Ma JX, Ocular neovascularization: implication of endogenous angiogenic inhibitors and potential therapy, *Prog Retin Eye Res*, 2007;26:1–37.
 61. Dorrell M, Uusitalo-Jarvinen H, Aguilar E, et al., Ocular neovascularization: basic mechanisms and therapeutic advances, *Surv Ophthalmol*, 2007;52(Suppl. 1):S3–19.
 62. Campochiaro PA, Ocular neovascularization and excessive vascular permeability, *Expert Opin Biol Ther*, 2004;4:1395–402.
 63. Connolly DT, Heuvelman DM, Nelson R, et al., Tumor vascular permeability factor stimulates endothelial cell growth and angiogenesis, *J Clin Invest*, 1989;84:1470–8.
 64. Iriyama A, Inoue Y, Takahashi H, et al., A2E, a component of lipofuscin, is pro-angiogenic *in vivo*, *J Cellular Phys*, 2009;220:469–75.
 65. Stone EM, Braun TA, Russell SR, et al., Missense variations in the fibulin 5 gene and age-related macular degeneration, *N Eng J Med*, 2004;351:346–53.
 66. Fisher SA, Abecasis GR, Yashar BM, et al., Meta-analysis of genome scans of age-related macular degeneration, *Hum Mol Genet*, 2005;14:2257–64.
 67. Abecasis GR, Yashar BM, Zhao Y, et al., Age-related macular degeneration: a high-resolution genome scan for susceptibility loci in a population enriched for late-stage disease, *Amer J Hum Genet*, 2004;74:482–94.
 68. Haddad S, Chen CA, Santangelo SL, et al., The genetics of age-related macular degeneration: a review of progress to date, *Surv Ophthalmol*, 2006;51:316–63.
 69. Klein RJ, Zeiss C, Chew EJ, et al., Complement factor H polymorphism in Age-related Macular Degeneration, *Science*, 2005;308:385–9.
 70. Zarepari S, Branham KE, Li M, et al., Strong association of the Y402H variant in complement factor H at 1q32 with susceptibility to age-related macular degeneration, *Am J Hum Genet*, 2005;77:149–53.
 71. Despriet DD, Klaver CC, Wittemans JC, et al., Complement factor H polymorphism, complement activators, and risk of age-related macular degeneration, *JAMA*, 2006;296:301–9.
 72. Rivera A, Fisher SA, Fritsche LG, et al., Hypothetical LOC387715 is a second major susceptibility gene for age-related macular degeneration, contributing independently of complement factor H to disease risk, *Hum Molec Genet*, 2005;14:3227–36.
 73. Gold B, Merriam JE, Zernant J, et al., Variation in factor B (BF) and complement component 2 (C2) genes is associated with age-related macular degeneration, *Nat Genet*, 2006;38:458–62.
 74. Age related Eye Disease study Group, A randomized, placebo controlled, clinical trial of high dose supplementation with vitamins C and E, beta carotene, and zinc for age related macular degeneration and vision loss. AREDS report 8, *Arch Ophthalmol*, 2001;119:1417–36.
 75. Ferris FL, Davis MD, Clemons TE, et al., Age Related Eye Disease Study Research Group, A simplified severity scale for age related macular degeneration: AREDS report 18, *Arch Ophthalmol*, 2005;123:1570–4.
 76. Macular Photocoagulation Study Group. Argon Laser Photocoagulation for neovascular maculopathy: five year results form randomized clinical trials, *Arch Ophthalmol*, 1991;109:1109–14.
 77. Treatment of Age Related Macular Degeneration with Photodynamic therapy (TAP) Study Group, Photodynamic therapy of sub-foveal choroidal neovascularization Age Related Macular Degeneration with Verteporfin: two year results of 2 randomized clinical trials. TAP report 2, *Arch Ophthalmol*, 2001;119:198–207.
 78. Verteporfin Photodynamic Therapy (VIP) Study Group, Verteporfin therapy of subfoveal choroidal neovascularization in age-related macular degeneration: two-year results of a randomized clinical trial including lesions with occult with no classic choroidal neovascularization—Verteporfin in Photodynamic Therapy Report 2, *Am J Ophthalmol*, 2001;131:541–60.
 79. Gragoudas ES, Adamis AP, Cunningham ET, et al., VEGF Inhibition Study in Ocular Neovascularization Clinical Trial Group. Pegaptanib for Neovascular age related macular Degeneration, *N Engl J Med*, 2004;351:2805–16.
 80. Rosenfeld PJ, Brown DM, Heier JS, et al., Ranibizumab for neovascular age related macular degeneration (2 year results from the MARINA study), *N Engl J Med*, 2006;355:1419–31.
 81. Brown DM, Kaiser PK, Michels M, et al., ANCHOR Study Group. Ranibizumab vs. Verteporfin for neovascular age related macular degeneration. (1 year results of the ANCHOR study), *N Engl J Med*, 2006;355:1432–44.
 82. Brown DM, Michels M, Kaiser PK, et al., Ranibizumab versus verteporfin photodynamic therapy for neovascular age-related macular degeneration: two-year results of the ANCHOR study, *Ophthalmology*, 2009;116:57–65.
 83. Rosenfeld PJ, Moshfeghi AA, Puliafito CA, Optical coherence tomography findings after an intravitreal injection of bevacizumab (Avastin) for neovascular age-related macular degeneration, *Ophthalmic Surg Lasers Imaging*, 2005;36:331–5.
 84. Schouten JS, La Heij EC, Webers CA, et al., A systematic review on the effect of bevacizumab in exudative age-related macular degeneration, *Graefes Arch Clin Exp Ophthalmol*, 2009;247:1–11.
 85. Ciulla TA, Rosenfeld PJ, Antivascular endothelial growth factor therapy for neovascular age-related macular degeneration, *Curr Opin Ophthalmol*, 2009;20:158–65.
 86. Wu L, Martinez-Castellanos MA, Quiroz-Mercado H, et al., Twelve-month safety of intravitreal injections of bevacizumab (Avastin): results of the Pan-American Collaborative Retina Study Group (PACORES), *Graefes Arch Clin Exp Ophthalmol*, 2008;246:81–7.
 87. Fung AE, Rosenfeld PJ, Reichel E, The international intravitreal bevacizumab safety survey: using the Internet to assess drug safety worldwide, *Br J Ophthalmol*, 2007;90:1344–9.
 88. Fung AE, Lalwani GA, Rosenfeld PJ, et al., An optical coherence tomography guided, variable dosing regimen with intravitreal ranibizumab (Lucentis) for neovascular age-related macular degeneration, *Am J Ophthalmol*, 2007;143:566–83.
 89. Regillo CD, Brown DM, Abraham P, et al., Randomized, double-masked, sham controlled trial of ranibizumab for neovascular age-related macular degeneration: PIER Study year 1, *Am J Ophthalmol*, 2008;145:239–48.
 90. Ruiz-Moreno JM, Montero JA, Barile S, Zarbin MA, Photodynamic therapy and high-dose intravitreal triamcinolone to treat exudative age-related macular degeneration: 1-year outcome, *Retina*, 2006;26:602–12.
 91. Ergun E, Maar N, Ansari-Shahrezaei S, et al., Photodynamic therapy with verteporfin and intravitreal triamcinolone acetonide in the treatment of neovascular age-related macular degeneration, *Am J Ophthalmol*, 2006;142:10–6.