

## Macular Pigment Density Measurement in Patients with Age-related Macular Degeneration

Jens Dawczynski,<sup>1</sup> Susanne Jentsch,<sup>2</sup> Dietrich Schweitzer,<sup>2</sup> Martin Hammer<sup>2</sup> and Jürgen Strobel<sup>3</sup>

1. Professor and Associate Director, Department of Ophthalmology, University Hospital Leipzig;

2. Research Fellow; 3. Professor and Head, Department of Ophthalmology, University Hospital Jena

### Abstract

Macular pigment is key to the healthy eye. Direct determination of macular pigment optical density using single-wavelength reflectometry with a fundus camera has allowed to identify changes in macular pigmentation in patients with dry or exudative macular degeneration. This approach could be useful for individualised patient follow-up, particularly in those with age-related macular degeneration.

### Keywords

Macular pigment, age-related macular degeneration, macular pigment optical density, long-term follow-up, individual patient monitoring

**Disclosure:** The authors have no conflicts of interest to declare.

**Received:** 20 September, 2011 **Accepted:** 4 October, 2011 **Citation:** *European Ophthalmic Review*, 2011; December: [ePub Ahead of Print]

**Correspondence:** Jens Dawczynski, Associate Director, Department of Ophthalmology, University Hospital Leipzig, Liebigstr. 10-14, 04103 Leipzig, Germany.  
E: jens.dawczynski@medizin.uni-leipzig.de

**Support:** The publication of this article was funded by Carl Zeiss Meditec AG.

Macular pigment, which consists of lutein and zeaxanthin, is a key component of the protective system of the retina.<sup>1</sup> In addition to its significance within the antioxidant protective system, macular pigment also has a direct influence on contrast sensitivity.<sup>2</sup> It is therefore reasonable to conduct routine and objective clinical follow-up of ophthalmology patients, especially those with degenerative macular diseases.<sup>3</sup>

The components of macular pigment can have a possible positive influence on the course of age-related macular degeneration (AMD).<sup>4,5</sup> There are distinct individual differences in macular pigment optical density (MPOD) between patients: those with a lower intake of lutein and zeaxanthin tend to exhibit lower MPOD values than those with a higher intake of lutein and zeaxanthin.<sup>6</sup> However, clearly defined standard MPOD values do not yet exist and, therefore, long-term individual follow-up is of great importance. Furthermore, direct determination of the macular pigment is necessary. Indirect determination – for example via changes in fundus autofluorescence alone – does not appear promising as a prognostic tool.<sup>7</sup>

### Procedures for Determining Macular Pigment Optical Density

Both objective and subjective procedures for determining MPOD are currently available.<sup>3,8</sup> With respect to their practical applicability, these procedures feature substantial differences in the duration of examination, glare for patients and demands on eye fixation behaviour. For broad-scale use, there is a particular need for a simple and accurate method that can also be performed on less co-operative patients.

A procedure developed by Schweitzer and colleagues, the single-wavelength reflectometry method, is now commercially available in a fundus camera (VISUCAM 200® and VISUCAM 500®, Carl Zeiss Meditec AG). It represents a particularly simple, objective and reproducible way of determining MPOD.<sup>9</sup> The results are comparable to those obtained by the two-wavelength autofluorescence method.<sup>9</sup>

### Investigations in Three Patients Using a VISUCAM 500 Fundus Camera

*Figures 1A–F* show fundus images and MPOD analyses of three patients; *Figures 1A* and *B* show the fundus image and MPOD analysis of a healthy patient with relatively high values; by contrast, *Figures 1C* and *D* show the fundus image and MPOD analysis of a patient with dry AMD, and *Figures 1E* and *F* show the fundus image and MPOD analysis of a patient with exudative AMD. The results of the investigations are displayed graphically as spatial distribution profiles, and also as measured values (mean optical density, maximum optical density, volume and area) in *Table 1*. The images were captured and analysed using a VISUCAM 500.

MPOD variations are evident in the patients with macular changes. Generally diminished MPOD values can be observed in the patient with dry AMD and the patient with exudative AMD.

Significant variations within an individual eye are obvious, as revealed by distinct areas of high and low MPOD. These observations are supported by a recent study that determined significant

**Table 1: Macular Pigment Optical Density Values for Patients from Figure 1**

Figure	Mean OD (du)	Max OD (du)	Volume (du x pixel)	Area (pixel)
1B (healthy patient)	0.245	0.689	15.611	63.643
1D (patient with dry AMD)	0.173	0.430	7.506	43.463
1F (patient with exudative AMD)	0.123	0.349	3.001	24.440

AMD = age-related macular degeneration; du = density units; OD = optical density.

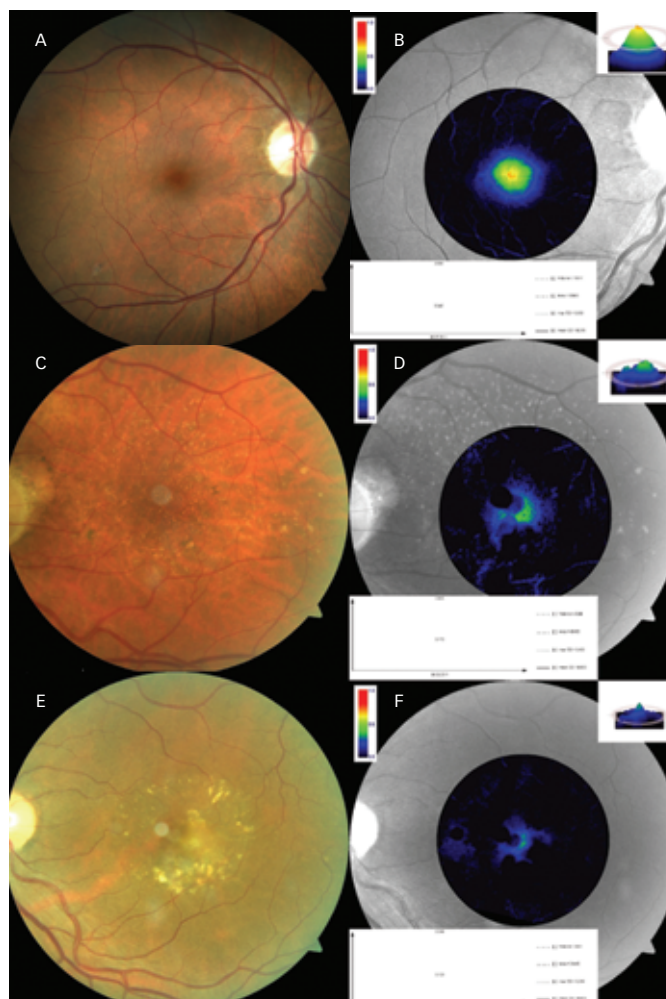
individual differences in patients with exudative or dry AMD, with no uniform pattern.<sup>10</sup>

### Long-term Monitoring of Patient with Age-related Macular Degeneration

From these observations, it follows that an MPOD measurement should be performed as soon as possible in patients with macular degeneration. It might then be possible to use the measured changes over time as progression parameters to forecast the future course of the disease.

MPOD measurement could thus become a form of examination for AMD comparable to visual field tests or measurement of nerve fibre layer thickness for glaucoma. In particular, MPOD measurement could enable long-term monitoring and risk assessment of the progression of macular changes in a practical way.

Overall, the determination of MPOD is an interesting additional procedure for individual monitoring of ophthalmology patients, particularly those with macular degeneration. Additional examinations of larger patient groups over a longer period of time would be needed to derive more precise conclusions concerning standard values and progression behaviour. ■

**Figure 1: Fundus Images and MPOD Analyses of a Healthy Patient (A + B), a Patient with Dry AMD (C + D) and a Patient with Exudative AMD (E + F)**


AMD = age-related macular degeneration; MPOD = macular pigment optical density.

1. Beatty S, Kohl H, Phil M, et al., The role of oxidative stress in the pathogenesis of age-related macular degeneration, *Surv Ophthalmol*, 2000;45(2):115–34.
2. Renzi LM, Hammond BR, The effect of macular pigment on heterochromatic luminance contrast, *Exp Eye Res*, 2010; 91: 896–900.
3. Dawczynski J, Schweitzer D, Lang GE, Möglichkeiten der objektiven Messung der optischen Dichte der Makula, *Klin Monatsbl Augenheilkd*, 2011;228(1):57–61.
4. Schweigert FJ, Reimann J, Mikronährstoffe und ihre Relevanz für das Auge – Wirkungsweise von Lutein, Zeaxanthin und Omega-3-Fettsäuren, *Klin Monatsbl Augenheilkd*, 2011; 228(6):537–43.
5. Trieschmann M, Beatty S, Nolan JM, et al., Changes in macular pigment optical density and serum concentrations of its constituent carotenoids following supplemental lutein and zeaxanthin: the LUNA study, *Exp. Eye Res*, 2007;84(4):718–28.
6. Dietzel M, Zeimer M, Heimes B, et al., Determinants of macular pigment optical density and its relation to age-related maculopathy: results from the Muenster ageing and retina study (MARS), *Invest Ophthalmol Vis Sci*, 2011; 52(6):3452–7.
7. Rothenbuehler SP, Wolf-Schnurrbusch UEK, Wolf S, Macular pigment density at the site of altered fundus autofluorescence, *Graefes Arch Clin Exp Ophthalmol*, 2011;249(4):499–504.
8. Bartlett H, Howells O, Eperjesi F, The role of macular pigment assessment in clinical practice: a review, *Clin Exp Optom*, 2010;93(5):300–8.
9. Schweitzer D, Jentsch S, Dawczynski J, et al., Simple and objective method for routine detection of the macular pigment xanthophyll, *J Biomed Opt*, 2010;15(6):061714.
10. Tsika C, Tsilimbaris MK, Makridaki M, et al., Assessment of macular pigment optical density (MPOD) in patients with unilateral wet age-related macular degeneration (AMD), *Acta Ophthalmol*, 2011;89(7):e573–e8.